

METASTASIS OF DUCTAL BREAST CARCINOMA TO THE VAGINA: A CASE REPORT

Leila Cristina Soares, Anna Candida Andrade de Camaret

Rio de Janeiro State University, Rio de Janeiro, Brazil

Disclosure: No potential conflict of interest.

Received: 01.04.13 **Accepted:** 13.09.13

Citation: EMJ Oncol. 2013;1:76-79.

ABSTRACT

Primary cancers of the vagina are rare, and so vaginal tumours are likely to represent metastasis from another site. Although breast cancer is a common malignancy, it rarely gives rise to vaginal metastases. In this study, we report a case of vaginal cancer diagnosed in a 65-year-old woman. Clinical examination showed the presence of a breast tumour, and ductal breast carcinoma was diagnosed by biopsy. Analysis of the vaginal tumour suggested that it was a metastasis. It was through the detection of the secondary tumour, complete gynaecologic examination, and complementary examinations that the primary site was correctly identified.

Keywords: Vaginal cancer, breast cancer, vaginal metastasis.

INTRODUCTION

Breast cancer is the most common neoplasm in women and a significant cause of death.¹ Approximately 3.5-10% of patients with newly diagnosed breast cancer present with concurrent metastatic disease.² This cancer often progresses because of distant metastases such as those in the bone, lung, pleura, brain, and liver. However, breast cancer metastasis to the vagina is rare.¹

Secondary tumours of the vagina are more common than primary ones. The most common cause of metastatic disease is direct local invasion from the female urogenital tract.³ A search of MEDLINE using search terms 'vaginal metastasis* AND breast cancer' yielded three cases reported in the literature. In two of these cases, lobular breast carcinoma was the primary disease, and in one case, ductal carcinoma was the primary disease. We report a case of vaginal metastasis from an invasive ductal breast carcinoma. At the time of diagnosis, bone involvement was also noted.

CASE

A 65-year-old African-American woman was admitted to our hospital because of pelvic and

lower back pain and vaginal bleeding. Gynaecological examination revealed a 3 cm ulcerated tumour in the lower third of the anterior vaginal wall with a vesicovaginal fistula and a 2 cm painful, palpable inguinal lymph node. The uterine cervix and vulva were normal. On examination of the right breast, a hard 8 cm tumour was detected but axillary lymph nodes were not palpable.

The vaginal tumour was completely removed revealing a poorly differentiated ulcerated vaginal carcinoma (Figure 1). Immunohistochemical study showed that the tumour cells stained positive for cytokeratin (CK7), vimentin, and pan-cytokeratin (AE1/AE3), and negative for cytokeratin 20 (CK20), CEA, p63, CK5/6, and S100. However, the primary origin of the tumour could not be determined immunohistochemically.

Mammography showed the presence of a mass, 8 cm in maximum diameter, at the upper quadrant junction of the right breast (Figure 2). Biopsy indicated the presence of invasive ductal carcinoma (Figure 3). Immunohistochemical studies showed negative staining for the oestrogen receptor and positive staining for both the progesterone receptor (weak) and c-erbB2. Bone metastases

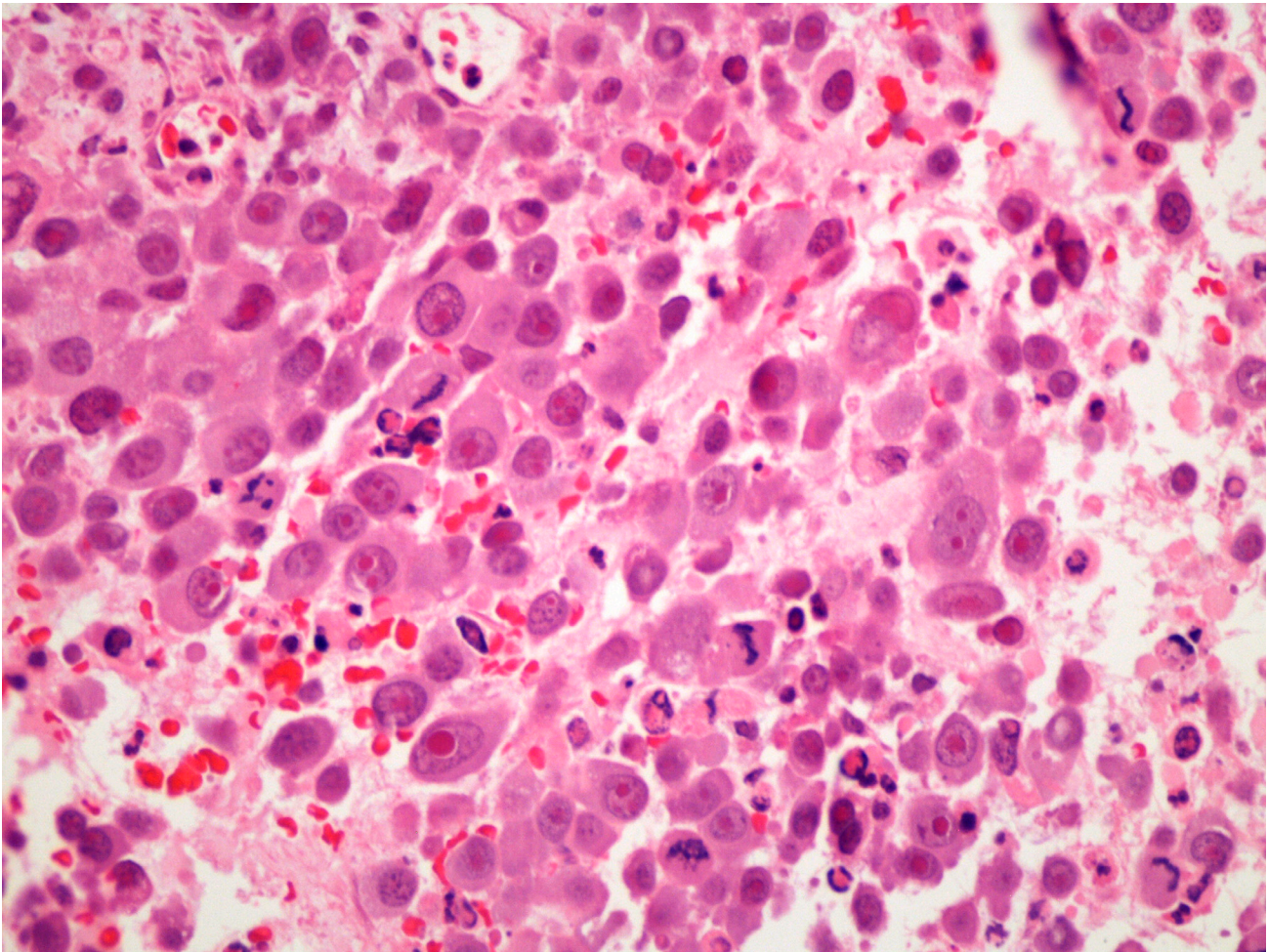


Figure 1. Histological examination of the vagina revealing poorly differentiated ulcerated carcinoma (staining haematoxylin and eosin; magnification 40×).

were detected on the right side of the frontal bone, shoulder joint, right scapula, third and fourth rib bones, ischium, hip joint, ankle joint, and transtrochanteric junction on bone scintigraphy. Abdominal ultrasonography did not indicate visceral metastases.

In this patient, breast cancer was classified as stage IV. The vaginal tumour was considered to be a metastasis from breast cancer, and it was suggested as the treatment with radiotherapy for vaginal and bone metastasis. As the vaginal tumour was completely removed and the patient achieved pain relief with medication (morphine), radiotherapy was not performed.

DISCUSSION

Primary cancers of the vagina are rare, predominantly affecting postmenopausal women and representing approximately 1-2% of all gynaecological cancers.⁴

Histologically, two main types are defined: squamous cell carcinoma and adenocarcinoma. In most cases, squamous cell carcinoma is the histological type, and in these cases, vaginal intraepithelial neoplasia often precedes vaginal cancer.^{4,5} Because of its rarity, the aetiological factors and prognosis of vaginal squamous cell carcinoma are not well known.⁴ More than 80% of vaginal malignancies are metastatic cancers, and their detection may precede the diagnosis of the primary cancer.³

Our patient had a vaginal lesion in the lower anterior wall, with a vesicovaginal fistula and a painful palpable right inguinal lymph node. The location of the tumour determines the areas of lymphatic spread. The upper two-thirds of the vagina drain into the pelvic nodes of the obturator and internal and external iliac chains, and the lower third drains into the inguinal and femoral nodes.⁶

Although the diagnosis of this breast tumour was ductal carcinoma, lobular carcinoma seems to metastasise to the genital tract more frequently, probably due to haematogenous spread.¹

Sometimes, discrimination between primary vaginal cancer and metastatic lesions is difficult.³ An accurate diagnosis is important for appropriate therapy, prognosis, and follow-up. These cancers often occur as a metastasis from cervical cancer.⁴ Vaginal cancer should initially be investigated as metastasis and should be considered as a primary tumour only after this investigation is complete.³ In this case, diagnosis was based only on the absence of inferior vulvar abnormalities and superior cervical involvement and preceded the diagnosis of breast cancer.

Remote vaginal metastases may occur via lymphatic or haematogenous spread. There are isolated reports of metastases from extra-genital cancers, from colon, breast, pancreas, and small bowel cancers.³

Patients with advanced vaginal carcinoma should be treated with irradiation and concurrent cisplatin-based chemotherapy. This treatment option is chosen to avoid exenterative surgery, to preserve anatomy, and to treat lymph node metastasis.⁷

According to the existing treatment guidelines for metastatic breast cancer, removal of the primary tumour may be a therapeutic strategy in a distinctive subset of patients. These are represented by oligometastatic disease, characterised by solitary or few metastatic lesions, and usually in a single organ.⁸

Although many patients survive for several years after the diagnosis of distant metastases, curative treatment was not possible in this case; hence, the intent of the treatment was palliative. The optimal management of stage IV breast cancer is unclear. Although there is some evidence that surgery may be associated with improved overall survival, some authors believe that removal of the primary tumour could promote cell proliferation via suppression of cell-mediated immunity. Thus, there is no consensus about the value of surgery.²

Data on the treatment of vaginal metastases are limited, but most cases are treated with radiotherapy.¹ In this case, vaginal metastasectomy had limited prognostic relevance but helped to reduce bleeding. Metastasectomy in breast cancer

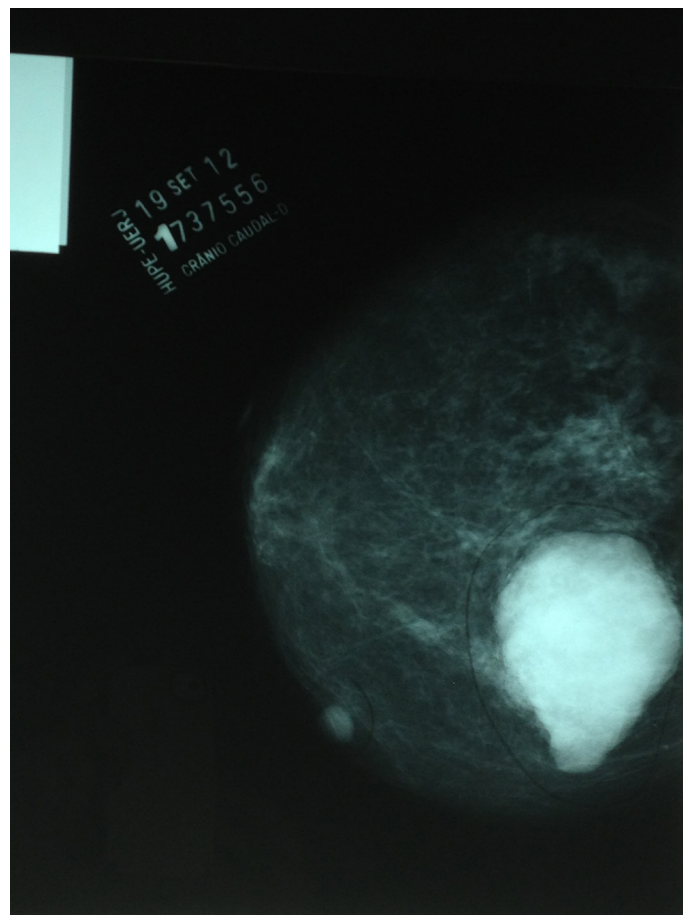


Figure 2. Mammography of right breast revealing an 8 cm mass.

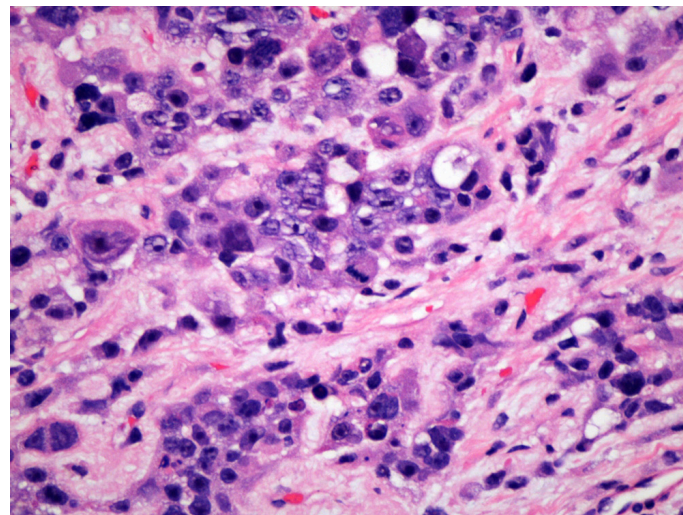


Figure 3. Histological examination of the breast revealing invasive ductal carcinoma (staining haematoxylin and eosin; magnification 40×).

is appropriate for patients in whom metastatic disease is limited to a solitary lesion or to multiple lesions at a single organ site.⁹

CONCLUSION

Involvement of the bone generally suggests a better prognosis than involvement of visceral sites and does not affect the survival of patients. Good local control can be achieved with radiotherapy.¹⁰

Vaginal cancer should initially be considered as a secondary tumour until a complete investigation has been carried out, especially in cases, such as the one reported here, with an unusual histological type.

Breast cancer is very common, but association with vaginal metastases is rare. Although vaginal cancer is associated with lobular carcinoma more often, it must be considered as a possibility even when ductal carcinoma is present. This case study emphasises the importance of a complete examination in order to avoid the misdiagnosis of vaginal cancer, and to aid follow-up of patients with breast cancer.

REFERENCES

1. Bellati F et al. First case of isolated vaginal metastasis from breast cancer treated by surgery. *BMC Cancer*. 2012;12:479.
2. Samiee S et al. Excision of the primary tumour in patients with metastatic breast cancer: a clinical dilemma. *Curr Oncol*. 2012;19(4):e270-9.
3. Parikh JH et al. MR imaging features of vaginal malignancies. *Radiographics* 2008;28(1):49-63.
4. Hellman K et al. Protein expression patterns in primary carcinoma of the vagina. *Br J Cancer*. 2004;91(2):319-26.
5. Weiderpass E, Labreche F. Malignant tumors of the female reproductive system. *Saf Health Work*. 2012;3(3):166-80.
6. McMahon CJ et al. Lymphatic metastases from pelvic tumors: anatomic classification, characterization, and staging. *Radiology*. 2010;254(1):31-46.
7. Grigsby PW. Vaginal cancer. *Curr Treat Options Oncol*. 2002;3(2):125-30.
8. Pagani O et al. International guidelines for management of metastatic breast cancer: can metastatic breast cancer be cured? *J Natl Cancer Inst*. 2010;102(7):456-63.
9. Singletary SE et al. A role for curative surgery in the treatment of selected patients with metastatic breast cancer. *Oncologist*. 2003;8(3):241-51.
10. Coleman RE. Clinical features of metastatic bone disease and risk of skeletal morbidity. *Clin Cancer Res*. 2006;12(20 Pt 2):6243s-9s.