

# XERODERMA PIGMENTOSUM: A MULTIDISCIPLINARY APPROACH

Mieran Sethi,<sup>1</sup> Alan R. Lehmann,<sup>1,2</sup> Hiva Fassihi<sup>1</sup>

1. National Xeroderma Pigmentosum Service, Department of Photodermatology, St John's Institute of Dermatology, Guy's and St Thomas' NHS Trust, London, UK  
2. Genome Damage and Stability Centre, University of Sussex, Falmer, Brighton, UK

**Disclosure:** No potential conflict of interest.

**Received:** 01.10.2013 **Accepted:** 06.11.13

**Citation:** EMJ Dermatol. 2013;1:54-63.

---

## ABSTRACT

Xeroderma pigmentosum (XP) is a rare, autosomal recessive disorder of DNA repair. Affected individuals are unable to repair ultraviolet radiation (UVR)-induced DNA damage, leading to a variety of clinical manifestations: a dramatic increase in mucocutaneous malignancies, increased lentiginosities, extreme photosensitivity (in approximately 50% of cases), and neurodegeneration (in approximately 30% of affected individuals). Incidence in Western Europe is recorded as 2.3 per million live births. There are eight different complementation groups, XP-A to XP-G, and XP-variant (XP-V) corresponding to the eight affected genes. Classically, XP patients were identified by clinicians for their tendency to develop severe and exaggerated sunburn on minimal sun exposure, however recently it has been shown that XP-C, XP-E and XP-V patients have normal sunburn reactions for skin type compared to the other groups, who suffer not only with severe, exaggerated sunburn, but also have an increased incidence of neurodegeneration.

A diagnosis of XP should be considered in a child with either severe sunburn, increasing lentiginosities at exposed sites, or development of multiple skin cancers at an early age. Skin biopsy and subsequent testing in cell cultures for defective DNA repair, confirms or excludes the diagnosis. Mean life expectancy is reduced; the two main causes of mortality are skin cancer and neurodegeneration. These clinical features distinguish XP from other disorders of DNA repair, namely Trichothiodystrophy and Cockayne syndrome, although overlapping syndromes do occur. Instigation of meticulous photoprotection for all XP patients has been shown to reduce both the lentiginosities and number of skin cancers dramatically and would be presumed to increase life expectancy. Compliance with photoprotection is a recognised problem amongst XP patients, particularly in those without easy sunburn. This is further accentuated by lack of social acceptance for people who wear UVR-protective visors. Increased awareness of XP, both within the medical and media spheres will benefit current and future XP patients; this will aid earlier diagnosis and timely photoprotection, with better compliance, and therefore, result in an improved prognosis.

**Keywords:** Xeroderma pigmentosum, DNA repair, sunburn, skin cancer, neurodegeneration, ultraviolet radiation DNA damage.

---

## INTRODUCTION

Nearly 140 years ago, the term 'xeroderma' was first used by Moritz Kaposi<sup>1</sup> for patients with dry, wrinkled, parchment-like skin, to characterise a rare disease he had noted in two patients; one with severely pigmented skin in predominantly sun-exposed areas (face, neck, shoulders, and

arms), the other, aged 10 years, also had dry, thin skin, without the noted pigmentation, but within 1 year developed a fissured tumour on the nose. Kaposi described xeroderma pigmentosum (XP) as a condition existing from childhood that never improved either spontaneously or as a result of any treatment.

In 1883, Albert Neisser made the link between XP and neurodegeneration and in 1932, two Italian physicians, De Sanctis and Cacchione,<sup>2</sup> reported a 'xerodermic idiocracy' in which three XP patients also had neurological and other physical abnormalities: microcephaly with progressive mental deficiency, retarded growth and sexual development, hearing loss, choreoathetosis, ataxia, and eventual quadriplegia with Achilles-tendon shortening. Until recently, the term 'De Sanctis-Cacchione syndrome' was used to describe XP patients with severe neurodegeneration, but the term is no longer in use. In 1965, Reed et al.<sup>3</sup> described XP with choreoathetoid neurological complications. Cerebral and olivopontocerebellar atrophy were found at autopsy of two further XP cases.<sup>4,5</sup> A review, at National Institute of Health (NIH), described all the neurological abnormalities identified in XP patients and commented that the type of neurodegeneration detected can be found in many degenerative and hereditary disorders of the nervous system of non-XP patients, and usually correlates to distinctive pathological findings; however, postmortem cerebral examination of XP patients had failed to reveal any unique morphological or cellular abnormality, other than neuronal cell loss.<sup>5,6</sup>

Exposure of skin cells to ultraviolet radiation (UVR) causes the formation of cyclobutane pyrimidine dimers (CPDs)<sup>7</sup> and pyrimidine (6-4) pyrimidone photoproducts (6-4 PPs)<sup>8</sup> by crosslinking of adjacent pyrimidines in DNA. These photoproducts are removed by the nucleotide excision repair (NER) pathway. In 1968, Cleaver<sup>9</sup> showed that whereas fibroblasts from normal adult skin were able to repair damage induced by UVR, cultured fibroblasts from XP patients had a marked reduction in, or absence of, repair. Epstein et al.<sup>10</sup> confirmed this *in vivo* in 1970.

In 1971-2, the spectrum of clinical symptoms in XP prompted studies into the genetic heterogeneity using XP fibroblast cell fusion techniques. Each XP fibroblast was known to be deficient in repairing UVR-induced DNA damage. Fusing two XP fibroblasts from two separate donors enabled a heterokaryon to be formed (a cell containing nuclei from different donors in a common cytoplasm). This heterokaryon was found to exhibit normal DNA repair, implying that separately each cell supplied what the other lacked and therefore the defects in each cell were genetically different. This ultimately

led to identification of seven separate XP 'complementation groups' deficient in NER, designated XP-A to XP-G.<sup>11-16</sup>

A separate group of XP patients with normal DNA excision repair in lymphocytes<sup>17</sup> and in fibroblasts<sup>18</sup> was reported by Burk et al. in 1971, and later these patients were designated 'XP-variant' (XP-V). Their cells showed normal levels of DNA repair after UVR exposure and it was assumed that the defect must lie elsewhere. Indeed, in 1975 Lehmann et al.<sup>19</sup> discovered that XP-V patients have a defect in the DNA post-replication repair pathway.

There have been several reviews of XP over the last 40 years,<sup>20-24</sup> but with the ever-expanding research into cellular mechanisms of DNA repair pathways, our understanding of XP as a whole continues to develop.

## EPIDEMIOLOGY

XP has been reported to occur in all ethnic groups worldwide and affects men and women in equal ratio. Amid Indian and Middle Eastern areas, incidence is quoted at 1:10,000-30,000.<sup>25-28</sup> In Japan, incidence is reported as 1:20,000-100,000,<sup>29,30</sup> and in Western Europe it has been estimated at 2.3 per million live births.<sup>31</sup> The incidence of XP in Japan appears 10-times higher than in Western countries, and approximately 60% of XP patients in Japan belong to the XP-A complementation group, twice the proportion seen in other countries.<sup>22</sup> 90% of patients are homozygous for the XP-A founder mutation, carried by 1% of the Japanese population.<sup>28</sup> In 2010, Soufir et al.<sup>32</sup> reported that 85% of XP families in the Maghreb region (Algeria, Tunisia and Morocco) carried a founder mutation in the XP-C gene. More recently, it has been reported that 1 in 5,000 individuals of the black Mahori population in the Comoro Islands have XP-C. This is linked to another founder mutation.<sup>33</sup> In the latter regions, consanguineous marriages are quite common, resulting in higher frequencies of homozygous mutations in genes corresponding to rare genetic disorders.

## AETIOLOGY AND GENETICS

XP is an autosomal recessive disorder that arises from mutations in the genes encoding for proteins that are integral to NER, a pathway that

repairs many types of DNA damage including those produced by UVR (CPDs/6-4PPs).<sup>34-37</sup> Patients have mutations in one of seven different XP genes (XP-A to XP-G) resulting in impaired NER. XP-V patients have normal NER, but mutations in DNA polymerase  $\eta$  (POLH) cause a defect in the ability to replicate DNA containing unrepaired damage.

NER consists of two sub-pathways that differ at the initial recognition step; global nucleotide excision repair (GG-NER) and transcription-coupled nucleotide excision repair (TC-NER), (Figure 1). GG-NER is a relatively slow, scanning of the entire genome; XP-E (with its partner protein DDB1) binds to the photoproduct,<sup>38</sup> and recruits XP-C, which recognises and binds to the distortion affecting the strand opposite the photoproduct.<sup>39</sup> GG-NER is responsible for

repair of both strands of actively and non-actively transcribed genes. TC-NER identifies and rapidly repairs damage, specifically on the transcribed strand of actively transcribing DNA. RNA polymerase II stalls at the site of the photoproducts; recognition of this and recruitment of subsequent NER proteins is mediated by the CSA and CSB proteins. Defects in either of these proteins result in Cockayne syndrome rather than XP.

The two NER sub-pathways then converge to form the common stem where TFIIH (a complex containing 10 polypeptides including the helicases, XP-B and XP-D) is recruited to open up DNA around the site of the photoproduct. XP-A binds to verify that all the proteins are in the correct position. The heterodimeric nucleases ERCC1/XP-F and XP-G cleave the damaged

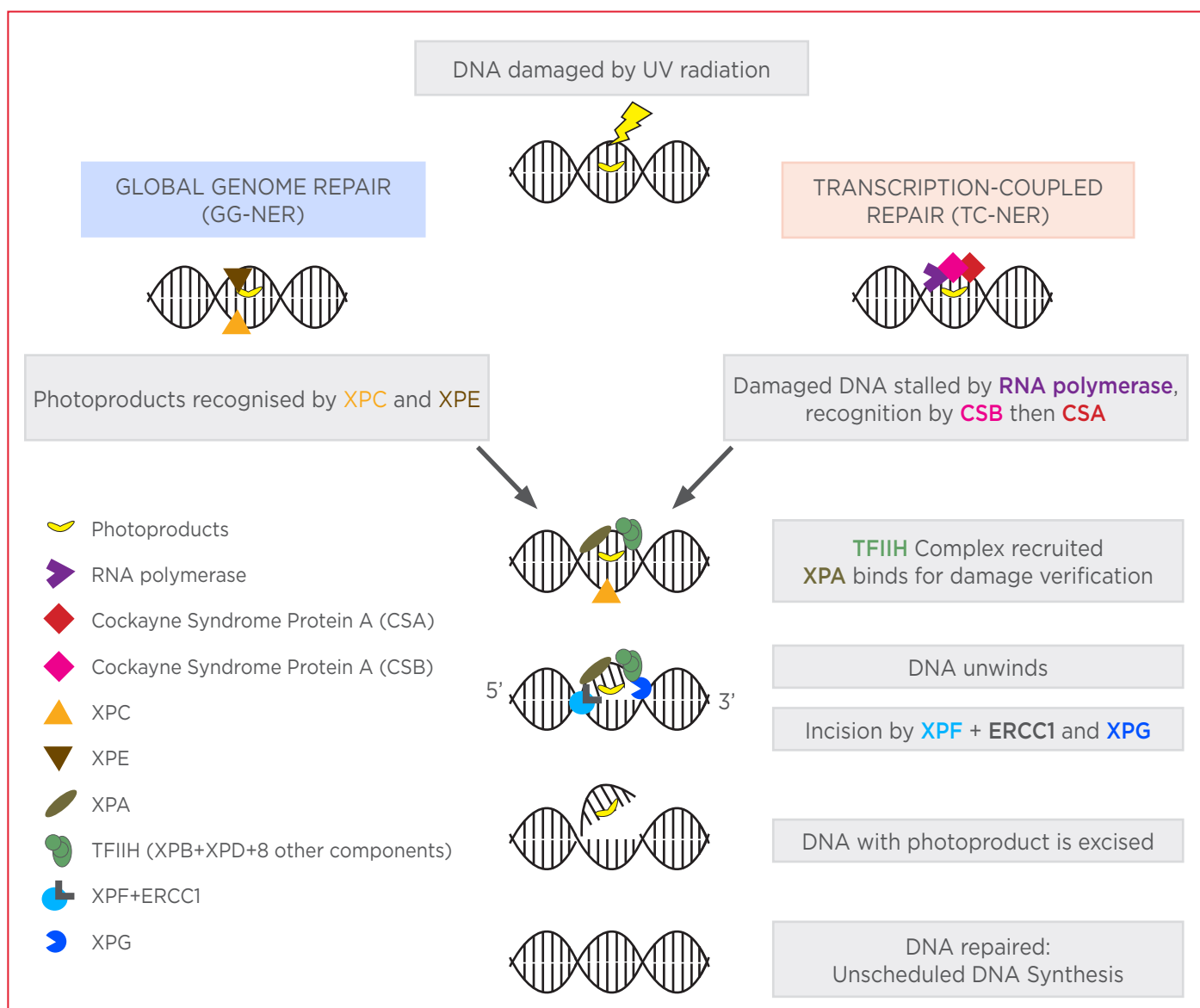


Figure 1. A model for NER of UVR-induced DNA damage.

DNA strand 5' and 3' to repair the damage respectively. An approximately 30-nucleotide fragment containing the damaged nucleotides is then excised and the resulting gap filled in using the undamaged strand as template. The DNA polymerisation that fills in the gap is known as unscheduled DNA synthesis (UDS). Mutations in XP-A, XP-B, XP-D, XP-F, and XP-G genes result in the impairment of both GG-NER and TC-NER. However, mutations in XP-C and XP-E genes affect only GG-NER, and therefore there is some preservation of NER via the TC-NER pathway.

NER is fully functional in XP-V patients. The defect is in the process of translesion synthesis, which is carried out by a specialised DNA polymerase, pol $\eta$ , that is able to replicate DNA past unrepaired photoproducts.<sup>19,40</sup>

The inability of XP patients to repair UVR-induced DNA damage explains the skin changes in these patients (lentigines and skin cancers). The neurodegeneration seen in only 30% of patients is harder to explain. It is likely to be related to the DNA repair defect and an efficient DNA repair mechanism is required to maintain the functional integrity of neuronal cells.<sup>19</sup> Brooks et al.<sup>41</sup> showed that DNA from neuronal cells that are exposed to endogenous oxygen radicals, produce oxidative DNA lesions called cyclopurines (cPu) (cyclo-2-deoxyadenosine and (5 S)-8,5'-cyclo-2'-deoxyguanosine). cPus requires removal from DNA, specifically via NER.<sup>42</sup> In XP-A cells (without functioning NER), the presence of a single cPu lesion on a transcribed DNA strand of a reporter gene strongly reduced gene expression. It was demonstrated that neuronal death resulted from accumulation of these unrepaired cPus. Later cPus were re-named as 8,5-cyclopurine-2-deoxynucleosides or 'cyPudNs'.<sup>42</sup> The biological properties of cyPudNs are very similar to other substrates of NER such as UVR-induced thymidine dimers. cyPudNs have been shown to block gene expression in XP cells, a biological effect that is compatible with causing neurodegeneration.<sup>43,44</sup>

## CLINICAL MANIFESTATIONS AND ASSOCIATIONS

Cutaneous clinical features of XP patients are largely determined by the cumulative amount of UVR exposure at sun-exposed sites (skin and

eyes) and therefore also by age of the patient at diagnosis and timing of photoprotection initiation. XP includes a clinically heterogeneous group of patients with some genotype-phenotype correlations, both between and within different complementation groups.

The main recognised clinical manifestations are: photosensitivity, leading to severe and exaggerated sunburn reactions, increased lentigines, and pigmentary change, an overwhelming increase in skin cancer frequency, ocular abnormalities, and neurodegeneration.

### Sunburn

Sunburn is a normal response to UVR exposure. The confluent and well-demarcated, erythematous, oedematous, and tender reaction is caused by vasodilation and inflammation. Apoptotic keratinocytes are present in histological analysis.<sup>45</sup> The sunburn response is probably triggered by UVR-induced DNA damage. Patients with XP suffer with severe and prolonged sunburn. Their increased susceptibility to severe sunburn may relate to the persistence of UVR photoproducts in the DNA.<sup>46</sup>

Acute severe sunburn on minimal sun exposure was once considered a cardinal presenting feature of XP. However, with increasing research and analysis of larger groups of XP patients, it has been shown that only 50% of XP patients will suffer from severe and prolonged sunburn reactions.<sup>21,47,48</sup> The remaining 50% have sunburn reactions that are normal for their skin type and present with lentigines at sun-exposed sites, (together with an early onset of skin cancer). Our recent study, within a cohort of patients in the UK National XP service, has shown that patients in complementation groups XP-A, XP-D, XP-F, and XP-G have been shown to suffer from severe sunburn reactions; whereas, those in groups XP-C, XP-E and XP-V have normal sunburn reactions, consistent with similar findings of Kraemer and colleagues at the NIH.<sup>47,48</sup> XP-A, XP-B, XP-D, XP-F, and XP-G proteins are all required for the common stem of NER whereas XP-C and XP-E proteins are only required for GG-NER. In XP-C and XP-E, TC-NER is preserved. XP-V patients with mutations affecting DNA polymerase  $\eta$ , also have normal functioning TC-NER (and GG-NER). It is therefore hypothesised that normal sunburn reactions in approximately half of the XP patients relate to preservation of TC-NER.<sup>49</sup>

## Skin Cancers

XP patients have a >10,000-fold increased risk of developing non-melanoma and a 2,000-fold increased risk of melanoma skin cancer in patients under 20 years of age. The median age at diagnosis of first non-melanoma skin cancer (NMSC) is between 8 and 9 years,<sup>21,50</sup> significantly younger than the median age at diagnosis of first melanoma, at age 22 years. This is an inverse pattern to what is observed in the general population, where younger patients are more likely to present with melanoma and older patients with non-melanoma skin cancers.<sup>51</sup> UVR exposure to the oral cavity in XP patients can result in mucocutaneous malignancy, most commonly seen as squamous cell carcinoma of the tip of the tongue.<sup>52</sup>

Studies on UVR-induced mutagenesis in cultured cells have indicated a 'UVR-signature mutation', namely C to T transitions and CC to TT tandem mutations. The latter, in particular, are rarely found after exposure to any mutagenic agent other than UVR. Analysis of the p53 gene in skin tumours from XP patients has revealed these classical UVR-induced 'signature' mutations in the DNA,<sup>53</sup> indicating that the high level of p53 mutations found in the tumours is directly caused by unrepaired UVR-induced DNA photoproducts.<sup>54</sup> There is a significantly higher level of the UVR signature mutations in XP skin tumours compared to those found in non-XP, sporadic skin cancers.<sup>55</sup>

The XP patients in complementation groups that have severe sunburn reactions (XP-A, XP-B, XP-D, XP-F, XP-G) have lower rates of skin cancer than those patients with sunburn reactions that are normal for skin type (XP-C, XP-E, XP-V). This may be due to severe sunburn reactions prompting earlier diagnosis of XP and earlier age of initiating more rigorous photoprotection.<sup>47</sup>

In addition to skin cancer, the XP-C patient group seems to be at greater risk of developing other forms of malignancy, particularly neurological cancers.<sup>56,57</sup> This patient group has also been reported to occasionally develop pyogenic granulomas and multinodular thyroid carcinomas.<sup>58</sup>

## Ocular

There are three ways in which the eyes can be affected in XP; (1) UVR exposure resulting in DNA damage of the eyelids and periocular skin; (2) UVR exposure resulting in DNA damage

of the ocular surface, and (3) the ocular manifestations of neurodegeneration. Even patients with few ophthalmic signs commonly describe photophobia, which is the earliest presenting ophthalmic symptom of XP.<sup>21</sup>

Damage to the eyelids and periocular skin can result in the development of cicatricial skin changes as well as skin cancers, which require excision.<sup>59</sup> The ocular surface (conjunctiva and cornea) can develop UVR-related damage including dry eye, conjunctival injection, and inflammation (without infection), as well as development of premature pingueculae and pterygia. Prolonged corneal exposure can result in corneal scarring and visual impairment. Ocular surface cancers, mainly squamous cell carcinomas, have also been reported in patients with significant UVR exposure and poor ocular photoprotection.<sup>60</sup>

Patients with XP-related neurodegeneration may also develop neuro-ophthalmological features, including sluggish pupils, nystagmus, and strabismus. (S. Morley, UK National XP Clinic ophthalmologist, personal communication).

## Neurodegeneration

Neurological manifestations of XP typically follow skin symptoms in the natural history of the disease and do not arise before 2 years of age.<sup>61</sup> Parents notice mild cognitive impairment first, usually when the child is starting school; EEG studies confirm a spectrum of encephalopathy from mild-to-severe. Cerebellar signs manifest usually between age 4 and 16 years, usually dysarthria and difficulties with balance. Ataxia and areflexia follow suit; EMG studies show evidence of axonal sensory and motor neuropathy although this is not usually seen before the second decade of life. Some patients will also exhibit choreoathetoid involuntary movements in the upper limbs.<sup>3</sup> Most XP patients with neurological abnormalities will develop sensorineural deafness, and the degree of hearing loss has been shown to predict future neurological involvement.<sup>48</sup> Involvement of the corticospinal tract can result in tetraplegia, becoming wheelchair-bound and eventually bed-bound, a few years before death.<sup>61</sup>

Approximately 30% of XP patients will develop neurodegeneration; patients with mutations causing lack of XP-A, XP-D, XP-F, and XP-G

proteins have an increased susceptibility.<sup>23,47,48,50</sup> This is most likely due to the requirement for these proteins to deal with oxidative damage such as cyPudNs, which accumulate in DNA in neuronal cells.<sup>44</sup>

XP-C and XP-E patients classically do not develop clinically detectable neurodegeneration; however there have been reports of late-onset asymptomatic neurological disease in XP-C patients.<sup>62</sup> In one report, post-mortem analysis of an XP-C patient provided evidence of neurodegeneration with neuronal loss in dorsal root ganglia.<sup>63</sup> A conceivable explanation for this was proposed by Nouspikel, who suggested a role for XP-C in domain-associated repair (DAR) (repair of both the transcribed and non-transcribed strand of active genes). As the non-transcribed strand of DNA serves as a template for repair, failure to repair the non-transcribed strand will eventually impact repair of the transcribed strand. XP-C is required for DAR so therefore lack of XP-C may result in lack of DAR and therefore gradual onset of neurodegeneration.<sup>44</sup>

## Psychological

Although not a presenting feature of XP, the social isolation and clothing restrictions of the disease can inevitably predispose these patients to depression. In patients with XP, adherence to a very restrictive photoprotection regime (including wearing a UVR-protective visor), which is highly visible to other people, causes poor health-related quality of life in terms of mental health (low mood, anxiety) and social isolation. There is a potential for bullying for school-age children, and concerns for job-security in adults at work should they disclose XP. A 20-year observational study of XP patients in Finland reported the symptom of increased fear and tendency to weep amongst 8/11 adults.<sup>61</sup>

Compliance is an issue; for children at school there is an impact on behaviour with tantrums and outbursts, due to the frustration of having to photoprotect, restrictions on outdoor activities, and being treated differently. This may create a barrier to successful learning at school, potentially limiting academic progress and impacting on social relationships (observations from the UK National XP clinic). In teenage years the necessity for photoprotection links more widely to patients' understanding and acceptance of XP.

Other psychological issues include potential for developing anxiety and depression from ongoing surgical procedures, many focused on the face, with potential for facial disfigurement or developing fatal skin cancers. Many patients are also anxious about the possibility of neurodegeneration, with loss of memory and early onset dementias as well as physical disabilities (J. Baulcomb, UK National XP clinic educational psychologist, personal communication).

## DIAGNOSIS

Initially the diagnosis is predominantly clinical: a young child may be brought to the paediatric department with bright, confluent erythema over all sun-exposed sites, or with lentigines at an unusually early age in sun-exposed areas. In the former case, the clinician assessing the child may suspect a skin allergy, drug reaction or even in some cases sunburn caused by parental neglect. After all differentials are excluded, the clinician would then request cellular tests to assess for defective DNA repair. This requires a 4 mm punch biopsy of the skin taken from an unexposed site (e.g. buttock area). This specimen is used to culture fibroblasts followed by UVR exposure and subsequent measurement of unscheduled DNA synthesis (UDS), (Figure 1). UDS refers to the newly synthesised DNA, which is formed when the damaged DNA is excised. UDS can be measured as incorporation of nucleotides into DNA of the irradiated cells by autoradiography,<sup>64</sup> liquid scintillation counting,<sup>65</sup> or fluorescence assay.<sup>66</sup> Typically a reduced level of UDS confirms diagnosis of XP. Mutational analysis to assign complementation group and define pathogenic mutation(s) in the affected gene(s) is then performed. Using next-generation sequencing techniques, a platform of DNA repair genes can be used for rapid identification of both complementation group and mutation analysis.

Diagnosis of XP-V is different as XP-V cells have normal levels of UDS. However, UVR-exposed XP-V cells show an exquisite sensitivity to caffeine, which impairs their survival.<sup>67,68</sup> Therefore, if XP-V is suspected, cultured fibroblasts are incubated in caffeine for a few days and their viability compared to that of normal cells. If UDS is normal and post-UV sensitivity to caffeine is detected, a diagnosis of XP-V is confirmed.<sup>69</sup>

Of the eight genes implicated in XP, mutations in the XP-C gene count for a substantial proportion in most but not all populations.<sup>47,48,50,70</sup> Immunohistochemistry staining with an antibody for XP-C protein has recently been shown to be a new rapid and cost-effective method for both diagnosis and potentially as a screening tool in suspected XP-C patients. UVR-protected, tumour-free skin of XP-C patients will show negative expression of the XP-C protein compared to normal controls.<sup>71</sup> In principle, use of antibodies to other XP proteins can be used to also look at deficiencies in other XP complementation groups. However, although this procedure is a rapid method of identifying reductions or absence of protein, as is the case for most XP-C and XP-V patients, immunohistochemistry cannot be used as a diagnostic tool in many other complementation groups because pathogenic missense mutations result in production of a defective XP protein present in normal quantity.

All the diagnostic procedures require specialised laboratories and technical skills and are therefore often not available in poorer countries, in which there may be high incidences of XP.

## GENETIC COUNSELLING AND PRENATAL DIAGNOSIS

As XP is an autosomal recessive disorder with 100% penetrance, it is only possible to offer prenatal diagnostic testing for XP in a family where parents already have an affected child.<sup>72</sup> Counselling and psychological support is of paramount importance in families at reproductive risk. These families can have prenatal diagnosis by mutational analysis or DNA repair testing on chorionic villus sampling at 10-12 weeks gestation.<sup>73-76</sup> In principle pre-implantation genetic diagnosis can also be carried out, if the pathogenic mutations are known and the carrier status of both parents confirmed, although to our knowledge this has not yet been done for XP.

## MANAGEMENT

Patients with XP require a multidisciplinary team approach to their care with involvement from dermatologists, specialist nurses, clinical psychologists, neurologists, and ophthalmologists. Particularly in childhood, if there is recognised early cognitive impairment, XP children require support from special schools and community

mental health teams. Towards the end of their life, XP patients with severe neurodegeneration will require maximal assistance with all activities of daily living, and careful planning with all members of a multidisciplinary team is required.

As soon as the diagnosis of XP is confirmed, the most crucial aspect of their care is the instigation of meticulous photoprotection. This includes the application of sunscreen to all exposed areas of skin (20 minutes before UVR exposure), thickly woven clothing, gloves, and a UVR-protective visor. Some patients choose not to wear a visor and instead wear broad-brimmed hats, hoodies and UVR-protective wrap-round glasses. All windows in the home, car, and school should be covered with UVR-protective film, which is commercially available. Hospital theatre lights, halogen lights, metal halide lamps, and some fluorescent lights need to be avoided or covered. In addition, educational support from specialist XP nurses in the community has been shown to dramatically improve both adherence to and social acceptance of photoprotection (our unpublished audit data from the UK National XP clinic).

XP patients complying with good photoprotection are inevitably vitamin D deficient. Long-term supplementation of vitamin D in tablet, spray or in severe cases intramuscular form, should be administered and regular serum vitamin D levels checked at outpatient follow-up to ensure optimum levels are maintained.

Avoidance of cigarette smoke and environmental carcinogens are recommended. Carcinogens in cigarette smoke also cause DNA damage requiring NER, so XP patients are at higher risk of developing further lung cancer-promoting mutations.<sup>77</sup> It may be suggested that excess levels of caffeine are not recommended in XP-V patients because of cellular sensitivity to UVR in the presence of caffeine, although there is no definitive evidence to support this guidance.

The UK National XP Service was launched in April 2010 at St. John's Institute of Dermatology, Guy's and St. Thomas' NHS Trust, London, serving the current UK XP population (approximately 70 patients) and can also offer services to XP patients worldwide. Patients are invited to attend a one-stop clinic with assessments from the entire multidisciplinary team. This allows regular skin checks to assess and remove precancerous and

cancerous lesions, photographic monitoring of indeterminate lesions, as well as reviews from clinical psychology, clinical genetics, neuropsychology, neurology, and ophthalmology. Diagnostic services for XP patients, of which we are aware, are also available in the USA,<sup>78</sup> France,<sup>79</sup> Germany,<sup>80</sup> Italy,<sup>81</sup> the Netherlands,<sup>82</sup> and Japan.<sup>83</sup>

## FUTURE PROSPECTS

XP is a monogenic disorder and therefore although the future invites the possibility of protein or gene therapy, as yet there is no cure. Exciting work using retroviral-mediated XP-C gene transfer into deficient stem cell keratinocytes (from XP-C patients) has given hope that corrective therapy is not far away. However, this therapy has yet to be carried out in humans and still carries with it the risk of retroviral-mediated mutagenesis and oncogenic activation.<sup>84</sup>

Median age of death reported by the NIH is 32 years with two main causes identified as skin cancer in 34% and neurodegeneration in 31% of XP patients.<sup>50</sup> Better understanding, identification of milder phenotypes, with earlier diagnosis and improved photoprotection in recent years has resulted in an increase in median age of

death. We anticipate improved survival in those without neurodegeneration who maintain lifelong vigorous photoprotection.

## CONCLUSIONS

The diagnosis of XP has a profound consequence on patients, particularly as their lifestyle measures require rigorous photoprotection. That said, there is a dramatic reduction in the number of skin cancers and improvement in life expectancy observed with photoprotective-compliant XP patients. Unfortunately the manifestation of neurodegeneration signifies a poor prognosis. A multidisciplinary team approach is crucial for all XP patients.

With the advances in medicine and genetics over the last half-century, the spectrum of XP as a disease has become increasingly acknowledged. From the first two patients described by Moritz Kaposi,<sup>1</sup> to several thousand patients diagnosed worldwide, the field of XP requires further research, particularly to identify mechanistic links behind sunburn reactions and neurodegeneration. Most importantly, it is to be hoped that the recent rapid advances in genetics may ultimately result in a cure for this severe disorder.

## Acknowledgements

The authors are indebted to Susie Morley, Consultant Ophthalmologist and Oculoplastic Surgeon, Guy's & St Thomas' NHS Foundation Trust; Jennifer Baulcomb, Educational Psychologist, Evelina Children's Hospital; Sally Turner, XP Clinical Nurse Specialist, Guy's & St Thomas' NHS Foundation Trust for helpful comments and advice.

## REFERENCES

1. Hebra F, Kaposi M. On diseases of the skin including exanthemata. volume III. New Sydenham Soc. 1874;61:252-8.
2. De Sanctis C, Cacchione A. L'idiozia xerodermica. Rivista Sperimentale di Freniatria e Medicina Legale delle Alienazioni Mentali. 1932;56:269-92.
3. Reed WB et al. Xeroderma pigmentosum with neurological complications: the de sanctis-cacchione syndrome. Arch Derm. 1965;91:224-6.
4. Yano K. Xeroderma pigmentosum mit Störungen des Zentralnervensystems: eine histopathologische Untersuchung. Folia Psychiat Neurol Jpn. 1950;4:143-51.
5. Reed WB et al. Xeroderma pigmentosum. Clinical and laboratory investigation of its basic defect. JAMA. 1969;207:2073-9.
6. Hokkanen E et al. Zu den neurologischen Manifestationen des Xeroderma pigmentosum. Dtsch Z Nervenheilk. 1969;196:206-16.
7. Setlow RB, Carrier WL. The disappearance of thymine dimers from DNA: An error correcting mechanism. Proc Natl Acad Sci USA. 1964;51:226-31.
8. Varghese AJ, Patrick MH. Cytosine derived heteroadduct formation in ultraviolet-irradiated DNA. Nature. 1969;223:299-300.
9. Cleaver JE. Defective repair replication in xeroderma pigmentosum. Nature. 1968;218:652-6.
10. Epstein JH et al. Defect in DNA synthesis in skin of patients with xeroderma pigmentosum demonstrated in vivo. Science. 1970;168:1477-8.
11. De Weerd-Kastelein EA et al. Genetic heterogeneity of xeroderma pigmentosum demonstrated by somatic cell hybridization. Nat New Biol. 1972;238:80-3.
12. De Weerd-Kastelein, EA et al. A third complementation group in xeroderma pigmentosum. Mutat Res. 1974;22:87-91.
13. Kraemer KH et al. Genetic heterogeneity in xeroderma pigmentosum: complementation groups and their relationship to DNA repair rates. Proc Natl Acad Sci USA. 1975;72:59-63.



14. Kraemer KH et al. Five complementation groups in xeroderma pigmentosum. *Mutat Res.* 1975;33:327-40.
15. Arase S et al. A sixth complementation group in xeroderma pigmentosum. *Mutat Res.* 1979;59:143-6.
16. Kleijer WJ et al. A seventh complementation group in excision-deficient xeroderma pigmentosum. *Mutat Res.* 1979;62:183-90.
17. Burk PG et al. Ultraviolet-stimulated thymidine incorporation in xeroderma pigmentosum lymphocytes. *J Lab Clin Med.* 1971;77:759-67.
18. Burk PG et al. Xeroderma pigmentosum and DNA repair. *Lancet.* 1971;i:601.
19. Lehmann AR et al. Xeroderma pigmentosum cells with normal levels of excision repair have a defect in DNA synthesis after UV-irradiation. *Proc Natl Acad Sci USA.* 1975;72:219-23.
20. Robbins JH et al. Xeroderma pigmentosum. An inherited disease with sun sensitivity, multiple cutaneous neoplasms, and abnormal DNA repair. *Ann Intern Med.* 1974;80:221-48.
21. Kraemer KH et al. Xeroderma pigmentosum. Cutaneous, ocular, and neurologic abnormalities in 830 published cases. *Arch Dermatol.* 1987;123:241-50.
22. Lehmann AR et al. Xeroderma pigmentosum. *Orphanet J Rare Dis.* 2011;6:70.
23. DiGiovanna JJ, Kraemer KH. Shining a light on xeroderma pigmentosum. *J Invest Dermatol.* 2012;132(3 Pt 2):785-96.
24. Fassih H. Spotlight on 'xeroderma pigmentosum'. *Photochem Photobiol Sci.* 2013;12(1):78-84.
25. Khatri ML et al. Xeroderma pigmentosum in Libya. *Int J Dermatol.* 1999;38:520-4.
26. Faza B et al. Melanoma in xeroderma pigmentosum: 12 cases. *Ann Dermatol Venereol.* 2001;128:503-6.
27. Zghal M et al. Xeroderma pigmentosum: manifestations cutanees, oculaires et neurologiques a partir de 49 patients tunisiens. *Tunis Med.* 2005;83:760-3.
28. Moussaid L et al. Tumeurs cutanees au cours du xeroderma pigmentosum au Maroc. *Ann Dermatol Venereol.* 2004;131:29-33.
29. Moriwaki S, Kraemer KH. Xeroderma pigmentosum—bridging a gap between clinic and laboratory. *Photodermatol Photoimmunol Photomed.* 2001;17:47-54.
30. Hirai Y et al. Heterozygous individuals bearing a founder mutation in the XPA DNA repair gene comprise nearly 1% of the Japanese population. *Mutat Res.* 2006;601:171-8.
31. Kleijer WJ et al. Incidence of DNA repair deficiency disorders in western Europe: Xeroderma pigmentosum, Cockayne syndrome and trichothiodystrophy. *DNA Repair (Amst).* 2008;7:744-50.
32. Soufir N et al. A prevalent mutation with founder effect in xeroderma pigmentosum group C from north Africa. *J Invest Dermatol.* 2010;130:1537-42.
33. Cartault F et al. A new XPC gene splicing mutation has lead to the highest worldwide prevalence of xeroderma pigmentosum in black Mahori patients. *DNA Repair (Amst).* 2011;10(6):577-85.
34. Setlow RB et al. Evidence that xeroderma pigmentosum cells do not perform the first step in repair of ultraviolet damage to their DNA. *Proc Natl Acad Sci USA.* 1969;64:1035-41.
35. Cleaver JE. DNA repair and radiation sensitivity in human (xeroderma pigmentosum) cells. *Int J Radiat Biol Relat Stud Phys Chem Med.* 1970;18:557-65.
36. Cleaver JE. Repair of alkylation damage in ultraviolet-sensitive (xeroderma pigmentosum) human cells. *Mutat Res.* 1971;12:453-62.
37. Cleaver JE, Trokso JE. Absence of excision of ultraviolet-induced cyclobutane dimers in xeroderma pigmentosum. *Photochem Photobiol.* 1970;11:547-50.
38. Scrima A et al. Structural basis of UV DNA-damage recognition by the DDB1-DDB2 complex. *Cell.* 2008;135(7):1213-23.
39. Min JH, Pavletich NP. Recognition of DNA damage by the Rad4 nucleotide excision repair protein. *Nature.* 2007;449(7162):570-5.
40. Masutani C et al. The XPV (xeroderma pigmentosum variant) gene encodes human DNA polymerase eta. *Nature.* 1999;399:700-4.
41. Brooks PJ. DNA repair in neural cells: basic science and clinical implications. *Mutat Res.* 2002;509:93-108.
42. Brooks PJ. The 8,5'-cyclopurine-2'-deoxynucleosides: candidate neurodegenerative DNA lesions in xeroderma pigmentosum, and unique probes of transcription and nucleotide excision repair. *DNA Repair (Amst).* 2008;7(7):1168-79.
43. Marietta C et al. A single 8,5'-cyclo-2'-deoxyadenosine lesion in a TATA box prevents binding of the TATA binding protein and strongly reduces transcription in vivo. *DNA Rep (Amst).* 2002;1:967-75.
44. Brooks PJ et al. The oxidative DNA lesion 8,5'-(S)-cyclo-2'-deoxyadenosine is repaired by the nucleotide excision repair pathway and blocks gene expression in mammalian cells. *J Biol Chem.* 2000;275:22355-62.
45. Young AR. The sunburn cell. *Photodermatology.* 1987;4:127-34.
46. Boyle J et al. Persistence of repair proteins at unrepaired DNA damage distinguishes diseases with ERCC2 (XPD) mutations: cancer-prone xeroderma pigmentosum vs. non-cancer-prone trichothiodystrophy. *Human Mutat.* 2008;29(10):1194-208.
47. Sethi M et al. Patients with xeroderma pigmentosum complementation groups C, E and V do not have abnormal sunburn reactions. *Br J Dermatol.* 2013;doi: 10.1111/bjd.12523. [Epub ahead of print].
48. Totonchy MB et al. Auditory analysis of xeroderma pigmentosum 1971-2012: hearing function, sun sensitivity and DNA repair predict neurological degeneration. *Brain.* 2013;136(Pt 1):194-208.
49. Jeppesen DK et al. DNA repair deficiency in neurodegeneration. *Prog Neurobiol.* 2011;94:166-200.
50. Bradford PT et al. Cancer and neurologic degeneration in xeroderma pigmentosum: long term follow-up characterises the role of DNA repair. *J Med Genet.* 2011;48:168-76.
51. Glass AG, Hoover RN. The emerging epidemic of melanoma and squamous cell skin cancer. *JAMA* 1989;262:2097-100.
52. Kraemer KH et al. DNA repair protects against cutaneous and internal neoplasia: evidence from xeroderma pigmentosum. *Carcinogenesis.* 1984;5:511-4.
53. Brash DE et al. A role for sunlight in skin cancer: UV-induced p53 mutations in squamous cell carcinomas. *Proc Natl Acad Sci USA.* 1991;88:10124-8.
54. Daya-Grosjean L, Sarasin A. The role of UV induced lesions in skin carcinogenesis: an overview of oncogene and tumor suppressor gene modifications in xeroderma pigmentosum skin tumors. *Mutat Res.* 2005;571:43-56.
55. Giglia-Mari G, Sarasin A. TP53 mutations in human skin cancers. *Hum Mutat.* 2003;21:217-28.
56. DiGiovanna JJ et al. Xeroderma pigmentosum: spinal cord astrocytoma with 9-year survival after radiation and isotretinoin therapy. *J Cutan Med Surg.* 1998;2:153-8.
57. Kraemer KH et al. The role of sunlight and DNA repair in melanoma and nonmelanoma skin cancer. The xeroderma pigmentosum paradigm. *Arch Dermatol.* 1994;130:1018-21.
58. Hadj-Rabia S et al. Unexpected extradermatological findings in 31 patients with xeroderma pigmentosum type C. *Br J Dermatol.* 2013;168(5):1109-13.
59. Brooks BP et al. Ocular manifestations of xeroderma pigmentosum: long-term follow-up highlights the role of DNA repair in protection from sun damage. *Ophthalmology.* 2013;120(7):1324-36.
60. Gaasterland DE et al. Ocular involvement in xeroderma pigmentosum. *Ophthalmology.* 1982;89(8):980-6.
61. Anttinen A et al. Neurological symptoms and natural course of

- xeroderma pigmentosum. *Brain*. 2008;131(Pt 8):1979-89.
62. Robbins JH et al. Clinically asymptomatic xeroderma pigmentosum neurological disease in an adult: evidence for a neurodegeneration in later life caused by defective DNA repair. *Eur Neurol*. 1993;33:188-90.
63. Robbins JH, et al. Adult-onset xeroderma pigmentosum neurological disease—observations in an autopsy case. *Clin Neuropathol*. 2002;21:18-23.
64. Stefanini M et al. Differences in the levels of UV repair and in clinical symptoms in two sibs affected by xeroderma pigmentosum. *Hum Genet*. 1980;54:177-82.
65. Lehmann AR, Stevens S. A rapid procedure for measurement of DNA repair in human fibroblasts and for complementation analysis of xeroderma pigmentosum cells. *Mutat Res*. 1980;69:177-90.
66. Limsirichaikul S et al. A rapid non-radioactive technique for measurement of repair synthesis in primary human fibroblasts by incorporation of ethynyl deoxyuridine (EdU). *Nucleic Acids Res*. 2009;37:e31.
67. Lehmann AR et al. Repair of ultraviolet damage in a variety of human fibroblast cell strains. *Cancer Res*. 1977;37:904-10.
68. Arlett CF et al. The influence of caffeine on cell survival in excision-proficient and excision-deficient xeroderma pigmentosum and normal human cell strains following ultraviolet light irradiation. *Mutat Res*. 1975;33:341-6.
69. Broughton BC et al. Molecular analysis of mutations in DNA polymerase eta in xeroderma pigmentosum-variant patients. *Proc Natl Acad Sci USA* 2002;99:815-20.
70. Rivera-Begeman A et al. A novel XPC pathogenic variant detected in archival material from a patient diagnosed with xeroderma pigmentosum: a case report and review of the genetic variants reported in XPC. *DNA Repair (Amst)*. 2007;6:100-14.
71. de Feraudy S et al. Diagnosing xeroderma pigmentosum group C by immunohistochemistry. *Am J Dermatopathol*. 2010;32:109-17.
72. Messaoud O et al. The Experience of a Tunisian Referral Centre in Prenatal Diagnosis of Xeroderma pigmentosum. *Public Health Genomics*. 2013;16(5):251-4.
73. Cleaver JE et al. Prenatal diagnosis of xeroderma pigmentosum and Cockayne syndrome. *Prenat Diagn*. 1994;14(10):921-8.
74. Matsumoto N et al. DNA-based prenatal carrier detection for group A xeroderma pigmentosum in a chorionic villus sample. *Prenat Diagn*. 1995;15(7):675-7.
75. Yang Y et al. DNA-based prenatal diagnosis in a Chinese family with xeroderma pigmentosum group A. *Br J Dermatol*. 2004;150(6):1190-3.
76. Kleijer WJ et al. Prenatal diagnosis of xeroderma pigmentosum and trichothiodystrophy in 76 pregnancies at risk. *Prenat Diagn*. 2007;27(12):1133-7.
77. Maher VM et al. Mutations and homologous recombination induced in mammalian cells by metabolites of benzo[a]pyrene and 1-nitropyrene. *Environ Health Perspect*. 1987;76:33-9.
78. Basic Research Laboratory, DNA Repair Section, Center for Cancer Research, National Cancer Institute, USA.
79. Laboratory of Genomes and Cancer, Centre National de la Recherche Scientifique FRE2939, Institut Gustave Roussy, 94805 Villejuif, France.
80. CeGaT GmbH und Praxis für Humangenetik, CeGaT GmbH, Paul-Ehrlich Strasse 17, 72076 Tübingen, Germany.
81. Istituto di Genetica Molecolare - Consiglio Nazionale delle Ricerche, via Abbiategrasso 207, 27100 Pavia, Italy.
82. Laboratorium Enzymdiagnostiek, Afdeling Klinische Genetica - Sectie Genetische Metabole Ziekten, Erasmus MC, Faculteitsgebouw, Dr. Molewaterplein 50,3015 GE Rotterdam, Netherlands.
83. Department of Molecular Medicine, Atomic Bomb Disease Institute, Graduate School of Biomedical Sciences, Nagasaki University, 1-12-4, Sakamoto, Nagasaki 852-8523, Japan.
84. Warrick E et al. Preclinical corrective gene transfer in xeroderma pigmentosum human skin stem cells. *Mol Ther*. 2012;20(4):798-807.