

PERCUTANEOUS CORONARY INTERVENTION FOR CHRONIC TOTAL OCCLUSION, A REVIEW OF INDICATIONS, TECHNIQUES, AND COMPLICATIONS

***Maria-Cruz Ferrer-Gracia**

Hospital Clínico Universitario Lozano Blesa, Zaragoza, Spain

**Correspondence to mcferrer10@gmail.com*

Disclosure: The author has declared no conflicts of interest.

Received: 03.02.16 **Accepted:** 28.04.16

Citation: EMJ Int Cardiol. 2017;5[1]:85-95.

ABSTRACT

Percutaneous coronary intervention for chronic total occlusion (CTO) remains a challenging prospect for many interventional cardiologists. The treatment of these lesions is heterogeneous, as is the success rate. The aim of this review is to learn about how to approach these patients and lesions and discover the latest tendencies and research in interventional approaches in this field, as well as how to perform a useful pre-procedural approach, dual injection, lesion crossing, and modification to success. Finally, complications specific to CTO percutaneous intervention should be taken into account. Current guidelines, recommendations, and references to other significant articles which detail different aspects of management in patients with these complex lesions could be a useful guide for people beginning in this area. Algorithms of treatment, step approach, and proctoring are the current tendencies for CTO.

Keywords: Chronic total occlusion (CTO), percutaneous treatment, antegrade approach, retrograde approach.

INTRODUCTION

Chronic total occlusion (CTO) is defined as the total obstruction of a coronary artery for >3 months. This duration has implications for the histopathological characteristics and the success rates associated with intervention.

Among patients diagnosed with coronary disease on angiography, CTO are seen in ~20%,^{1,2} however rates as high as 50% can be found in patients who are receiving re-interventions, such as those who have previously had coronary artery bypass graft (CABG) surgery.^{1,3,4} Approximately 35% of CTO are currently treated by revascularisation (either CABG or percutaneous coronary intervention [PCI]). In the Canadian multicentre CTO registry, the majority of patients with CTO underwent medical treatment (64%) or were referred for CABG surgery (26%), while only 10% were referred for CTO PCI revascularisation.¹ The referral rate of CTO PCI is between 1% and 16%, suggesting several issues:

- Patients are treated according to operator expertise (specific training) and institutional

practice (high cost and resource utilisation) rather than clinical need⁵

- There are concerns regarding higher technical difficulty and perceived risk of complications compared with non-invasive treatment
- A lack of consensus regarding which patients would benefit from CTO revascularisation⁶

There are no randomised controlled data comparing recanalisation with medical therapy. The success of CTO PCI is largely dependent on the level of operator experience with different features of CTO,⁷ therefore step training of the operators in order to understand varied lesion specific characteristics is important.⁷⁻⁹

The rationale for the treatment of CTO has two key clinical decision points: first, whether to revascularise; and second, by which modality. Clinical need for revascularisation includes relief of the exercise-limiting symptoms of angina or dyspnoea, and also, prognostic factors such as improving regional left ventricular function.¹⁰ **Figure 1** shows an algorithm to guide treatment decisions in these patients and lesions.

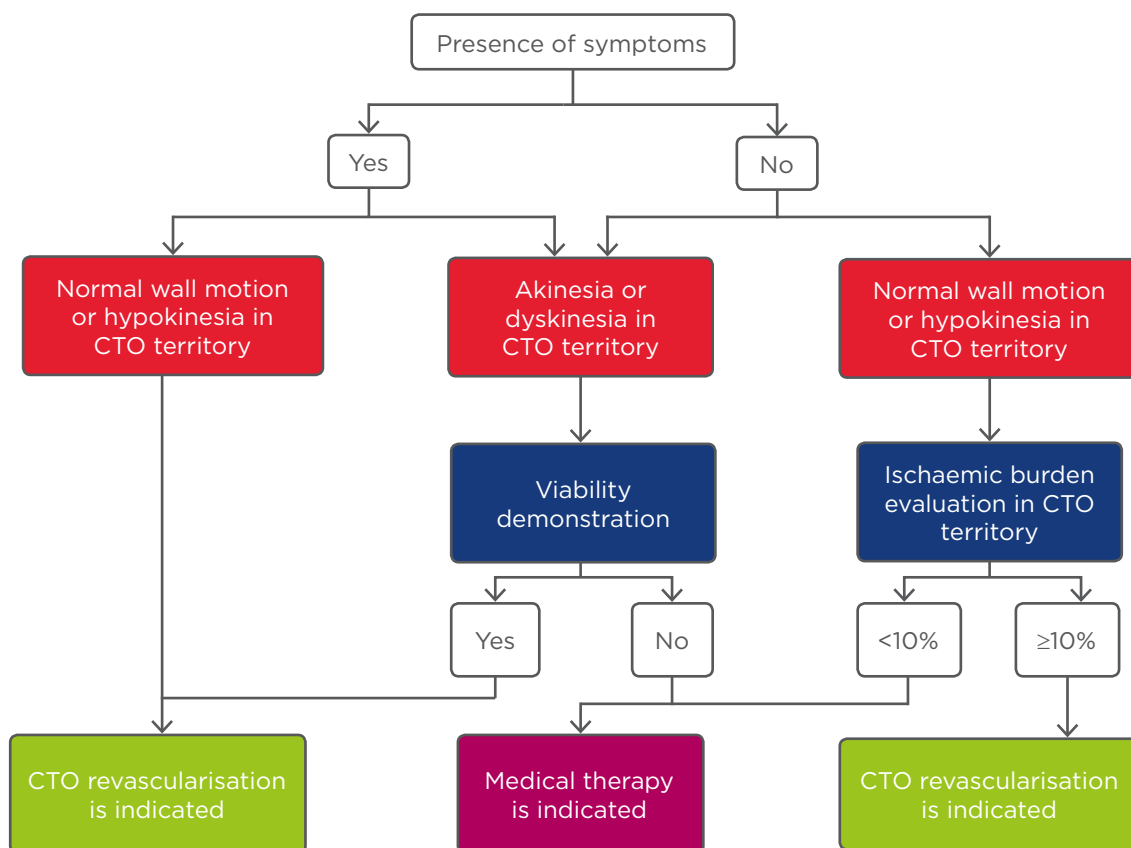


Figure 1: Algorithm of treatment in patients with chronic total occlusion.

CTO: chronic total occlusion.

Adapted from Galassi et al.¹¹ with permission.

Table 1: Chronic total occlusion percutaneous coronary intervention in current guidelines.^{12,13}

Guidelines	Class of recommendation	Level of evidence	Recommendations
European	Ila	B	Percutaneous recanalisation of CTO should be considered in patients with expected ischaemia reduction in a corresponding myocardial territory and/or angina relief.
European	IIb	B	Retrograde recanalisation of CTO may be considered after a failed antegrade approach or as the primary approach in selected patients.
American	Ila	B	PCI of a CTO in patients with appropriate clinical indications and suitable anatomy is reasonable when performed by operators with appropriate expertise.

PCI: percutaneous coronary intervention; CTO: chronic total occlusion.

Discussions of optimal treatment are reflected in the evolution of the approach to CTO treatment in European¹² and American¹³ guidelines as shown in **Table 1**. Since the publication of these guidelines, CTO PCI has undergone drastic improvements with success rates consistently >90% and major complication rates around 2% reported at several expert CTO sites.¹⁴⁻¹⁶ Taking economic aspects into

account, it is uncertain whether PCI as an initial strategy would achieve a socially acceptable cost threshold, at any level of angina severity. However, a decision-analytic model suggests that CTO PCI is cost-effective in a patient population with severe angina symptoms. Relevant quality of life metrics should be employed prior to CTO PCI.^{17,18}

GENERAL ASPECTS IN CHRONIC TOTAL OCCLUSION LESIONS

Aetiology and Origin of a Chronic Total Occlusion

The development of a CTO could happen after a myocardial infarction; it has been described in 45% of patients without treatment, in 30% of patients after thrombolysis,^{19,20} and in 5–10% of patients after failed primary PCI or vessel reocclusion.^{21,22} However, the majority (~60%) of patients with a CTO do not have a history of myocardial infarction.¹ This could be due to the recruitment of collateral vessels to counterbalance the gradual progression to an occluded artery, limiting myocardial damage and resulting in mild or absent clinical symptoms.²³

Histopathology

Anatomopathological studies of patients in whom a CTO was identified at least 3 months before, showed that thrombotic occlusion progressed over time from soft to hard. Long-term CTO, particularly without previous CABG, also have a high prevalence of negative remodelling.²⁴ Hard intimal plaques are characterised by calcification. Although severity and extent of calcification and the collagen content of the intimal plaque increases with the duration of CTO, calcium is present in 54% of occlusions <3 months old. Within CTO lesions, microchannels are often observed and they might facilitate lesion crossing during CTO PCI. Microchannels mostly lead into the adventitia, small side branches, or vasa vasorum; however, they can also extend from the proximal to the distal lumen.²⁵ These differences, along with an abrupt and tapering pattern of proximal and distal lumens, are likely to affect the success rate of PCI in CTO. Furthermore, the prevalence of the tapering pattern in the distal lumen was significantly higher than that in the proximal lumen, suggesting the advantage of a retrograde approach.²⁴

Coronary Collateral Circulation

Anastomotic channels represent a native system for coronary arterial bypass allowing bidirectional flow. Collaterals therefore provide an alternative source of blood supply to the myocardium jeopardised by occlusive coronary artery disease, and they can help to preserve myocardial function in the setting of a CTO.^{26,27}

Coronary collateral pathways are present in >70% of patients with either complete artery occlusion or coronary stenosis >90%.²⁸

It is important to note that angiographically visualised collateral vessels do not always indicate myocardial viability. Thus a viability assessment should be undertaken before considering CTO recanalisation in patients with abnormal regional wall motion. In an invasive study using fractional flow reserve, <10% of collaterals provided a normal functional reserve during pharmacological stress.²⁹ Cardiac magnetic resonance imaging with pharmacological stress testing, perfusion, and contrast enhancement is the optimal assessment to determine whether CTO PCI is indicated in patients without severe symptoms or ischaemia.^{6,30} In patients with evidence of significant myocardial inducible perfusion defect and viability on cardiac magnetic resonance, CTO recanalisation reduces ischaemic burden, favours reverse remodelling, and ameliorates quality of life.^{31,32} Positron emission tomography/computed tomography,³³ perfusion contrast echocardiography,³⁴ and scintigraphy³⁵ may be used as alternatives to magnetic resonance imaging.

From a technical standpoint, understanding the presence, quality, and location of collateral vessels is key to maximising the likelihood of CTO recanalisation procedural success. Dual injections of the CTO PCI target vessel and the donor artery or branch reveals the presence, size, and tortuosity of the collateral vessels and helps determine whether a retrograde approach is feasible.⁴ The presence of collateral flow does not seem to predict later restenosis or re-occlusion of the target vessel.³⁶

Clinical and Epidemiological Characteristics of Patients with Chronic Total Occlusion

Patients affected by CTO sometimes show atypical symptoms; shortness of breath and exercise limitation are more frequently observed than typical angina.¹¹ CTO are frequent in patients with relevant coronary artery disease (CAD), >50% have well-preserved left ventricular function, and ~80% have no Q-waves in the CTO territory suggesting viable myocardium.^{1,2,37} In patients with diagnosed CTO the mean age is 66±11 years; they also have a higher prevalence of all cardiovascular risk factors and previous myocardial infarction than patients with CAD but not CTO.¹

There are sex differences: 80% of patients with CAD and CTO are men,¹ and women who receive a CTO PCI tend to be older, have higher rates of hypertension and diabetes mellitus, and are less likely to smoke compared with male patients. Moreover, female patients more often have a CTO located in the left anterior descending coronary artery, shorter and fewer blunt stumps and bridging collaterals than men, and are less likely to develop multivessel disease (MVD). However, after multivariable adjustment for known predictors, sex was not associated with CTO PCI failure.³⁸

Indications of Treatment

There are three main reasons to recommend a CTO recanalisation:

- To relieve the exercise limiting symptoms of angina or dyspnoea, and, in moderately symptomatic patients, to resolve ischaemia detected by non-invasive stress testing
- To improve regional left ventricular function in the territory of the occluded artery
- To improve the prognosis of the patient as there is considerable risk of future progression of CAD in the remaining patent arteries¹⁰

CTO PCI is indicated when occlusion of an artery leads to angina, ischaemia,^{11,12} left ventricular dysfunction, and electrical instability, especially when the left anterior descending coronary artery is involved.⁶ Registries of patients with CTO showed that successful percutaneous revascularisation is associated with improved clinical outcomes: improvements in angina and quality of life,³⁹ a potential improvement in electrical myocardial stability,^{32,40} a reduced need for CABG surgery,⁴¹ enhanced tolerance of future coronary events; increased left ventricular function.^{42,43} and in the context of complete coronary revascularisation, a substantial increase in survival.^{41,44-48}

A rate of 10-12.5% of myocardium 'at risk' was recognised to be the cut-off point above which percutaneous treatment shows clear survival benefit for patients.² However, in 2011 the STICH investigators reported that after correction of other prognostic variables, the presence of myocardial viability was no longer significantly associated with mortality. These findings bring into question whether left-ventricular ejection fraction recovery is completely dependent of myocardial viability, but might support the electrical or the 'reserve' hypothesis. In this hypothesis, patients

with a CTO might be more prone to future cardiovascular events and have less reserve, especially during an acute occlusion in one of the remaining coronary arteries.⁴⁹

PERCUTANEOUS TREATMENT OF CHRONIC TOTAL OCCLUSION

A detailed review of the techniques and materials available for CTO PCI are beyond the scope of this paper, however below is a summary of current recommendations and treatment algorithms which provide a useful introduction to the subject area.

Pre-Procedural Approach

The most widely used score to predict the overall likelihood of successful CTO PCI is the JCTO (Japanese Multicenter CTO Registry) score.⁵⁰ It uses independent angiographic predictors of failure (each given one point): prior failed attempt, angiographic evidence of heavy calcification, bending within the occluded segment, blunt proximal stump, and occlusion length >20 mm. CTO were graded as easy, intermediate, difficult, and very difficult (JCTO scores of 0, 1, 2, and ≥3, respectively). In addition to crossing times, the JCTO score appears to correlate with long-term success.¹⁶

In addition, other independent predictors of failure were derived from the use of coronary computed tomography angiography (CCTA): occlusion length >20 mm, multiple occlusions, blunt stump, bending, and severe calcification in the CTO segment. Clinical predictors of failure included a previously failed PCI revascularisation and duration of CTO >12 months or unknown duration of occlusion. The use of CCTA is controversial because the indication of treating a CTO is a clinical one, and should not be made on the basis of the ease or difficulty of the case. As such, these scores are useful for identifying highly complex cases that should be referred to expert centres.

Although CCTA is generally seen as having limited clinical value, it offers assessment of:

- The length and three dimensional course of the occluded arterial segment
- The presence of calcium at the CTO
- The vessel size and vessel remodelling (either positive or negative)
- The quality of the vessel distal to the CTO

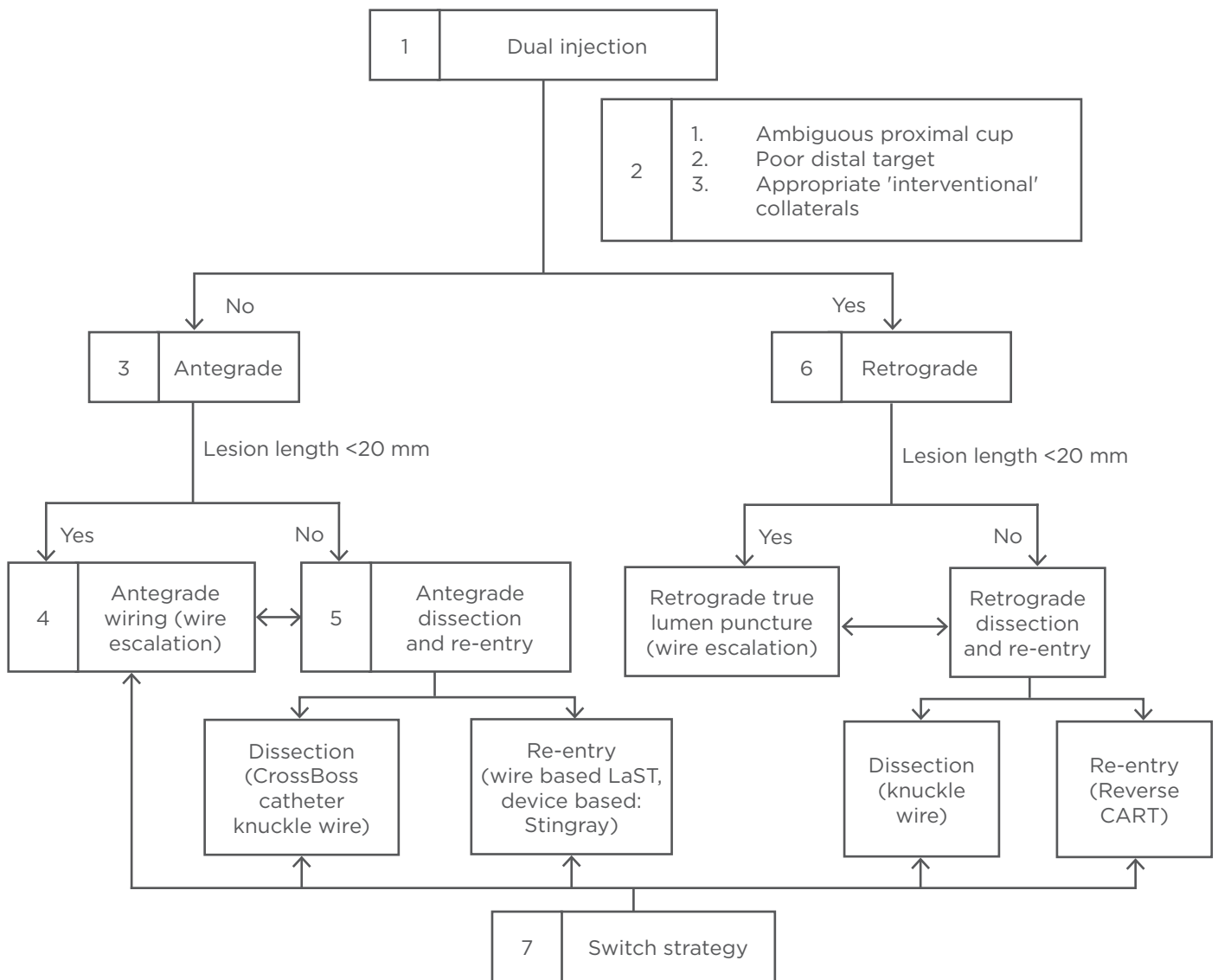


Figure 2: The American hybrid approach.

According to point 5 the ‘move the cap’ technique can facilitate antegrade crossing of CTO with ambiguous or impenetrable cap using either a stiff guidewire (scratch and go), or a proximal balloon inflation to cause limited dissection to facilitate subintimal guidewire entry (balloon assisted technique). This entry in the subintimal space is followed by antegrade dissection re-entry lesion crossing.⁵⁹ Stingray, Boston Scientific, Marlborough, Massachusetts, USA; Crossboss catheter knuckle wire, Boston Scientific. CTO: chronic total occlusion; LaST: limited antegrade subintimal tracking; CART: controlled antegrade and retrograde tracking.

Adapted from Brilakis et al.⁵¹ and Touma et al.⁵⁶

Patients presenting with an acute coronary syndrome require expedited recanalisation of the culprit vessel. Whenever a CTO in a non-culprit vessel is incidentally found, the patient should be given time to recover from the cardiac, vascular, and renal effects of acute coronary syndrome and PCI. A minimum of 1-2 weeks should elapse between treatment of the culprit lesion and planned treatment of a CTO. There is evidence that leaving a totally occluded artery untreated

is associated with higher mortality at short and long-term follow-up post-ST-segment elevation myocardial infarction.^{2,12}

Interventional procedures should be carefully planned; *ad hoc* angioplasty is not recommended. The operator should spend time examining the diagnostic films to decide if a unilateral or bilateral approach is required, to choose appropriate vascular access routes and dedicated equipment, and to guide catheter shape and size.

Finally, remember that time constraint in the catheterisation laboratory is one of the factors linked with procedural failure.⁵¹ Proper catheterisation laboratory planning for a minimum of 2 hours is essential.²

The selection of the access route is dependent on the individual patient situation (e.g. severe peripheral vascular disease may mandate a radial approach). The radial artery could be used for either contralateral injection (5 or 6 Fr diagnostic catheters) or CTO treatment with 7 Fr sheathless guiding catheter.⁵² However, most experts use the femoral approach for the target CTO vessel (90% in Europe).^{2,12}

When the distal vessel is mainly filled by retrograde collaterals, or there are bridging collaterals originating near the occlusion that are likely to have their flow impaired after wire-catheter advancement, contralateral injection is essential from the beginning of the procedure.² When distal flow comes from a proximal branch of the occluded vessel, an 8 Fr catheter can be used to perform selective injections in this branch with a microcatheter and cross in parallel the rest of the material to work in the occluded segment. Occasionally, single vascular access has been used to perform contralateral injections with different manoeuvres.^{53,54} Furthermore, single catheter antegrade injection should be avoided once dissection occurs in the antegrade space with subintimal entry as it may result in haematoma expansion.⁵⁵ Bilateral access is therefore frequently needed.

Regarding a CTO there are two methodological approaches: the Japanese (proximal-to-distal) approach,¹¹ and the American hybrid approach (Figure 2).⁵¹ The technical aspects, and pros and cons of each one were recently explained in an interesting review by Touma et al.⁵⁶ In Europe and America the hybrid strategy has more followers, and it has also been used in CTO caused by in-stent restenosis.^{57,58}

The hybrid approach is a systematic algorithm-led PCI strategy based on the identification of key anatomical features on baseline angiography.⁵¹ It introduces a structured approach, the main aim being to provide a reproducible, easily taught, and proctored technique for CTO PCI.⁶⁰

This approach requires operator familiarity with all the available CTO PCI materials, techniques, and skillsets (antegrade wire escalation, antegrade

dissection/re-entry with dedicated devices,⁶¹ and retrograde wire escalation and dissection re-entry). Flexibility with the various approaches, and timely change of strategies, is at the heart of the hybrid algorithm.

The limitations of disseminating the Japanese approach relate to cost and laboratory time. This approach is also highly individualised, making it difficult to teach and disseminate. Unique to Japan is the situation where patient preference results in low rates of CABG and this results in preferential treatment with PCI. Long case-duration may not be feasible when laboratory time is limited. Concerns have been raised over radiation and contrast volume during protracted cases.⁵⁶

Lesion Crossing

In addition to strategies to facilitate lesion crossing and lesion modification, guidewire selection greatly influences the ability of an operator to successfully cross a lesion and wire the distal vessel true lumen. A variety of guidewires⁵⁶ and supplementary manoeuvres specific to lesion subsets are available. In the JCTO trial, utilisation of advanced guidewires facilitated successful lesion crossing in 88.6% of CTO cases.⁵⁰ It should be remembered that CTO-specific guidewires are more prone to enter subintimal channels, and may increase the risk of perforation. In order to increase the support to cross the lesion different techniques and devices can be used, including: anchor balloon support techniques, extension catheters, and microcatheters.

Lesion Modification

Once the lesion has been successfully crossed, further challenges related to lesion modification can arise. These modifications should be considered last resort measures where standard techniques have proved unsuccessful, taking into account the fact that in CTO they are all off-license settings;^{62,63} very high pressure non-compliant balloon dilation, balloon assisted micro-dissection, excimer laser coronary atherectomy, and/or high speed rotational ablation.

Stent Implantation

After successful procedures, implantation of drug-eluting stents (DES) is recommended. DES lead to an incremental 60% reduction in the relative risk of repeat revascularisation after CTO PCI.⁶⁴ Clinical and angiographic restenosis rates are

higher after DES of CTO compared to non-CTO, at least in part due to the diffuseness of disease, calcification, and number and length of stents required. Current generation DES may improve upon the results of first-generation DES after successful CTO recanalisation. The patency rate after CTO PCI at 69-month follow-up is approximately 90% for first-generation DES (sirolimus and paclitaxel-eluting stents), 97% for everolimus-eluting stents,⁶⁵ and 94.3% for bioresorbable everolimus-eluting vascular scaffold (BVS).⁶⁶ Before BVS can be recommended for routine application to CTO several issues must be addressed, these include their greater profile, tendency toward more recoil, and healing properties (particularly with subintimal implantation).⁶⁷ Recently, similar clinical and angiographic outcomes in CTO revascularisation with zotarolimus and everolimus-eluting stents have also been discovered. Stent length, but not type of stent, was predictive for in-stent late loss and target lesion revascularisation rate.⁶⁸

For the clinical community there are two interesting trials in progress: the EuroCTO and the DECISION-CTO,^{69,70} both of which compare PCI with DES

and optimal medical therapy or optimal medical therapy alone. After these are complete we will have more evidence of the best option for treatment.

Complications and Outcomes in Chronic Total Occlusion Percutaneous Coronary Intervention

There are several general and specific complications related to this procedure such as contrast induced nephropathy (CIN) and radiodermatitis. The overall rates of adverse short-term clinical outcomes after percutaneous CTO intervention are declining (Table 2) and the current rates are approaching that of non-CTO PCI (Table 3).³

Of paramount significance is the prevention of CIN during the CTO recanalisation procedure. Most operators would wish to keep dye load even in patients with normal estimated glomerular filtration rate (GFR) <400 mL, in the EuroCTO Club consensus the maximal amount is defined as 4 x GFR (mL). When planning a second attempt, it is advised to wait between 3 and 4 weeks.² The risk of incidence of CIN was not different between the successful and failed CTO PCI group (7.2% versus 6.5%, p=0.45).⁴⁴

Table 2: Evolution of success and procedural complications in large registries of chronic total occlusion percutaneous coronary intervention.

Author	Year	CTO lesions (n)	Retrograde (%)	Technical success (%)	Major complications (%)	Death (%)	Tamponade (%)
Rathore et al. ⁷¹	2009	904	17	87.5	1.9	0.6	0.6
Morino et al. ⁷²	2010	528	26	86.6	NR	0.4	0.4
Galasi et al. ³⁷	2011	1,983	14	82.9	1.8	0.3	0.5
Michael et al. ⁷³	2013	1,361	34	85.5	1.8	0.22	0.6

CTO: chronic total occlusion; PCI: percutaneous coronary intervention; NR: not reported.

Table 3: Comparison of in-hospital clinical outcomes between chronic total occlusion and elective non-chronic total occlusion percutaneous coronary intervention.

Clinical outcomes	Elective non-CTO PCI (%)	Current rates with successful CTO PCI (%)	Current rates with failed CTO PCI (%)
Death	0.2-0.3	0.1	0.8
Myocardial infarction	2.0	2.0	2.3
Urgent CABG	0.1-0.3	0.13	0.7

CTO: chronic total occlusion; PCI: percutaneous coronary intervention; CABG: coronary artery bypass graft. Adapted from Khan et al.³

The Mehran score⁷⁴ suggested that 'very high-risk group' (≥ 16) classification and angiographic severe tortuosity were the predictors of CIN in CTO PCI. In daily practice, more careful hydration before and after the procedure, lower contrast volumes during the procedure, and precise follow-up after the procedure should be applied to these high-risk patients.^{2,74,75} Use of limited pre-procedural multislice spiral computed tomography, retrogradely positioned wires as markers (rather than using contrast injections), and intravascular ultrasound may all help to reduce dye load.²

Exposure to radiation is an important consideration; during CTO PCI it is necessary to make every effort to reduce radiation exposure (to the patient and the operator) and to document radiation exposure during the procedure. The procedure should be stopped when radiation reaches a maximum of 10 Gy. Strategies to reduce exposure could include using a frame rate for fluoroscopy of 7.5 pulses/s and changing projection.²

Urgent CABG in patients undergoing PCI for CTO could be needed in three common scenarios. Firstly, mechanical trauma to a vessel resulting in frank perforation and/or tamponade requires emergency cardiac surgery. Secondly, the inability to recanalise a CTO in the presence of MVD even in the absence of complications prompts a need for urgent bypass surgery in some symptomatic patients. Thirdly, in some patients with MVD and successful CTO intervention, post-PCI acute stent thrombosis can be managed with urgent CABG.

Complications unique to the retrograde approach may involve the occluded vessel (retrograde perforation/dissection), the collaterals (rupture/haematoma of the septal or epicardial collaterals, perforation to the right or left ventricle, septal wire trapping, epicardial flow disruption with ischaemia), and the donor artery (potentially life-threatening dissection/thrombosis, spasm leading to ischaemia). The most common of these are related to the collateral vessels, but they tend to be minor and easily treatable in the majority of cases. However, perforation of epicardial collaterals, particularly in patients without prior open heart surgery, can be associated with tamponade and rapid haemodynamic compromise.

Although coronary perforations are common in CTO PCI (27.6%),⁷¹ most perforations are related to localised wire exit from the vessel architecture and are limited to angiographic evidence of

contrast staining. As most perforations do not have serious clinical consequences, the risk of tamponade is low (0.3%).⁷⁶ However, clinically significant coronary perforations can be associated with significant morbidity and mortality, with reported rates of death of 42%, emergency surgery of 39%, myocardial infarction of 29%, and transfusion of 65% in series not limited to CTO PCI.⁷⁷ Management of perforations includes:

- prolonged balloon inflation across the perforation
- reversal of anticoagulation (not completely to avoid target and donor vessel thrombosis)
- covered stent placement, emergency surgery, or embolisation (coils, microsphere injection)
- pericardiocentesis

Experience in managing vascular and haemorrhagic complications is required since most CTO PCIs are performed through 8 Fr femoral sheaths, and the activated clotting time is kept in the 300 secs range during retrograde procedures.² When feasible, the radial approach has fewer access site complications.⁷⁸

Post-procedural deaths in patients can be broadly divided into two main categories: those directly related to procedural complications (perforation and tamponade), and those secondary to stent related complications such as acute stent thrombosis. However, deaths in patients with failed CTO intervention seem to be closely related to procedural complications as evidenced by higher rates of coronary perforation and cardiac tamponade (7.4% and 1.9% versus 1.16% and 0.2%, respectively) in this group. The risk of peri-procedural death as a result of a failed CTO PCI attempt ranges from 0.8-1.4%, which is still lower than the peri-operative mortality for CABG (1.76-3.5%).⁷⁹

Outcomes following PCI CTO have been improving during recent years. Success rates in the treatment of complex CTO are 90-95%. They remain in the hands of a few dedicated expert operators, however the spreading of the hybrid approach algorithm, including the proctor's help in difficult cases, is promising.^{60,80,81} These rates imply a huge knowledge about antegrade and retrograde techniques, dedicated materials such as catheters, guidewires, microcatheters, and catheter extensions, and how to manage complementary techniques such as CCTA and intravascular ultrasound.⁷ A recently published meta-analysis³ showed that,

compared with a successful percutaneous CTO intervention, a failed CTO PCI is associated with higher rates of procedural complications: in-hospital mortality (1.44% versus 0.5%; relative risk [RR]: 2.88; $p < 0.001$), peri-procedural major adverse cardiac event (8.88% versus 3.75%; RR: 2.25), myocardial infarction (3.17% versus 2.4%; RR: 1.35; $p = 0.032$), and urgent revascularisation with bypass surgery (4.0% versus 0.5%; RR: 6.67; $p < 0.001$).

Outcomes after CTO PCI may be enhanced by proper patient selection (resistant angina, large areas of ischaemia, and anatomic suitability for antegrade, retrograde, and/or subintimal recanalisation) and by reliance on expert operators using a flexible incremental approach to recanalisation.

There is evidence that successful CTO PCI results in improved long-term outcomes; however, a failed procedure is also associated with a higher risk of complications and adverse short-term outcomes. Therefore, patient selection for percutaneous CTO intervention should be individualised based on the risks of complications (probability of failed intervention) versus the benefits of improved long-term outcomes (in cases of successful PCI). Careful assessment of lesion morphology and other scores of risk, along with operator's personal experience to deal with the specific lesion subtype is paramount before embarking on the procedure. Successful revascularisation correlates strongly with operator experience. For senior operators in high-risk complex CTO, proctoring and referral centres should be considered.

REFERENCES

1. Fefer P et al. Current perspectives on coronary chronic total occlusions: the Canadian Multicenter Chronic Total Occlusions Registry. *J Am Coll Cardiol*. 2012;59(11):991-7.
2. Sianos G et al. Recanalisation of chronic total coronary occlusions: 2012 consensus document from the EuroCTO club. *EuroIntervention*. 2012;8(1):139-45.
3. Khan MF et al. Comparison of procedural complications and in-hospital clinical outcomes between patients with successful and failed percutaneous intervention of coronary chronic total occlusions: a meta-analysis of observational studies. *Catheter Cardiovasc Interv*. 2015;85(5):781-94.
4. Brilakis ES et al. The retrograde approach to coronary artery chronic total occlusions: a practical approach. *Catheter Cardiovasc Interv*. 2012;79(1):3-19.
5. Carlino M et al. Treatment of the chronic total occlusion: a call to action for the interventional community. *Catheter Cardiovasc Interv*. 2015;85(5):771-8.
6. Hoebbers LP et al. Contemporary overview and clinical perspectives of chronic total occlusions. *Nat Rev Cardiol*. 2014;11(8):458-69.
7. Habara M et al. Comparison of percutaneous coronary intervention for chronic total occlusion outcome according to operator experience from the Japanese retrograde summit registry. *Cathet Cardiovasc Intervent*. 2016;87(6):1027-35.
8. Stone GW et al. Percutaneous recanalization of chronically occluded coronary arteries: procedural techniques, devices, and results. *Catheter Cardiovasc Interv*. 2005;66(2):217-36.
9. Singbal Y, Lim R. Training Standards and Recommendations for Intervention on Chronic Total Occlusions. *Curr Cardiol Rev*. 2015. [Epub ahead of print].
10. Werner GS, "Chronic total occlusions," Eeckhout E et al. (eds.), *Percutaneous Interventional Cardiovascular Medicine The PCR-EAPCI Textbook*. II. (2012) 1st edition, Toulouse:PCR, pp.407-53.
11. Galassi AR et al. Appropriateness of percutaneous revascularization of coronary chronic total occlusions: an overview. *Eur Heart J*. 2015. [Epub ahead of print].
12. Windecker S et al. 2014 ESC/EACTS Guidelines on myocardial revascularization: The Task Force on Myocardial Revascularization of the European Society of Cardiology (ESC) and the European Association for Cardio-Thoracic Surgery (EACTS) Developed with the special contribution of the European Association of Percutaneous Cardiovascular Interventions (EAPCI). *Eur Heart J*. 2014;35(37):2541-619.
13. Levine GN et al. 2011 ACCF/AHA/SCAI Guideline for Percutaneous Coronary Intervention. A report of the American College of Cardiology Foundation/American Heart Association Task Force on Practice Guidelines and the Society for Cardiovascular Angiography and Interventions. *J Am Coll Cardiol*. 2011;58(24):e44-122.
14. Nombela-Franco L et al. Validation of the J-chronic total occlusion score for chronic total occlusion percutaneous coronary intervention in an independent contemporary cohort. *Circ Cardiovasc Interv*. 2013;6(6):635-43.
15. Karpaliotis D, Green P. Chronic total occlusion percutaneous coronary intervention in 2014 beyond the J-CTO score (Japanese Multicenter CTO Registry): chance favors the prepared mind. *JACC Cardiovasc Interv*. 2015;8(2):268-70.
16. Tanaka H et al. Impact of J-CTO score on procedural outcome and target lesion revascularisation after percutaneous coronary intervention for chronic total occlusion: a substudy of the J-CTO Registry (Multicentre CTO Registry in Japan). *EuroIntervention*. 2016;11(9):981-8.
17. Zhang Z et al. The cost-effectiveness of percutaneous coronary intervention as a function of angina severity in patients with stable angina. *Circ Cardiovasc Qual Outcomes*. 2011;4(2):172-82.
18. Gada H et al. Establishing the cost-effectiveness of percutaneous coronary intervention for chronic total occlusion in stable angina: a decision-analytic model. *Heart*. 2012;98(24):1790-7.
19. Stone GW et al. Percutaneous recanalization of chronically occluded coronary arteries: a consensus document: part I. *Circulation*. 2005;112(15):2364-72.
20. Veen G et al. Culprit lesion morphology and stenosis severity in the prediction of reocclusion after coronary thrombolysis: angiographic results of the APRICOT study. Antithrombotics in the Prevention of Reocclusion in Coronary Thrombolysis.

- J Am Coll Cardiol. 1993;22(7):1755-62.
21. Grines CL et al. A comparison of immediate angioplasty with thrombolytic therapy for acute myocardial infarction. The Primary Angioplasty in Myocardial Infarction Study Group. *N Engl J Med.* 1993;328(10):673-9.
 22. Stone GW et al. Comparison of angioplasty with stenting, with or without abciximab, in acute myocardial infarction. *N Engl J Med.* 2002;346(13):957-66.
 23. Habib GB et al. Influence of coronary collateral vessels on myocardial infarct size in humans. Results of phase I thrombolysis in myocardial infarction (TIMI) trial. The TIMI Investigators. *Circulation.* 1991;83(3):739-46.
 24. Sakakura K et al. Comparison of pathology of chronic total occlusion with and without coronary artery bypass graft. *Eur Heart J.* 2014;35(25):1683-93.
 25. Srivatsa SS et al. Histologic correlates of angiographic chronic total coronary artery occlusions: influence of occlusion duration on neovascular channel patterns and intimal plaque composition. *J Am Coll Cardiol.* 1997;29(5):955-63.
 26. Karrowni W et al. Coronary collateral circulation: its relevance. *Catheter Cardiovasc Interv.* 2013;82(6):915-28.
 27. Werner GS et al. Collateral function in chronic total coronary occlusions is related to regional myocardial function and duration of occlusion. *Circulation.* 2001;104(23):2784-90.
 28. Gensini G. "Arterial anastomoses in the Coronary Circulation: The Coronary Collaterals", Gensini G (ed.), *Coronary arteriography (1975) 1st edition*, New York: Futura Publishing, pp.321-54.
 29. Werner GS et al. The functional reserve of collaterals supplying long-term chronic total coronary occlusions in patients without prior myocardial infarction. *Eur Heart J.* 2006;27(20):2406-12.
 30. Cheng AS et al. Percutaneous treatment of chronic total coronary occlusions improves regional hyperemic myocardial blood flow and contractility: insights from quantitative cardiovascular magnetic resonance imaging. *JACC Cardiovasc Interv.* 2008;1(1):44-53.
 31. Bucciarelli-Ducci C et al. CMR Guidance for Recanalization of Coronary Chronic Total Occlusion. *JACC Cardiovasc Imaging.* 2016. [Epub ahead of print].
 32. Rossello X et al. Assessment of Inducible Myocardial Ischemia, Quality of Life, and Functional Status After Successful Percutaneous Revascularization in Patients With Chronic Total Coronary Occlusion. *Am J Cardiol.* 2016;117(5):720-6.
 33. Stuijzfand WJ et al. Value of Hybrid Imaging with PET/CT to Guide Percutaneous Revascularization of Chronic Total Coronary Occlusion. *Curr Cardiovasc Imaging Rep.* 2015;8(7):26.
 34. Cho JS et al. Usefulness of the parameters of quantitative myocardial perfusion contrast echocardiography in patients with chronic total occlusion and collateral flow. *Echocardiography.* 2015;32(3):475-82.
 35. Galassi AR et al. Prognostic value of exercise myocardial scintigraphy in patients with coronary chronic total occlusions. *J Interv Cardiol.* 2010;23(2):139-48.
 36. Werner GS et al. Determinants of target vessel failure in chronic total coronary occlusions after stent implantation. The influence of collateral function and coronary hemodynamics. *J Am Coll Cardiol.* 2003;42(2):219-25.
 37. Galassi AR et al. In-hospital outcomes of percutaneous coronary intervention in patients with chronic total occlusion: insights from the ERCTO (European Registry of Chronic Total Occlusion) registry. *EuroIntervention.* 2011;7(4):472-9.
 38. Claessen BE et al. Gender differences in long-term clinical outcomes after percutaneous coronary intervention of chronic total occlusions. *J Invasive Cardiol.* 2012;24(10):484-8.
 39. Grantham JA et al. Quantifying the early health status benefits of successful chronic total occlusion recanalization: Results from the FlowCardia's Approach to Chronic Total Occlusion Recanalization (FACTOR) Trial. *Circ Cardiovasc Qual Outcomes.* 2010;3(3):284-90.
 40. Nombela-Franco L et al. Ventricular arrhythmias among implantable cardioverter-defibrillator recipients for primary prevention: impact of chronic total coronary occlusion (VACTO Primary Study). *Circ Arrhythm Electrophysiol.* 2012;5(1):147-54.
 41. Khan MF et al. Effects of percutaneous revascularization of chronic total occlusions on clinical outcomes: a meta-analysis comparing successful versus failed percutaneous intervention for chronic total occlusion. *Catheter Cardiovasc Interv.* 2013;82(1):95-107.
 42. Kirschbaum SW et al. Combining magnetic resonance viability variables better predicts improvement of myocardial function prior to percutaneous coronary intervention. *Int J Cardiol.* 2012;159(3):192-7.
 43. Roifman I et al. The effect of percutaneous coronary intervention of chronically totally occluded coronary arteries on left ventricular global and regional systolic function. *Can J Cardiol.* 2013;29(11):1436-42.
 44. Borgia F et al. Improved cardiac survival, freedom from MACE and angina-related quality of life after successful percutaneous recanalization of coronary artery chronic total occlusions. *Int J Cardiol.* 2012;161(1):31-8.
 45. Jolicœur EM et al. Percutaneous coronary interventions and cardiovascular outcomes for patients with chronic total occlusions. *Catheter Cardiovasc Interv.* 2012;79(4):603-12.
 46. Jones DA et al. Successful recanalization of chronic total occlusions is associated with improved long-term survival. *JACC Cardiovasc Interv.* 2012;5(4):380-8.
 47. Mehran R et al. Long-term outcome of percutaneous coronary intervention for chronic total occlusions. *JACC Cardiovasc Interv.* 2011;4(9):952-61.
 48. Niccoli G et al. Late (3 years) follow-up of successful versus unsuccessful revascularization in chronic total coronary occlusions treated by drug eluting stent. *Am J Cardiol.* 2012;110(7):948-53.
 49. Bonow RO et al. Myocardial viability and survival in ischemic left ventricular dysfunction. *N Engl J Med.* 2011;364(17):1617-25.
 50. Morino Y et al. Predicting successful guidewire crossing through chronic total occlusion of native coronary lesions within 30 minutes: the J-CTO (Multicenter CTO Registry in Japan) score as a difficulty grading and time assessment tool. *JACC Cardiovasc Interv.* 2011;4(2):213-21.
 51. Brilakis ES et al. A percutaneous treatment algorithm for crossing coronary chronic total occlusions. *JACC Cardiovasc Interv.* 2012;5(4):367-79.
 52. Kwan TW et al. Feasibility and safety of 7F sheathless guiding catheter during transradial coronary intervention. *Catheter Cardiovasc Interv.* 2012;80(2):274-80.
 53. Ferrer-Gracia MC et al. Sequential contralateral injection through the same transradial vascular approach in a chronic total occlusion. *Postepy Kardiol Interwencyjne.* 2015;11(2):152-3.
 54. Kiemeneij F. Simultaneous transradial coronary angioplasty and contralateral coronary angiography with a single guide catheter for total coronary occlusions. *J Invasive Cardiol.* 2014;26(2):87-90.
 55. Yamane M. Current percutaneous recanalization of coronary chronic total occlusion. *Rev Esp Cardiol (Engl Ed).* 2012;65(3):265-77.
 56. Touma G et al. Chronic total occlusions - Current techniques and future directions. *Int J Cardiol Heart Vascul.* 2015;7:28-39.
 57. Wilson WM et al. A novel approach to the management of occlusive in-stent restenosis (ISR). *EuroIntervention.* 2014;9(11):1285-93.
 58. Christopoulos G et al. The efficacy of "hybrid" percutaneous coronary

- intervention in chronic total occlusions caused by in-stent restenosis: insights from a US multicenter registry. *Catheter Cardiovasc Interv.* 2014;84(4):646-51.
59. Vo MN et al. "Move the cap" technique for ambiguous or impenetrable proximal cap of coronary total occlusion. *Catheter Cardiovasc Interv.* 2016;87(4):742-8.
60. Sharma V et al. Impact of proctoring on success rates for percutaneous revascularisation of coronary chronic total occlusions. *Open Heart.* 2015;2(1):e000228.
61. Whitlow PL et al. Use of a novel crossing and re-entry system in coronary chronic total occlusions that have failed standard crossing techniques: results of the FAST-CTOs (Facilitated Antegrade Steering Technique in Chronic Total Occlusions) trial. *JACC Cardiovasc Interv.* 2012;5(4):393-401.
62. Fairley SL et al. Adjunctive strategies in the management of resistant, 'undilatable' coronary lesions after successfully crossing a CTO with a guidewire. *Curr Cardiol Rev.* 2014;10(2):145-57.
63. Fernandez JP et al. Beyond the balloon: excimer coronary laser atherectomy used alone or in combination with rotational atherectomy in the treatment of chronic total occlusions, non-crossable and non-expandable coronary lesions. *EuroIntervention.* 2013;9(2):243-50.
64. Colmenarez HJ et al. Efficacy and safety of drug-eluting stents in chronic total coronary occlusion recanalization: a systematic review and meta-analysis. *J Am Coll Cardiol.* 2010;55(17):1854-66.
65. Valenti R et al. Predictors of reocclusion after successful drug-eluting stent-supported percutaneous coronary intervention of chronic total occlusion. *J Am Coll Cardiol.* 2013;61(5):545-50.
66. Vaquerizo B et al. Bioresorbable everolimus-eluting vascular scaffold for the treatment of chronic total occlusions: CTO-ABSORB pilot study. *EuroIntervention.* 2015;11(5):555-63.
67. Goldman S et al. Long-term patency of saphenous vein and left internal mammary artery grafts after coronary artery bypass surgery: results from a Department of Veterans Affairs Cooperative Study. *J Am Coll Cardiol.* 2004;44(11):2149-56.
68. Markovic S et al. Zotarolimus compared with everolimus eluting stents-angiographic and clinical results after recanalization of true coronary chronic total occlusions. *Catheter Cardiovasc Interv.* 2016. [Epub ahead of print].
69. Euro CTO Club. A Randomized Multicentre Trial to Evaluate the Utilization of Revascularization or Optimal Medical Therapy for the Treatment of Chronic Total Coronary Occlusions (EuroCTO). Clinical Trial: NCT01760083. clinicaltrials.gov/ct2/show/NCT01760083.
70. Park SJ; CardioVascular Research Foundation, Korea. Drug-Eluting Stent Implantation Versus Optimal Medical Treatment in Patients With Chronic Total Occlusion (DECISION-CTO). Clinical trial: NCT01078051. clinicaltrials.gov/ct2/show/NCT01078051.
71. Rathore S et al. Procedural and in-hospital outcomes after percutaneous coronary intervention for chronic total occlusions of coronary arteries 2002 to 2008: impact of novel guidewire techniques. *JACC Cardiovasc Interv.* 2009; 2(6):489-97.
72. Morino Y et al. In-hospital outcomes of contemporary percutaneous coronary intervention in patients with chronic total occlusion insights from the J-CTO Registry (Multicenter CTO Registry in Japan). *JACC Cardiovasc Interv.* 2010; 3(2):143-51.
73. Michael TT et al. Procedural outcomes of revascularization of chronic total occlusion of native coronary arteries (from a multicenter United States registry). *Am J Cardiol.* 2013;112(4):488-92.
74. Mehran R et al. A simple risk score for prediction of contrast-induced nephropathy after percutaneous coronary intervention: development and initial validation. *J Am Coll Cardiol.* 2004;44(7):1393-9.
75. Abellas-Sequeiros RA et al. Mehran contrast nephropathy risk score: Is it still useful 10 years later? *J Cardiol.* 2016; 67(3):262-7.
76. Karpaliotis D et al. Development of a high-volume, multiple-operator program for percutaneous chronic total coronary occlusion revascularization: procedural, clinical, and cost-utilization outcomes. *Catheter Cardiovasc Interv.* 2013;82(1):1-8.
77. Fejka M et al. Diagnosis, management, and clinical outcome of cardiac tamponade complicating percutaneous coronary intervention. *Am J Cardiol.* 2002; 90(11):1183-6.
78. Rathore S et al. A comparison of the transradial and the transfemoral approach in chronic total occlusion percutaneous coronary intervention. *Catheter Cardiovasc Interv.* 2009;73(7):883-7.
79. Hannan EL et al. Long-term outcomes of coronary-artery bypass grafting versus stent implantation. *N Engl J Med.* 2005; 352(21):2174-83.
80. Shammam NW et al. The learning curve in treating coronary chronic total occlusion early in the experience of an operator at a tertiary medical center: The role of the hybrid approach. *Cardiovasc Revasc Med.* 2016;17(1):15-8.
81. Vo MN et al. Adoption of the hybrid CTO approach by a single non-CTO operator: procedural and clinical outcomes. *J Invasive Cardiol.* 2015;27(3):139-44.