

A CONFOUNDING CASE: PNEUMOCOCCAL PNEUMONIA UNMASKING SYSTEMIC LUPUS ERYTHEMATOSUS

*Ashok Arbat, Sneha Tirpude, Mitesh K. Dave, Sukhant Bagdia, Sameer Arbat

Department of Pulmonology, KRIMS Hospitals, Nagpur, Maharashtra, India

**Correspondence to ashok_arbat@yahoo.com*

Disclosure: The authors have declared no conflicts of interest.

Received: 21.04.16 **Accepted:** 26.08.16

Citation: EMJ Respir. 2016;4[1]:82-85.

ABSTRACT

We report a case of systemic lupus erythematosus in a 27-year-old female complicated with pneumonia and severe respiratory failure, requiring treatment in an intensive care unit and non-invasive ventilation. Symptoms developed in an otherwise healthy female with no comorbidities except recurrent oral ulcers. Despite evidence of pulmonary infection, response was noted only after early introduction of intensive immunosuppressive treatment. Differential diagnosis and treatment of this condition represent a real challenge but close co-operation between the intensive care unit, pulmonology, and rheumatology departments reduce the risk of a fatal outcome.

Keywords: Systemic lupus erythematosus (SLE), pneumococcal pneumonia, acute lupus pneumonitis (ALP).

INTRODUCTION

Lupus ranges from mild to severe symptoms and many people have long periods with few or no symptoms before a sudden flare-up. In a person who is genetically susceptible to develop systemic lupus erythematosus (SLE), multiple environmental factors such as air pollution, smoking, exposure to toxins and gases, and infections can act as triggers to develop the clinical features of SLE. Tissue chimerism also plays an important role in producing lung disease in SLE.¹ Chimerism refers to cells from one individual in another individual. Kremer Hovinga et al.² performed a postmortem investigation for chimerism in SLE and normal controls. It was found that chimerism occurred more commonly in SLE organs and in those who had an evidence of injury. During pregnancy, fetal cells enter the maternal circulation, making the mother chimeric.

The incidence of SLE is higher amongst non-Caucasians,³ although finding the true prevalence of lung involvement with SLE is complicated by high rates of pulmonary infections. Reported prevalence of pulmonary involvement in SLE varies from 14-100%. Pulmonary manifestations may be

the presenting symptom in 4-5% of patients, and the lungs are involved in almost half of patients during the disease course.⁴ SLE most commonly affects females of childbearing age.⁵ In India, the reported prevalence of SLE ranges from 14-60 people per 100,000.⁶ This case report shows an otherwise asymptomatic female presenting with pulmonary infection but eventually diagnosed with SLE.

CASE REPORT

A 27-year-old female had complaints of fever for 3 months and cough with mucoid expectoration for 1.5 months. She was privately hospitalised for 7 days but did not respond to the empirical treatment. After 15 days she followed up with us and, except for fever, her observations were stable. Her chest radiograph showed persistent left lower zone opacity (**Figure 1**). We performed bronchial washings and gave her cefuroxime and awaited her reports.

The next month, her bacterial culture yielded *Streptococcus pneumoniae*, and she was then hospitalised in the intensive care unit, with a temperature of 38.3°C, respiratory rate of 24 breaths

per minute with use of accessory muscles, and oxygen saturation of 84%. She had a rash over her faucial pillars and soft palate, and coarse-end inspiratory crackles in all zones on auscultation. She was treated with injectable vancomycin followed by linezolid, according to the antibiotic sensitivities report, and oxygen supplementation with non-invasive ventilator support was provided. She was still febrile and her chest radiograph worsened, now involving bilateral mid and upper zones. She had three absence seizures to which her neurological assessment yielded no abnormality. A complete blood count showed a white blood cell count of 2,500/mm³, lymphocytes of 13% (absolute lymphocyte count 325/mm³), and haemoglobin of 9.4 g/dL. There was proteinuria and serum creatinine of 0.7 mg/dL. The patient did not consent to spirometry with diffusion capacity of lung for carbon monoxide. On computed tomography, the thorax showed bilateral patchy alveolar opacities with ground glass opacification and superimposed tiny nodular opacities. The anti-nuclear antibody test was positive, along with anti-double stranded DNA and perinuclear anti-neutrophil cytoplasmic

antibodies. Complement C3 (36.5 mg/dL) and C4 (<6.3 mg/dL) were low, rheumatoid factor was negative, and a transbronchial lung biopsy on repeat bronchoscopy showed evidence of diffuse alveolar damage (organising phase).

DISCUSSION

The most immediate concern was the progressive worsening of the patient despite several courses of antibiotics, with the backdrop of difficult communication due to language barriers. There was an initial bronchial washings report suggesting infection due to *S. pneumoniae* after which she started on appropriate antibiotics. Despite this, she continued to have fever and radiological progression of her condition. Her oral ulcers, faucial pillar rash, and reports of anaemia, lymphopenia, proteinuria, and diffuse alveolar damage led to serology tests that confirmed the diagnosis of SLE. Pulse steroid, mycophenolate mofetil, and hydroxychloroquine were then started. She showed improvement clinically and radiologically. Her symptoms and chest radiograph after 4 weeks of treatment significantly improved (Figure 2).

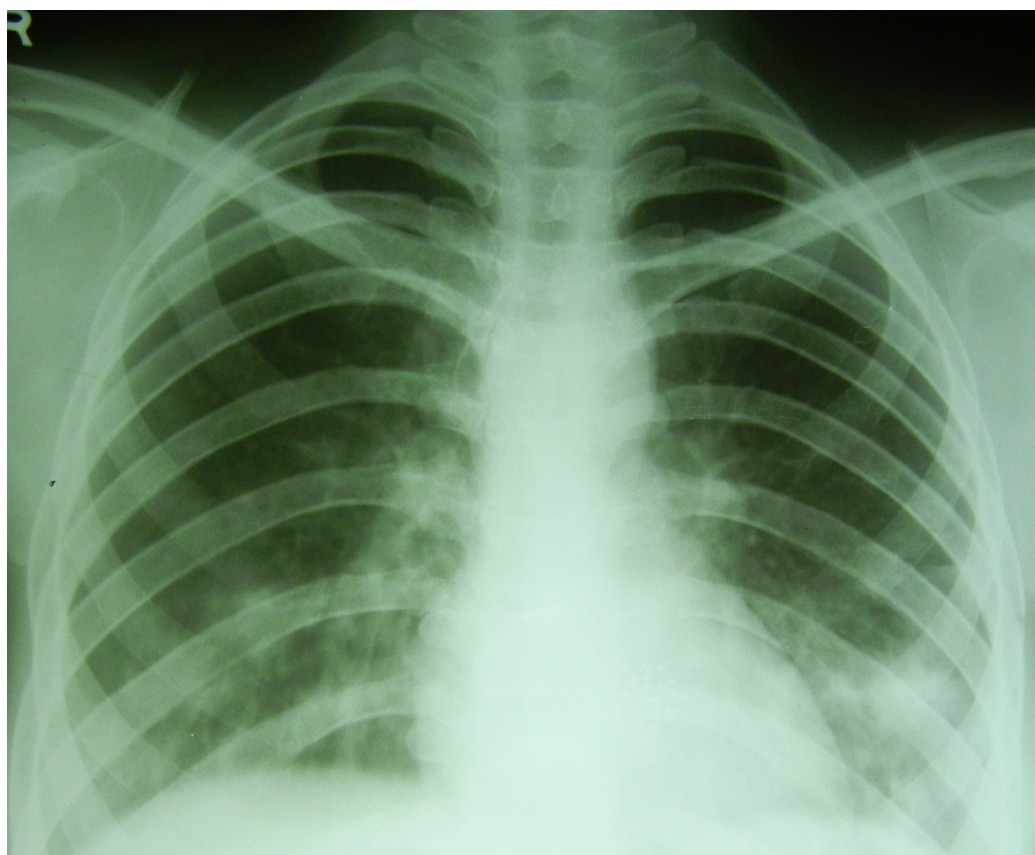


Figure 1: Chest radiograph showing progressive increase in opacities bilaterally in the mid and lower zones.

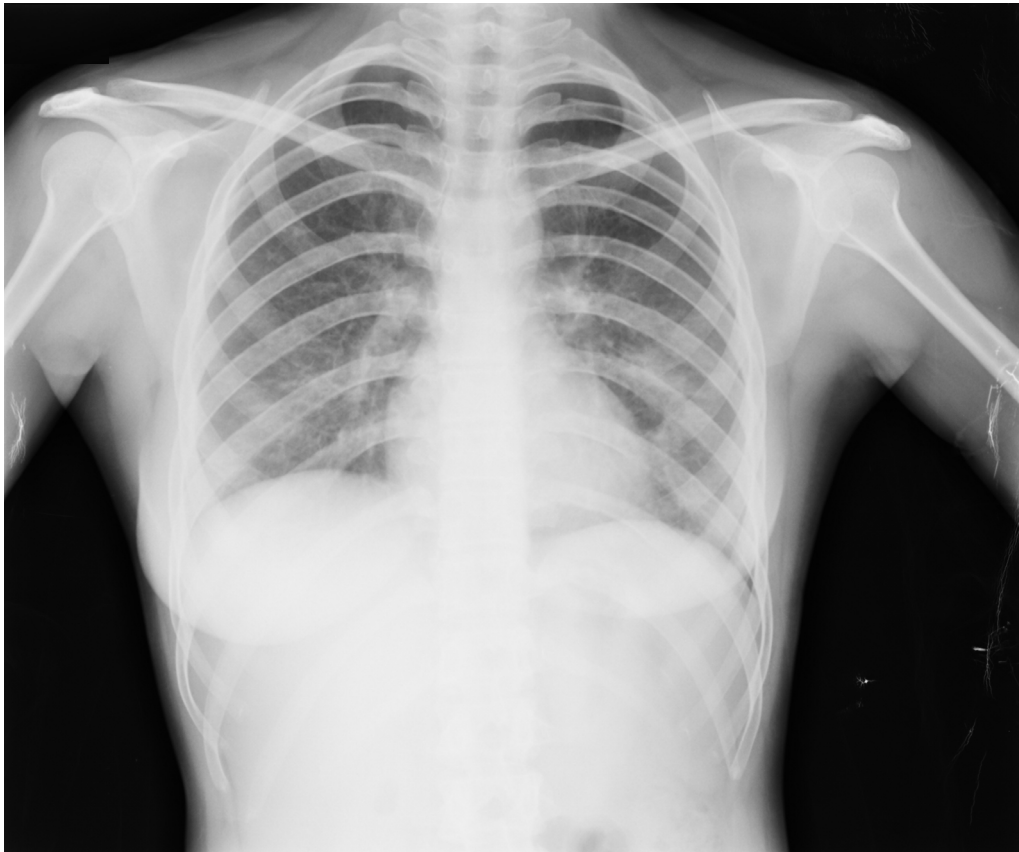


Figure 2: Chest radiograph showing resolution of opacities.

SLE has various pulmonary manifestations ranging from pleurisy, obstructive lung disease, and diaphragmatic dysfunction (shrinking lung syndrome) to acute lupus pneumonitis (ALP), diffuse alveolar haemorrhage (DAH), and chronic interstitial pneumonia. The rate of infection in SLE appears to exceed that of any other autoimmune diseases and immuno-compromised states by as much as 8-fold.⁷ The clinical presentation of ALP is non-specific and is characterised by the sudden onset of fever, cough, and dyspnoea with hypoxaemia and hypocapnia, pleuritic chest pain, and patchy alveolar infiltrates on chest radiograph without clinical and laboratory evidence of an underlying infection.⁸ If the bronchial washings had been negative to culture, this patient would have been a case of ALP versus DAH. ALP can be difficult to differentiate from infectious pneumonia because of similar clinical and radiological presentation. Their differentiation is important for treatment, but in this patient both antibiotics and immuno-suppressive treatment were required. The underlying SLE in the form of ALP became apparent with this infection. We may call this acute lupus 'pneumonia' instead of acute lupus 'pneumonitis'.

Bacterial DNA can promote several of the autoimmune abnormalities observed in SLE through molecular mimicry and has a possible pathogenic role in activating immune cells.⁹⁻¹¹ Bacteria and viruses produce toxins called superantigens that bind to the major histocompatibility complex Class II proteins on antigen-presenting cells and to the specific T cell receptors on activated T cells. The ability to stimulate polyclonal B (immunoglobulin G) as well as T cell responses raises the possibility of a role for superantigens in the induction of autoimmune diseases.¹² In the framework of autoimmune diseases, antibodies developed against bacterial antigens during infection are supposed to recognise self-antigens, inducing formation of immune complexes. The infections are particularly due to encapsulated organisms.¹³ Pulmonary tuberculosis is the most common infection seen in India in patients with SLE. A 2009 study showed that individuals on hydroxychloroquine are 16-times less likely to get a major infection when taking the drug, regardless of whether or not corticosteroids are also taken.¹⁴ Lupus patients' immune systems need to receive bactericidal rather than bacteriostatic drugs;¹⁵ non-live vaccines are useful.¹³

This is a novel case, in which the patient had an ongoing fever for 3 months due to pneumonia that triggered the expression of SLE. We arrived at this conclusion because the increased opacities resolved only after the addition of treatment of ALP.

REFERENCES

1. Kamen DL, Strange C. Pulmonary manifestations of systemic lupus erythematosus. *Clin Chest Med.* 2010;31(3): 479-88.
2. Kremer Hovinga IC et al. Tissue chimerism in systemic lupus erythematosus is related to injury. *Ann Rheum Dis.* 2007;66(12):1568-73.
3. Somers EC et al. Population-based incidence and prevalence of systemic lupus erythematosus: the Michigan Lupus Epidemiology and Surveillance program. *Arthritis Rheumatol.* 2014;66(2):369-78.
4. Vitali C et al. Disease activity in systemic lupus erythematosus: report of the Consensus Study Group of the European Workshop for Rheumatology Research. I. A descriptive analysis of 704 European lupus patients. *European Consensus Study Group for Disease Activity in SLE. Clin Exp Rheumatol.* 1992;10(5):527-39.
5. Weckerle CE, Niewold TB. The unexplained female predominance of systemic lupus erythematosus: Clues from genetic and cytokine studies. *Clin Rev Allergy Immunol.* 2011;40(1):42-9.
6. Malaviya AN et al. Prevalence of systemic lupus erythematosus in India. *Lupus.* 1993;2(2):115-8.
7. Skare TL et al. Infections and systemic lupus erythematosus. *Einstein (São Paulo).* 2016;14(1):47-51.
8. Torre O, Harari S. Pleural and pulmonary involvement in systemic lupus erythematosus. *Presse Med.* 2011;40(1Pt2): e19-29.
9. Tomita H et al. Systemic lupus erythematosus-like autoimmune abnormalities induced by bacterial infection. *Clin Exp Rheumatol.* 2003; 21(4):497-9.
10. Sheybani F et al. Sometimes there is more than one puzzle on the table: Pneumococcal bacteremia as a new systemic lupus erythematosus presentation. *Case Rep Infect Dis.* 2015; 970289.
11. Sánchez B et al. Interaction of Intestinal Microorganisms with the Human Host in the Framework of Autoimmune Diseases. *Front Immunol.* 2015;20(6):594.
12. Acha-Orbea H. Bacterial and viral superantigens: Roles in autoimmunity? *Ann Rheum Dis.* 1993;52(Suppl 1):S6-16.
13. Abu-Shakra M. Safety of vaccination of patients with systemic lupus erythematosus. *Lupus.* 2009;18(13): 1205-8.
14. Medscape Medical News; Barclay L. Hydroxychloroquine use may be safe in systemic lupus erythematosus. 15 June 2009. Available at: <http://www.medscape.com/viewarticle/704385>. Last accessed: 26 August 2016.
15. Lupus Society of Illinois. Managing Infections for Lupus Patients - Highlights from Dr. Curran's Presentation. 411 S. Chicago, Illinois, 9 August 2012. Available at: <http://www.lupusil.org/managing-infections-for-lupus-patients--highlights-from-dr-currans-presentation.html>. Last accessed: 26 August 2016.