

# CURRENT CONCEPTS IN AESTHETIC LASER MEDICINE: THE 694-NM Q-SWITCHED RUBY-LASER

**\*Peter Arne Gerber,<sup>1</sup> Said Hilton<sup>2</sup>**

*1. Department of Dermatology, Medical Faculty, University of Düsseldorf, Düsseldorf, Germany*

*2. Medical Skin Center, Dr. Hilton, Düsseldorf, Germany*

*\*Correspondence to peterarne.gerber@med.uni-duesseldorf.de*

**Disclosure:** PAG has received honoraria for oral presentations by Asclepion Laser Technologies. SH has no potential conflict of interest.

**Received:** 21.04.14 **Accepted:** 16.07.14

**Citation:** EMJ Dermatol. 2014;2:56-60.

---

## ABSTRACT

Quality-switched (q-switched) laser systems are the gold standard for the treatment of benign pigmented lesions and tattoo removal. A frequently used system is the q-switched ruby laser that emits monochromatic light at the wavelength of 694 nm. This system is used for the removal of age spots (senile lentigines), seborrhoeic keratosis, tattoos, and other dyschromatoses. The increasing need for the removal of, for example, age spots and unwanted tattoos, reflects both the wish of our ageing society to preserve a youthful appearance and the steadily growing prevalence of tattoos. This review highlights the potential, limitations, and novel treatment concepts of using q-switched ruby laser systems.

**Keywords:** Quality-switched (q-switched) laser, ruby, pigmented lesions, tattoo, lentigines, R20.

---

## BIOPHYSICAL PRINCIPLES OF DERMATOLOGICAL LASER THERAPY

In 1983 R. Rox Anderson and John A. Parrish<sup>1</sup> published their groundbreaking paper on the biophysical principle of laser therapy. Briefly, this principle of selective photothermolysis states that the efficacy of a medical laser relies on the specific absorption of radiation by distinct target chromophores. For lasers used in the dermatological practice, these chromophores are water (ablative lasers: the 2,940 nm Erb:YAG-laser or the 10,600 nm CO<sub>2</sub>-laser), haemoglobin (treatment of vascular structures: the long-pulsed 532 nm and 1,064 nm Nd:YAG-laser or the 585 nm pulsed dye laser), and melanin (treatment of pigmented structures: quality-switched systems, such as the 694 nm ruby laser, the 532 nm and 1,064 nm Nd:YAG-laser, or the 755 nm alexandrite laser; laser epilation: long-pulsed systems, such as 1,064 nm Nd:YAG-lasers). Non-ablative laser systems emit radiation at wavelengths of approximately 500-1,200 nm, which allows the light deep enough into the skin to reach the target structures. This so-called optical window (~500-1,200 nm) is defined by the

absorption of the epidermis/protein (<500 nm) and water (>1,200 nm).

The selective absorption of the monochromatic light emitted by the respective lasers, in the best case, enables us to generate a confined heating and hence, damage of the target chromophore, with no or minimal damage to the surrounding tissue. To achieve this optimal result, the pulse duration of our laser pulse should match the thermal relaxation time of the target. The thermal relaxation time is defined as the time that an object needs to dissipate 50% of the generated heat and depends on its diameter. Whereas larger structures (such as telangiectasia) are often treated with pulse durations of ≥30 ns, the small pigments require pulse durations of ≤80 ns, which can only be generated by quality-switched (q-switched) lasers. Ideally, these ultra-short, high-energy pulses (100-200 MW) do not only result in confined thermal damage but also generate a so-called photoacoustic effect that disrupts the pigment into micro-fragments and/or releases it from cellular structures. Subsequently, these fragments are discharged via the epidermis or transported to the

draining lymph nodes by tissue macrophages. This process takes approximately 4-6 weeks.

### Laser Therapy of Pigmented Structures

Q-switched laser systems, such as the 694 nm ruby-laser, the 532 nm and 1,064 nm Nd: YAG-laser, or the 755 nm alexandrite laser, are the gold standard for the treatment of benign pigmented lesions and tattoo removal. Indications for the q-switched ruby laser (QSRL) include, but are not restricted to, benign pigmented lesions (e.g. solar lentigo, ephelides, or certain nevi), tattoos (including dirt tattoos and permanent makeup), seborrhoeic keratosis, post-inflammatory hyperpigmentation, melasma, or drug-induced dyschromias. In this review, we will focus on the treatment of more common indications such as solar lentigo ('age spots') and tattoos.

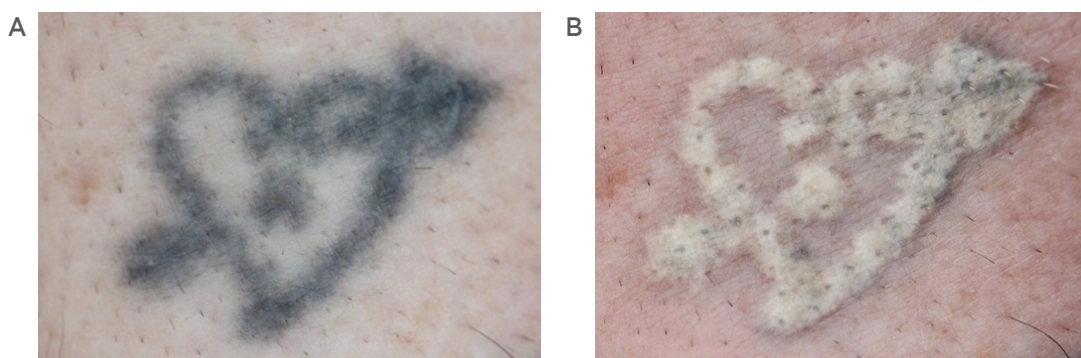
The treatment of pigmented lesions using q-switched laser systems generates extreme energy and heat peaks that vaporise the water of the tissue surrounding the pigments. This vaporisation, and the photodisruption of the pigment, results in a 'snapping' noise and a whitish discolouration of the skin, i.e. the so-called blanching phenomenon (Figure 1). The blanching correlates with the generation of gas bubbles within the dermis and usually vanishes over a time period of 10-20 minutes.

## LASER THERAPY OF TATTOOS

Tattoos have played an important role in various human cultures for thousands of years.<sup>2</sup> An impressive example is the mummy of the iceman

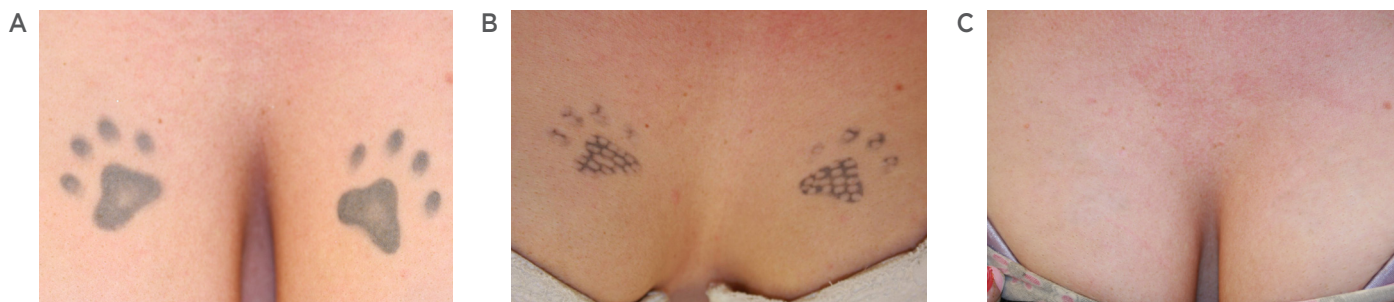'Ötzi', which dates back to >5,000 years, who displayed tattoos on his back and ankles. Today an estimated 25% of US citizens are tattooed and the prevalence is increasing. The word tattoo is derived from the Polynesian word 'Tatau', which means as much as pricking, hitting, or slitting. Accordingly, the process of tattooing includes the introduction of external pigment into the skin by respective techniques. Tattoos can be differentiated into five types: professional, amateur, cosmetic (permanent makeup), traumatic, and medical.<sup>3</sup> The type of tattoo has an immediate influence on the efficacy of the laser tattoo-removal. Additional factors that influence the selection of the ideal type of laser and the efficacy of the treatment include colour, location, age, and skin-type of the patient. Whereas amateur tattoos often can be removed within 3-6 sessions, professional tattoos may require >20 sessions; the 694 nm ruby-laser may effectively remove black, dark blue, or green colours, while red colours can only be removed effectively with 532 nm Nd:YAL lasers. Multi-colour tattoos require the combination of different laser systems.

Potential complications of laser tattoo-removal include, but are not restricted to, hyper or hypopigmentation, scarring, changes in tattoo-colour, or reactivation of allergic reactions. Accordingly, the ideal time for the treatment of sun-exposed areas is the 'winter-season'. Tanned patients or patients that have planned a sunny vacation within the next 4-6 weeks should not be treated. The same accounts for patients that report allergic reactions following the tattoo-process.



**Figure 1: Blanching-phenomenon.**

Heart-shaped tattoo on the forearm A prior to, and B immediately after treatment with a q-switched 649 nm ruby laser (TattooStar Effect, Asclepion Laser Technologies, Jena, Germany; spot: 4 mm Spot, fluence: 2.5 J/cm<sup>2</sup>, passes: 1). The vaporisation of tissue-water results in a whitish discolouration (so-called 'blanching' or 'popcorn' phenomenon). The blanching vanishes over 10-20 minutes.



**Figure 2: Treatment of a professional tattoo using the q-switched ruby laser.**

Paw-shaped tattoos on the mammae A prior to, B after one session, and C after five sessions using a q-switched 649 nm ruby laser (TattooStar Effect, Asclepion Laser Technologies, Jena, Germany; spot: 4 mm Spot, fluence: 2.5 J/cm<sup>2</sup>, passes: 1).

Treating physicians should be extremely cautious of pigmented nevi in the area of the tattoo. These nevi need to be covered or spared from any laser therapy. Notably, Pohl and co-workers<sup>4</sup> have recently reported the first case of a malignant melanoma (MM) that developed on a pre-existing nevus within a tattoo during and between the phases of laser removal. Prior to the first laser treatment the nevus had been noticed within the tattoo but showed no alterations in the dermatoscopic analysis. As the patient refused the surgical removal of the nevus prior to laser therapy, laser therapy was initiated and the clinical course of the nevus was closely monitored under therapy. After a total of 47 sessions using different laser-systems (532 and 1,064 nm Nd:YAG and 755 nm alexandrite laser) the lesion was excised and a MM (Breslow's thickness of 0.45 mm) was diagnosed.

Prior to therapy, standardised photodocumentation is mandatory. Strict ultraviolet protection of the treated area is mandatory throughout the entire therapy and 6 weeks after. In our hands, the first session is restricted to a 'test-treatment' performed on a representative part of the tattoo and using different treatment intensities. This test-treatment helps to determine the ideal therapy parameters (laser-system, fluence) and predict adverse reactions (e.g. scarring) as well as the estimated number of required sessions. It is prudent to perform such test spots, particularly when the ink composition is ambiguous. The blanching-phenomenon indicates that the selected treatment parameters are effective. If purpura is observed, the fluence should not be increased any further. Bleeding demands reduction of treatment

intensity. The result of the test-treatment is evaluated and photodocumented after 2-4 weeks. The patient is questioned about any complications in the course (e.g. blisters, crusts, bleeding). Subsequently, laser-therapy is performed using effective but safe parameters. We strongly recommend starting the therapy using defensive parameters in order to avoid complications in the course. Therapy is performed using superficial analgesia with cooled air (e.g. Cryo 6 Derma, Zimmer MedizinSysteme, Neu-Ulm, Germany).

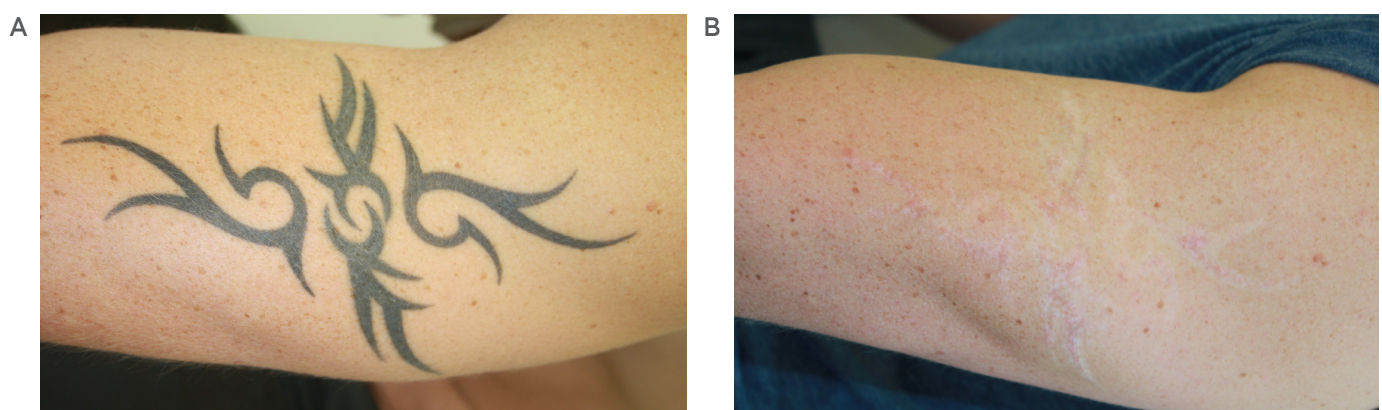
Whereas most patients tolerate the treatment solely with cooled air, topical anaesthetics can be applied prior to therapy in sensitive patients. In some patients pain can be severe and they will not tolerate just cold air and/or a topical anaesthetic; injectable anaesthetics may be required. However, any potent analgesia may increase the risk of adverse effects as the danger signal 'pain' may be turned off. Subsequently, an antiseptic ointment can be applied and cool-packs are used for at least 10 minutes. Topical sun screen (SPF 50+) is advised throughout the entire treatment period. Since the pulses should not overlap during the treatment to avoid bulk-heating and complications, the tattoo will show a 'dotted' appearance in the course of the therapy (Figure 2). Treatments are repeated every 4-6 weeks. An increase of the treatment intervals may result in a reduced number of overall treatments that are needed to completely remove the tattoo. This is due to the fact that the immune system has more time to 'remove' pigment fragments from the tattoo area (please also refer to Biophysical principles). Nevertheless, prolonged treatment-intervals are likely to increase the overall time needed to achieve a complete removal.

The use of the QSRL can achieve excellent cosmetic results (Figure 2); nevertheless, the patient must be educated prior to the therapy that the tattooing-process often results in a permanent alteration of the skin-structure. Hence, removing the colour from the tattooed area may 'uncover' a tattoo-shaped scar (Figure 3). If the patient is not educated about this fact, the individual may associate the scar with the process of an 'incorrect' laser-therapy. Furthermore, in approximately 40% of the cases, QSRL-therapy is associated with transient hypopigmentation (Figure 3).<sup>5</sup> This may be permanent in approximately 10% of the cases.<sup>6</sup> The occurrence of hypopigmentation correlates with the number of treatment-sessions. Another potential complication must be warranted when treating cosmetic tattoos. In fact, laser therapy of red permanent makeup, which is usually applied to accentuate the contour of lips, may result in an oxidation of the pigment and a subsequent black discolouration.<sup>6</sup> Hence, when treating permanent makeup, a test-treatment is mandatory. In most cases, the first treatment will induce the discolouration to black, which is then effectively removed with the QSRL in the course. However, the patient must be educated about the stigmatising appearance until complete pigment removal is achieved.

As mentioned before, the removal of a tattoo often requires multiple treatment sessions, which is associated with a distinct timely and financial burden for the patient. Thus, there is an urgent need for novel techniques that may reduce the

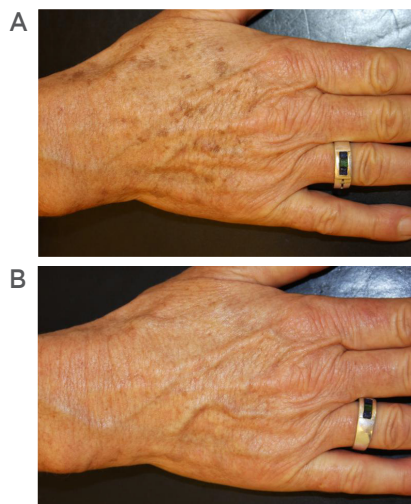
number of treatments needed. In this context, Anderson and Parrish<sup>1</sup> recently published the so-called 'R20' method.<sup>7</sup> The authors propose that the blanching that is observed after the treatment of tattoos using q-switched laser systems (Figure 1) limits the number of effective passes to one, as the forming gas bubbles in the dermis scatter light and prevent the laser from reaching pigments located in the deeper dermis. However, the application of multiple passes after the blanching vanished (approximately 20 minutes, and therefore, 'R20'-technique) in one session resulted in a significant increase of the efficacy of each session. In our hands, this 'R20' technique has proven its benefit, and we were able to reduce the number of sessions by approximately 25% when we performed two passes per session. Whereas Anderson and Parrish<sup>1</sup> reported that they used four passes per session in their study and observed an even better efficacy than we did, we advise to restrict the therapy to two passes per session in order to avoid complications. In fact, we suggest that the 'R20'-technique should only be performed by experienced laser physicians. We have made the observation that it is effective and 'risk-averse' to start the treatment with single passes and to switch to 'R20' once the density of the pigment is reduced in a further course of therapy.

Finally, the latest developments in laser tattoo removal are q-switched laser systems that emit extreme short pulses in the picosecond range and that have been proposed to effectively remove multi-coloured tattoos within one or two sessions.<sup>8,9</sup>



**Figure 3: Treatment of a professional tattoo using the q-switched ruby laser.**

Tribal-shaped tattoos on the forearm A prior to, and B after 15 session using a q-switched 649 nm ruby laser (TattooStar Effect, Asclepion Laser Technologies, Jena, Germany; spot: 4 mm Spot, fluence: 2.5 J/cm<sup>2</sup>, passes: 1). At the end of the therapy (B), a tattoo-shaped, hypopigmentation with an alteration of the skin-structure is visible.



**Figure 4: Treatment of solar lentiginos ('age spots') using the q-switched ruby laser.**

Lentiginos on the hand A prior to, and B 3 weeks after a single treatment using a q-switched 649 nm ruby laser (TattooStar Effect, Asclepion Laser Technologies, Jena, Germany; spot: 4 mm Spot, fluence: 4.0 J/cm<sup>2</sup>, passes: 1).

However, whereas we regard the picosecond technology as a very promising development, in our view, a close look at the images presented in the original publications show some scarring in the follow-ups, and further controlled studies with larger patient collectives are needed to prove the superiority of these systems.

## LASER THERAPY OF BENIGN PIGMENT LESIONS

The QSRL is extremely effective in the treatment of benign pigment lesions. In the most cases solar lentiginos ('age spots') or flat, pigmented seborrhoeic keratosis can be removed within a

single session (Figure 4). Prior to therapy, the diagnosis and dignity of the treated lesions must be determined. As we have mentioned before, Pohl and co-workers<sup>4</sup> have recently reported that the laser treatment of a pigmented nevus resulted in malignant transformation and the development of a MM. Diagnostic procedures include dermatoscopy and or the histopathological analysis of representative superficial (shave) biopsies. In particular when treating facial pigmented lesions, the differential diagnosis includes lentigo or even lentigo maligna melanoma. Therefore, we advise to perform histopathological analysis of shave biopsies prior to any laser-treatments of facial pigmented lesions, if possible, or at least if there are any signs of atypia. Facial pigmented lesions that reoccur after laser-therapy should undergo immediate histopathological evaluation.

In accordance with the treatment of tattoos, test-treatment should be performed when treating large lesions. Tanned patients should not be treated, and sun-exposed areas should not be treated in the 'summer season'. During this time of the year, patients can be advised to apply depigmenting ointments and sunscreen. Topical sunscreen (SPF 50+) is also mandatory for at least 6 weeks post-treatment.

## SUMMARY

Today, q-switched laser systems are the gold standard for the removal of tattoos and the treatment of benign pigmented lesions. In our hands, the QSRL has proven itself as a reliable and effective system for the management of a broad variety of indications. Novel techniques and laser-systems grant interesting and novel treatment options for new and experienced users.

## REFERENCES

1. Anderson RR, Parrish JA. Selective photothermolysis: precise microsurgery by selective absorption of pulsed radiation. *Science*. 1983;220(4596):524-7.
2. Kent KM, Graber EM. Laser tattoo removal: a review. *Dermatol Surg*. 2012;38(1):1-13.
3. Kuperman-Beade M et al. Laser removal of tattoos. *Am J Clin Dermatol*. 2001;2(1):21-5.
4. Pohl L et al. Pitfalls and recommendations in cases of laser removal of decorative tattoos with pigmented lesions: case report and review of the literature. *JAMA Dermatol*. 2013;149(9):1087-9.
5. Leuenberger ML et al. Comparison of the Q-switched alexandrite, Nd:YAG, and ruby lasers in treating blue-black tattoos. *Dermatol Surg*. 1999;25(1):10-4.
6. Raulin C, Karsai S (eds.), *Lasertherapie der Haut* (2013), Springer-Verlag Berlin Heidelberg.
7. Kossida T et al. Optimal tattoo removal in a single laser session based on the method of repeated exposures. *J Am Acad Dermatol*. 2012;66(2):271-7.
8. Brauer JA et al. Successful and rapid treatment of blue and green tattoo pigment with a novel picosecond laser. *Arch Dermatol*. 2012;148(7):820-3.
9. Saedi N et al. Treatment of tattoos with a picosecond alexandrite laser: a prospective trial. *Arch Dermatol*. 2012;148(12):1360-3.