

# CURRENT STATUS AND FUTURE PERSPECTIVES ON DRUG-ELUTING BIORESORBABLE CORONARY SCAFFOLDS: WILL THE PARADIGM OF PCI SHIFT?

**\*Alfonso Ielasi, Maurizio Tespili**

*Division of Cardiology, Bolognini Hospital, Seriate (BG), Italy*

*\*Correspondence to alielasi@hotmail.com*

**Disclosure:** No potential conflict of interest.

**Received:** 16.01.14 **Accepted:** 28.02.14

**Citation:** EMJ Int Cardiol. 2014;1:81-90.

---

## ABSTRACT

Despite improvements in stent platform, polymer, and drug elution, the permanent metallic stents have significant limitations as they distort vessel physiology, predispose to late thrombosis, and may preclude surgical revascularisation. Bioresorbable scaffold (BRS) technology has evolved over the last few years to overcome these drawbacks. Actually, different BRS are either available or under clinical and preclinical investigation. However, the use of BRS has largely been restricted to patients recruited into clinical trials with a relatively small number of 'real-world' patients treated with these devices. Here, we highlight the potentialities of these devices, describe the evidence from the recent clinical trials, and discuss the potential advantages as well as challenges that this novel technology may face in routine clinical practice.

Keywords: Bioresorbable scaffolds, drug-eluting stents, coronary angioplasty.

---

## INTRODUCTION

The landscape of percutaneous coronary intervention (PCI) has evolved dramatically over the last 35 years. At the beginning, plain old balloon angioplasty (POBA) revolutionised the treatment of coronary artery disease (CAD). However, the outcomes following POBA were compromised by re-narrowing due to elastic recoil, abrupt coronary occlusion secondary to severe dissection, and neointimal hyperplasia.<sup>1-3</sup> Metallic stents were developed to overcome these issues and the two landmark trials, BENESTENT and STRESS, demonstrated the superiority of the bare-metal stents (BMS) over POBA and established BMS as second revolution in coronary intervention.<sup>4,5</sup> However, the medium and long-term results after BMS implantation showed a high incidence of in-stent restenosis.<sup>6</sup> The introduction of drug-eluting stents (DES) that were developed by coating BMS with anti-proliferative drugs (i.e. sirolimus or paclitaxel) significantly reduced in-stent restenosis and target lesion revascularisation (TLR) rates compared to BMS.<sup>7,8</sup> DES, considered the third

revolution in interventional cardiology, broadened the applications of PCI, particularly in complex subsets of lesions and high-risk patients.<sup>9,10</sup>

However, first-generation DES were associated with an increased risk of stent thrombosis (ST),<sup>11,12</sup> but newer-generation DES, with thinner struts and biocompatible or biodegradable polymers, have a considerably improved safety profile.<sup>13-15</sup> Although DES technology seems to cover the needs of the interventional cardiologists, it cannot be considered the optimal solution as it leaves a permanent cage inside the vessel that could be associated with potential future problems.

The presence of a foreign body within the artery wall can be a source of chronic vessel wall inflammation and may interfere with the endothelial function, thus delaying the vessel wall healing that is associated with a higher risk of ST.<sup>16-18</sup> In addition, it has been demonstrated that stent implantation has an unfavourable effect on the geometry of curved arteries, increasing the risk for neointima hyperplasia.<sup>19</sup> Furthermore, the increased

rigidity of the stent may alter the pulsatile profile of the blood flow, affecting the shear stress within the stent.<sup>20</sup> Another important drawback of the metallic stents is the risk to preclude surgical revascularisation when implanted in a potential “anastomotic” segment of the coronary tree. Thus, the ideal solution would be a transient bioresorbable scaffold (BRS) that would initially maintain the vessel open and then it would disappear, allowing the vessel to return to its natural state whilst maintaining access for future surgical revascularisation, if required. The absence of a rigid permanent cage may result in restoration of endothelial function and shear stress, reducing the risk of late events and favouring positive remodelling of the vessel. These benefits may also result in reduced need for long-term dual anti-platelet therapy (DAT). Furthermore, BRS are an ideal device for allowing an eventual future non-invasive functional/morphological assessment (i.e. by the computed tomographic coronary angiography associated with myocardial perfusion scan or the non-invasive fractional flow-reserve) of the treated vessel as, in contrast to the traditional stents, they do not produce artifacts.<sup>21</sup>

Today, several BRS are available but only two devices have acquired Conformité Européenne (CE) mark approval and only one is currently used in clinical practice. Here, we provide a brief overview of the available (under development, under preclinical validation, or undergoing clinical trials) drug-eluting BRS and discuss the potential additional advantages and limitations that these devices may have in everyday clinical practice.

## DRUG-ELUTING BRS

### ABSORB Bioresorbable Vascular Scaffold (BVS)

The ABSORB<sup>®</sup> BVS (Abbott Vascular, Santa Clara, CA, USA) is comprised of semicrystalline poly L-lactic acid (PLLA) coated with amorphous poly-D,L-lactide (PDLA) polymer-eluting everolimus. Degradation of the bioresorbable components (PLLA and PDLA) of the scaffold is mainly through hydrolysis, followed by macrophage phagocytosis of the resulting degradation products, a process that is completed within 3 years.<sup>22</sup> Two versions of the BVS have been assessed in clinical trials. The safety and feasibility of the BVS 1.0 was tested in the open-label prospective ‘A bioresorbable everolimus eluting coronary stent system for patients with single *de novo* coronary

artery lesions (ABSORB) Cohort A’ trial.<sup>23</sup> At 6 months, the angiographic in-stent late lumen loss (LLL) was 0.44 mm with evidence of scaffold shrinkage (-11.8%) as measured by intravascular ultrasound (IVUS). However, vasomotion appeared to be restored, with induced vasoconstriction and vasodilatation possible in the treated segment.<sup>24</sup> To prolong the mechanical BVS strength and reduce late recoil, a second-generation BVS (1.1) has been introduced. Of note, BVS 1.1 has a smaller maximum circular unsupported surface area,<sup>25</sup> a more uniform strut distribution, and improved stent retention. Importantly, these changes have not resulted in an increased amount of polymeric material or an increase in strut thickness. Proprietary process changes have been implemented to increase radial strength. In addition, these changes have reduced polymer degradation rates at early time points, and thus prolonged mechanical integrity of the scaffold throughout the first few months following implantation.<sup>26</sup>

The efficacy of the BVS 1.1 was assessed in the ABSORB Cohort B trial, which recruited 101 patients with single or two-vessel *de novo* disease all receiving a 3x18 mm BVS. At 6-month follow-up, there was only one TLR, while LLL was 0.19±0.18 mm; at 2-year follow-up, LLL was 0.27±0.20 mm. The scaffold area progressively increased during follow-up, although at 6-months there was significant reduction in minimal lumen area (MLA) on IVUS as compared with baseline (6.60±1.22 to 6.37±1.12 mm<sup>2</sup>, p<0.005).<sup>24</sup> Furthermore, at 2-year angiographic follow-up no differences in LLL (0.29±0.16 versus 0.25±0.22 mm, p=0.439) were noted between small (reference vessel diameter [RVD] <2.5 mm) and large vessels (≥2.5 mm).<sup>27</sup> The recently published 3-year multimodality imaging observations of the ABSORB Cohort B trial showed interesting results. On IVUS, mean lumen and scaffold area remained stable between 2 and 3 years, whereas significant reduction in plaque behind the struts occurred with a trend toward adaptive restrictive remodelling of external elastic membrane. Hyperechogenicity of the vessel wall, a surrogate of the bioresorption process, decreased from 23.1% to 10.4% with a reduction of radiofrequency backscattering for dense calcium and necrotic core. The count of strut cores detected on optical coherence tomography (OCT) increased significantly, likely reflecting the dismantling of the scaffold, while 98% of struts were covered. At 3-year follow-up, there were seven (7%) ischaemia-driven TLR and three (3%) non-ST segment

elevation myocardial infarctions (MI). The major adverse cardiovascular event (MACE) rate was 10.0% without any scaffold thrombosis.<sup>28</sup>

Data regarding the use of ABSORB® in everyday practice are also becoming available. The prospective, single-centre, BVS Expand registry - examining the use of ABSORB® in routine clinical practice, with the exception of patients with ST-elevation MI (STEMI) and restenotic lesions - was associated with one (0.7%) MI and one (0.7%) non-target vessel revascularisation (TVR) at 30-day follow-up in a cohort of 131 patients.<sup>29</sup> Recently, Gori et al.<sup>30</sup> reported the outcome following ABSORB® implantation in 150 patients (194 lesions) with acute coronary syndromes compared with a control group composed of 103 consecutive patients (129 lesions) who underwent everolimus DES implantation in the same time period. In-hospital, 30-day, and 6-month MACE rates were similar between both groups (all  $p > 0.5$ ), while definite or probable in-stent/scaffold thrombosis occurred in two BVS patients (1.3%) and one (0.9%) DES patient during the index admission, and it occurred in another patient in each group in the first month after BVS/DES implantation.

The recently published BVS STEMI first study is a prospective, single-arm, single-centre study, reporting data following BVS implantation in 49 STEMI patients. The procedural success was 97.9%, while no patients had angiographically-visible residual thrombus at the end of the procedure. OCT analysis (performed in 31 patients) showed that mean percentage of malapposed struts per patient was  $2.80 \pm 3.90\%$ . At 30-day follow-up, target-lesion failure (TLF) rate was 0% and no death or scaffold thrombosis were reported.<sup>31</sup> Other interesting results in the STEMI subset come from the Prague-19 multicentre study where 40 patients undergoing primary PCI were evaluated. The 6-month survival free from death, MI or TVR was 95%, while an OCT substudy (performed on 21 patients) demonstrated only a 1.1% rate of scaffold struts malapposition.<sup>32</sup>

More, ongoing studies are currently evaluating the BVS 1.1. The ABSORB Extend study is recruiting 1,000 patients worldwide with *de novo* single or two-vessel disease. It allows the recruitment of patients with diseases in smaller vessels ( $> 2.0$  mm) as well as those with long lesions, thus giving the opportunity to evaluate the BVS performance in both these groups. An interim

report on the 24-month clinical outcomes from the first 250 patients enrolled showed MACE and target vessel failure (TVF) rates of 4.4% and 4.8%, respectively.<sup>33</sup> Recently, the first 450 patients enrolled in this trial have completed a 12-month follow-up, and an interim report presented seven cases (1.5%) of device failure.<sup>34</sup> In particular, scaffold dislodgement occurred in three (0.67%) cases, while subacute or late scaffold thrombosis occurred in four (0.89%) cases.

The prospective, randomised ABSORB II study, on the other hand, will compare BVS 1.1 to the XIENCE® PRIME everolimus-eluting stent (Abbott Vascular) in patients with stable angina and single or two-vessel disease. The trial is expected to be completed in 2015. The multicentre randomised ABSORB III trial will aim to recruit over 2,000 patients with up to two *de novo* lesions in different epicardial vessels (vessel diameter 2.5-3.75 mm, length  $\leq 24$  mm) and randomise these to BVS 1.1 or XIENCE® PRIME. Finally, the ABSORB IV study will aim to add another 4,000 patients to ABSORB III in order to assess for BVS 1.1 superiority over XIENCE® PRIME with regards to TLF between 1 and 5 years.

The Amsterdam Investigator-initiated Absorb strategy All-comers trial (AIDA trial) is a prospective, randomised (1:1), active-control, single-blinded, all-comer, non-inferiority study. About 2,690 all-comer subjects will be enrolled in order to evaluate the efficacy and performance of the ABSORB® BVS versus the Xience® family in the treatment of coronary lesions. The study population includes both simple and complex lesions, in patients with stable and acute coronary syndromes. The follow-up continues for 5 years and the primary end point of the trial is TVF, defined as the composite of cardiac death, MI, and TVR at 2-year follow-up.<sup>35</sup>

### DESolve® BRS

The DESolve® BRS (Elixir Medical, Sunnyvale, CA, USA) is made from a PLLA-based polymer eluting novolimus, a major metabolite of sirolimus. The DESolve® is designed to be fully resorbed within 2 years. In the first-in-man (FIM) study, 15 patients with lesion length  $< 10$  mm and RVD 2.75-3.00 mm underwent DESolve® implantation with 14 patients completing 6-month follow-up angiography. Quantitative coronary angiography (QCA) analysis at 6-months showed reasonable in-scaffold LLL ( $0.19 \pm 0.19$  mm) with OCT showing

low neointimal hyperplasia. At 1-year follow-up, one cardiac death, one target vessel MI, and one TLR occurred with no scaffold thrombosis. Multi-slice computed tomography (CT) at 12-months showed continued neointimal suppression and vessel patency.<sup>36</sup> The subsequent multicentre, prospective DESolve<sup>®</sup> Nx trial enrolled 126 patients worldwide. The principal imaging end point was in-scaffold LLL as assessed by QCA at 6-months. The main inclusion angiographic criteria were RVD 2.75–3.5 mm and lesion length  $\leq$ 14 mm. At 6-month follow-up, MACE rate was 3.3%, with two cases of TLR and no cases of scaffold thrombosis. DESolve<sup>®</sup> BRS has recently achieved a CE mark.

### Bioresorbable Magnesium BRS

Magnesium is the lightest structural metal. The strength-to-weight ratio of precipitation-hardened magnesium alloys is comparable with that of strong aluminium alloys and alloy steels.<sup>37</sup> Consequently, a magnesium BRS has the potential to provide a high radial strength for dilating atherosclerotic narrowing and, hence, higher acute gain of coronary lumen. Another virtue of magnesium as an endoprosthesis is its electrochemical properties. Magnesium is more electronegative than other metals used for implants and has shown anti-thrombogenic properties *in vivo*.<sup>38–40</sup> The bioresorbable magnesium scaffold is manufactured by BIOTRONIK (Berlin, Germany). The scaffold is balloon expandable, composed by magnesium (Mg) alloy, and has two radiopaque markers (proximal and distal end of the balloon) to facilitate positioning.

The first generation absorbable metallic stent (AMS I) was associated with a 40% TLR rate within the first 4 months and with an angiographically reported LLL ( $1.08 \pm 0.49$  mm) unacceptably high.<sup>41,42</sup> IVUS demonstrated that most of the AMS-I has been resorbed within 4 months, thus, the increased event rate and recoil were attributed to inappropriate support due to the fast resorption of the AMS. Second-generation devices, AMS-II and AMS-III, have since been designed with different Mg alloys and slower degradation times. The AMS-III DREAMS (DRug Eluting AMS) possessed a biodegradable matrix that eluted paclitaxel. The FIM, BIOSOLVE-I, enrolled 46 patients with *de novo* lesions  $\leq$ 12 mm and RVD 3.0–3.5 mm. At 12-month follow-up, TLF was 7.0% and TLR rate was 4.7%; LLL was  $0.52 \pm 0.39$  mm. Vasomotion was shown to be restored by 6 months with no changes at 1 year. The 2-year clinical outcomes

presented at EuroPCR 2013 showed that TLF and TLR remained stable between 12 and 24 months and no cardiac death or scaffold thrombosis were observed.<sup>43</sup> DREAMS has since been modified to DREAMS-II, which possesses tantalum radiopaque end-markers and elutes sirolimus instead of paclitaxel. The FIM study to assess DREAMS-II, BIOSOLVE-II, is currently recruiting patients to get the data needed to apply for CE mark.

### IDEAL<sup>™</sup> BRS

The IDEAL<sup>™</sup> BRS (Xenogenics Corporation, Canton, MA, USA) is the only scaffold incorporating salicylate directly into the polymer chain. As the polymer degrades, salicylate and sirolimus are released, thereby reducing inflammation and platelet aggregation. The first-generation IDEAL<sup>™</sup> BRS device required an 8-Fr guide catheter. It was associated with a larger-than-expected reduction in lumen area, likely due to insufficient neointimal suppression.<sup>44</sup> This was attributed to inadequate drug dosing and rapid drug release. The second-generation IDEAL<sup>™</sup> BRS addressed these issues by incorporating a higher drug dose, a slower release pattern, and a 6-Fr compatible delivery system. The device is currently undergoing preclinical evaluation.<sup>45</sup>

### ReZolve BRS

The ReZolve<sup>®</sup> BRS (REVA<sup>®</sup> Medical Inc., San Diego, CA, USA) consists of a tyrosine-based polymer, resorption of which takes 18–24 months to complete. The first-generation of this device was associated with a high rate of 1-year adverse clinical outcomes (66.6% TLR and 11.1% MI) that led to the redesign of the scaffold.<sup>46</sup> The current ReZolve<sup>®</sup> consists of a more resilient polymer that incorporates sirolimus. It also has a unique slide and spiral lock mechanism, which reduces acute recoil and provides better radial support. The ReZolve<sup>®</sup> BRS is undergoing clinical evaluation in the ReZolve<sup>®</sup> Sirolimus-Eluting Bioresorbable Coronary Scaffold (RESTORE) trial, which aims to recruit 50 patients with *de novo* CAD. A further CE Mark multicentre study with ReZolve<sup>®</sup>2 (a sheathless, lower profile device that can be delivered through a 6 Fr sheath), the RESTORE-II (Safety and Performance of the ReZolve<sup>®</sup>2 Sirolimus-Eluting Bioresorbable Coronary Scaffold) has recently completed the enrolment. The immediate and mid-term follow-up results of the patients enrolled in the trial will be presented in May at EuroPCR 2014.

## Drug-Eluting BRS Under Preclinical Investigation

The ON-AVS (OrbusNeich Medical, Fort Lauderdale, FL, USA) differs from other drug-eluting BRS as it incorporates CD34+ antibodies for endothelial progenitor cell capture.<sup>47</sup> This aims to promote and achieve faster endothelialisation. The drug eluted is sirolimus. The Xinsorb BRS™ (Huaan Biotechnology Group, Laiwu, China) is made of PLLA and elutes sirolimus. Other BRS under development include: the Sahajanand BRS (Sahajanand Medical Technologies, Pvt, Ltd, India), the Avatar BRS (S3V; Vascular Technologies Pvt. Ltd., Bangalore, Karnataka, India), the FADES BRS (Zorion Medical Inc., USA), Stanza BRS (480 Biomedical, MA, USA), Arterius BRS (Arterius Ltd, Bradford, UK), and the MeRes BRS (Meril Life Science, Vapi, Gujarat, India).<sup>48</sup> Main characteristics of the most recent drug-eluting BRS under preclinical and clinical evaluation are summarised in [Table 1](#).

## From Clinical Trials to Clinical Practice

BRS may theoretically improve clinical outcomes in patients requiring revascularisation since the absence of a permanent metallic cage in the vessel wall may reduce chronic injury, predisposing to restenosis and ST. Currently available data have shown the complete biodegradation of the device at follow-up,<sup>49,50</sup> vessel remodelling with lumen gain over time,<sup>49</sup> and signs of physiological vasomotion of the 'scaffolded' coronary segment.<sup>24,50</sup> Furthermore, promising results have been shown in patients with simple lesions at different follow-up periods up to 5 years ([Table 2](#)).<sup>36,49-51</sup>

To date, the ABSORB is the only scaffold commercially available and the only one that has been used in everyday clinical practice. However, the experience with ABSORB was initially limited to younger patients with AHA/ACC Type A or B lesions in moderate-sized vessels.<sup>52</sup> Thus, there have been very limited data about the ABSORB

**Table 1: Main characteristics of the most recent drug-eluting bioresorbable coronary scaffolds under preclinical and clinical evaluation.**

Scaffold	Strut Material	Drug-Eluted	Strut Thickness (µm)	Radial Support Duration	Bioresorption Period (months)	Status
ABSORB® 1.1 (Abbott Vascular)	Poly-L-Lactide	Everolimus	150	3 months	24-48	CE mark approval acquired
AMS®-3 DREAMS (Biotronik SE)	Magnesium alloy	Paclitaxel	120	3-6 months	9	Under clinical evaluation
DREAMS® 2 (Biotronik SE)	Magnesium alloy	Sirolimus	120	3-6 months	9	Under development
DESolve® (Elixir)	Poly-L-Lactide	Novolimus	150	3-6 months	12-24	CE mark approval acquired
REVA® ReZolve (REVA medical)	Tyrosine-derived polycarbonate	Sirolimus	122	4-6 months	4-6	On clinical studies
IDEAL® Generation II (Xenogenics)	Polyanhydride ester with salicylate	Sirolimus, Salicylate	175	3 months	6-9	On clinical trials
Xinsorb™ (Huaan Biotech)	Poly-L-Lactid Acid	Sirolimus	160	-	-	On preclinical studies
ON-AVS (Orbus Neich)	3 x Lactide polymers	Sirolimus/CD34+	150	6 months	>6	On preclinical studies

*AMS: absorbable metallic stent; CE: Conformité Européenne.*

**Table 2: Main bioresorbable vascular scaffold clinical trials.**

Scaffold	Clinical Study	Number of Patients	End Point	Late Loss (mm)	TLR (%)	MACE (%)
ABSORB® 1.0	ABSORB Cohort A	30	Procedural success, 5-year MACE	0.44 at 6 months	0 at 5 years	3.4 at 5 years
ABSORB® 1.1	ABSORB Cohort B	101	LLL, TLR, and MACE at 6 months, 1, 2, and 3 years	0.27 at 12 months	3.6% at 12 months	10% at 3 years
AMS®-3 DREAMS	BIOSOLVE-I	46	TLF at 6 and 12 months	0.64 at 6 months 0.52 at 12 months	4.3% at 6 months 6.5% at 12 months	4.3% at 6 months 6.5% at 12 months
DESolve®	DESolve 1	15	LLL at 6 months	0.19 at 6 months	6.7% at 12 months	20% at 12 months
	DESolve Nx	120	Procedural success, LLL at 6 months, and 5-year MACE	0.21 at 6 months	1.6% at 6 months	3.25% at 6 months
REVA®	RESORB	27	MACE	1.81 at 6 months	66.7% at 6 months	-
REVA® ReZolve	RESTORE	50	TLR at 6 months, LLL at 12 months	0.20 at 12 months	2 of 12 at 6 months	2 of 12 at 6 months

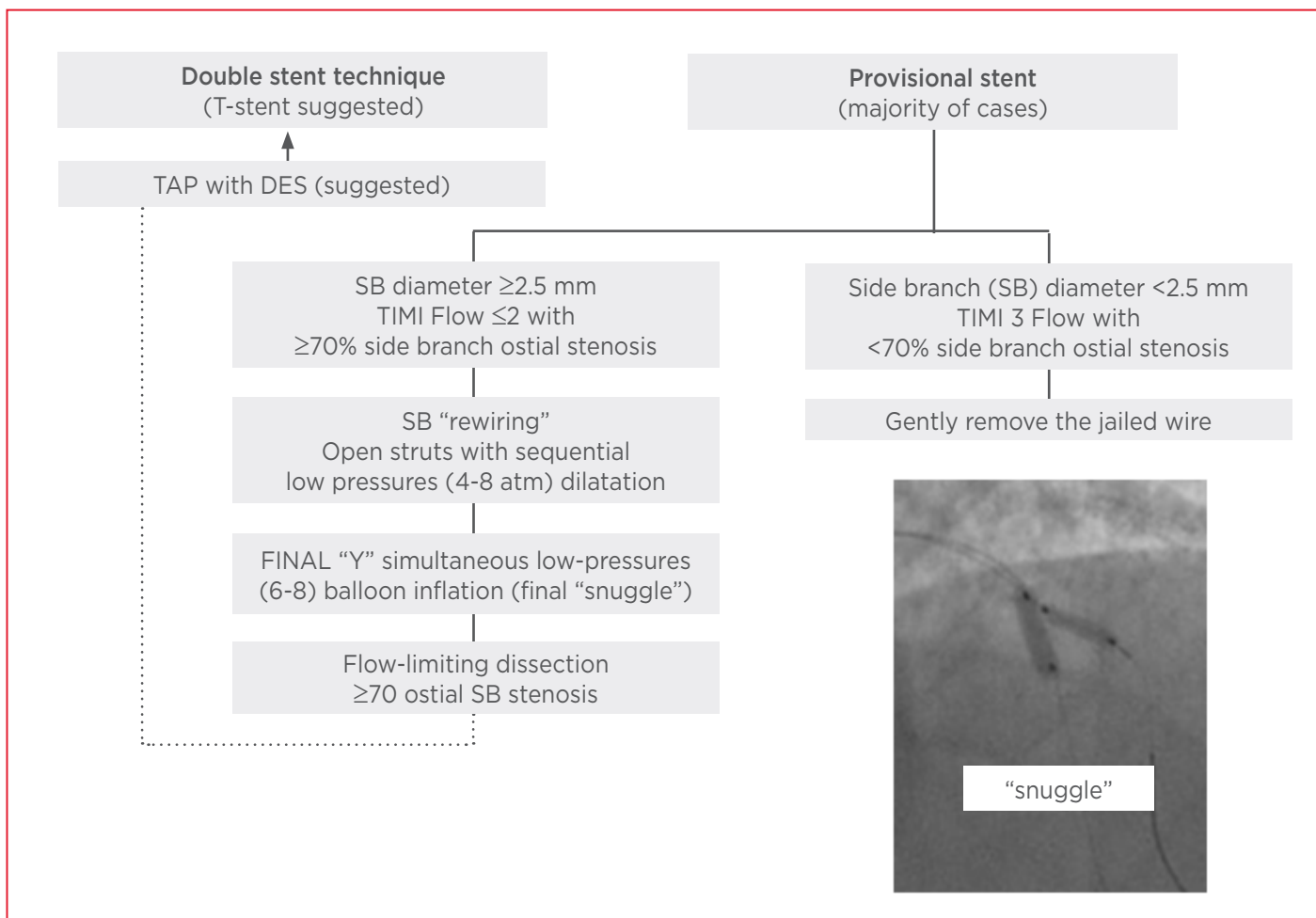
*LLL: late lumen loss; MACE: major adverse cardiac events; TLR: target lesion revascularisation; TLF: target lesion failure.*

performance in complex lesions such as bifurcations, chronic total occlusions, calcified lesions, diffuse disease-requiring overlapping scaffolds, and restenosis, as well as in complex patients such as diabetics with or without multi-vessel disease.

Preliminary real-world data on the outcome following BVS implantation in coronary bifurcation lesions were presented at the Transcatheter Cardiovascular Therapeutics Congress 2013. Most of the lesions were true bifurcations while provisional approach was the default strategy (80-85% of the cases). Angiographic success was obtained in 98-99% of cases, TLR was about 3%, and no scaffold thrombosis was reported up to 6-months follow-up. Aggressive, intravascular-imaging (OCT or IVUS) guided post-dilatation ( $\geq 20$  atm) was performed in all the BVS implanted in the main branch (MB), while final simultaneous balloon inflation was performed, only if required for clinical reasons, at low pressure with minimal

protrusion of the side branch (SB) balloon (final 'snuggle'). No scaffold disruption was reported after simultaneous balloon inflation. The T and minimal protrusion (TAP) technique was the strategy for SB stenting as crossover from provisional, and it was usually performed with a conventional DES since a BVS may not pass through the MB struts. T-stenting was the preferred technique for elective double-stenting with BVS in order to avoid overlapping scaffolds (Figure 1).<sup>53</sup> Although complex double-stenting bifurcation techniques using the BVS platform in both MB and SB appear feasible, their use should be carefully evaluated and eventually limited to patients with large-calibre main vessels.<sup>54,55</sup>

The feasibility of BVS implantation in the setting of long, fibro-calcific lesions is limited to case reports.<sup>56,57</sup> Considering the relatively high BVS profile and the lower radial strength compared to a conventional DES, some points (i.e. an appropriate lesion evaluation with intravascular imaging, a



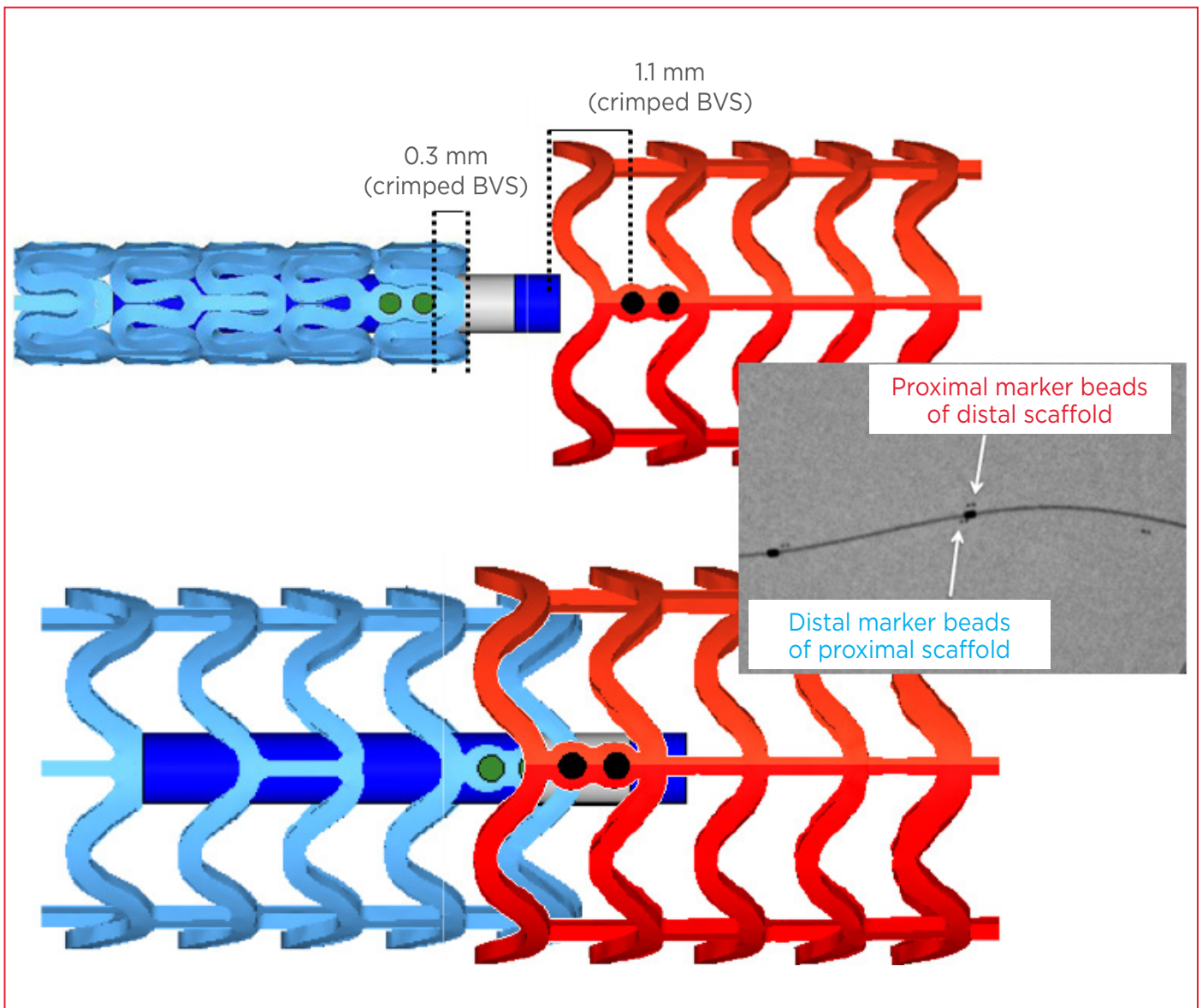
**Figure 1:** Algorithm for bifurcation lesion treatment with ABSORB.

TAP: T and minimal protrusion; DES: drug-eluting stents; SB: side branch; TIMI: thrombolysis in myocardial infarction.

7F guiding catheter, an extra support guidewire, an aggressive lesion preparation using scoring balloons or rotational atherectomy, or a bail-out enhanced back-up support using guide catheter extension systems) appear essential in order to successfully deploy and expand BVS in this complex subset of lesions. However, it is important to highlight that the friction that could be encountered between the thick (156  $\mu\text{m}$ ) polymeric BVS and a tortuous/calcified vessel or a daughter catheter (i.e. Guideliner) may result in BVS dislodgement when forcefully pushing the scaffold.<sup>34</sup>

Early, preliminary 'real-world' experience with ABSORB<sup>34,58</sup> may allow us to draw suggestions on which patients/lesions are best suited for these devices. Aside from simple lesions, patients with long diffuse left anterior descending disease and those requiring multi-vessel revascularisation are interesting candidates for ABSORB, as the eventual

resorption of the BVS reduces stent length as well as sparing from a 'full metal jacket', both of which can predispose to ST and restenosis (Figure 2).<sup>59</sup> This is particularly important for younger patients since such an approach does not only maintain access for future bypass graft surgery if required, but also offers the possibility of further PCI treatment without the additional permanent metallic layers. However, it is important to remember that there are no published data regarding clinical outcomes in complex lesions treated with BVS.<sup>58</sup> The importance of intravascular imaging, pre and post-dilatation, in optimising scaffold implantation and expansion should not be underestimated, particularly in the case of complex lesions (i.e. bifurcations, long lesions, calcified plaques) where the scaffold under-expansion may be associated with sub-acute or late thrombotic events. However, the importance of meticulous procedural technique cannot be overemphasised;



**Figure 2:** Consideration for overlapped ABSORB implantation.

To avoid ‘geographical miss’, without overlap or too much overlap, the following strategy is suggested: 1) advance the second scaffold system until the distal balloon marker lines up with the proximal marker beads of the implanted scaffold; 2) the markers of the second scaffold will be adjacent to the markers of the deployed scaffold (scaffold marker to scaffold marker); 3) the result will be about 1 mm of BVS overlap. BVS: bioresorbable vascular scaffold.

it should take longer to implant a BVS as compared to a conventional DES.

## CONCLUSION

BRS have been heralded as the fourth revolution in interventional cardiology. This novel technology not only provides transient scaffolding and restores flow in the diseased segment but also restores vascular integrity and function. Over recent years, huge improvements have been made in the field of BRS, with encouraging data emerging from their

use in clinical practice. The current results have provided promise for the future, although data regarding their use in complex lesions and long-term clinical outcomes in the ‘real world’ are lacking. The message that arises from their first applications is that BRS should not be considered as another type of stent but as a totally different device that has special strengths, weaknesses, and limitations, and also one that introduces a novel therapeutic potential. This field is an exciting area where further improvements will advance PCI practice.



## REFERENCES

1. Grüntzig AR et al. Nonoperative dilatation of coronary-artery stenosis: percutaneous transluminal coronary angioplasty. *N Engl J Med.* 1979;301(2): 61-8.
2. Sigwart U et al. Emergency stenting for acute occlusion after coronary balloon angioplasty. *Circulation.* 1988;78(5 Pt 1):1121-7.
3. Roubin GS et al. Influence of balloon size on initial success, acute complications, and restenosis after percutaneous transluminal coronary angioplasty. A prospective randomized study. *Circulation.* 1988;78(3):557-65.
4. Serruys PW et al. A comparison of balloon-expandable-stent implantation with balloon angioplasty in patients with coronary artery disease. Benestent Study Group. *N Engl J Med.* 1994;331(8):489-95.
5. Fischman DL et al. A randomized comparison of coronary-stent placement and balloon angioplasty in the treatment of coronary artery disease. Stent Restenosis Study Investigators. *N Engl J Med.* 1994;331(8):496-501.
6. Al Suwaidi J et al. Coronary artery stents. *JAMA.* 2000;284(14):1828-36.
7. Morice MC et al. A randomized comparison of a sirolimus-eluting stent with a standard stent for coronary revascularization. *N Engl J Med.* 2002;346(23):1773-80.
8. Stone GW et al. A polymer-based, paclitaxel-eluting stent in patients with coronary artery disease. *N Engl J Med.* 2004;350(3):221-31.
9. Stone GW et al. Comparison of a polymer-based paclitaxel-eluting stent with a bare metal stent in patients with complex coronary artery disease: a randomized controlled trial. *JAMA.* 2005;294(10):1215-23.
10. Sabaté M et al. Randomized comparison of sirolimus-eluting stent versus standard stent for percutaneous coronary revascularization in diabetic patients: the diabetes and sirolimus-eluting stent (DIABETES) trial. *Circulation.* 2005;112(14):2175-83.
11. McFadden EP et al. Late thrombosis in drug-eluting coronary stents after discontinuation of antiplatelet therapy. *Lancet.* 2004;364(9444):1519-21.
12. Lagerqvist B et al. Long-term outcomes with drug-eluting stents versus bare-metal stents in Sweden. *N Engl J Med.* 2007;356(10):1009-19.
13. Stone GW et al. Everolimus-eluting versus paclitaxel-eluting stents in coronary artery disease. *N Engl J Med.* 2010;362(18):1663-74.
14. Stefanini GG et al. Long-term clinical outcomes of biodegradable polymer biolimus-eluting stents versus durable polymer sirolimus-eluting stents in patients with coronary artery disease (LEADERS): 4 year follow-up of a randomised non-inferiority trial. *Lancet.* 2011;378(9807):1940-8.
15. Iqbal J et al. Incidence and predictors of stent thrombosis: a single-centre study of 5,833 consecutive patients undergoing coronary artery stenting. *EuroIntervention.* 2013;9(1):62-9.
16. König A et al. Influence of stent design and deployment technique on neointima formation and vascular remodeling. *Z Kardiol.* 2002;91 Suppl 3:98-102.
17. Joner M et al. Pathology of drug-eluting stents in humans: delayed healing and late thrombotic risk. *J Am Coll Cardiol.* 2006;48(1):193-202.
18. Guo N et al. Incidence, mechanisms, predictors, and clinical impact of acute and late stent malapposition after primary intervention in patients with acute myocardial infarction. An intravascular ultrasound substudy of the Harmonizing Outcomes with Revascularization and Stents in Acute Myocardial Infarction (HORIZONS-AMI) trial. *Circulation.* 2010;122(11):1077-84.
19. Wentzel JJ et al. Coronary stent implantation changes 3-D vessel geometry and 3-D shear stress distribution. *J Biomech.* 2000;33(10):1287-95.
20. Gijzen FJ et al. Usefulness of shear stress pattern in predicting neointima distribution in sirolimus-eluting stents in coronary arteries. *Am J Cardiol.* 2003;92(11):1325-8.
21. Bourantas CV et al. Bioresorbable scaffolds: current knowledge, potentialities and limitations experienced during their first clinical applications. *Int J Cardiol.* 2013;167(1):11-21.
22. Oberhauser JP et al. Design principles and performance of bioresorbable polymeric vascular scaffolds. *EuroIntervention.* 2009;5 Suppl F:F15-22.
23. Ormiston JA et al. A bioabsorbable everolimus-eluting coronary stent system for patients with single de-novo coronary artery lesions (ABSORB): a prospective open-label trial. *Lancet.* 2008;371(9616):899-907.
24. Serruys PW et al. A bioabsorbable everolimus-eluting coronary stent system (ABSORB): 2-year outcomes and results from multiple imaging methods. *Lancet.* 2009;373(9667):897-910.
25. Okamura T et al. In vivo evaluation of stent strut distribution patterns in the bioabsorbable everolimus-eluting device: an OCT ad hoc analysis of the revision 1.0 and revision 1.1 stent design in the ABSORB clinical trial. *EuroIntervention.* 2010;5(8):932-8.
26. Brugaletta S et al. Comparison between the first and second generation bioresorbable vascular scaffolds: a six month virtual histology study. *EuroIntervention.* 2011;6(9):1110-6.
27. Diletti R et al. Clinical and intravascular imaging outcomes at 1 and 2 years after implantation of absorb everolimus eluting bioresorbable vascular scaffolds in small vessels. Late lumen enlargement: does bioresorption matter with small vessel size? Insight from the ABSORB cohort B trial. *Heart.* 2013;99(2):98-105.
28. Serruys PW et al. Dynamics of vessel wall changes following the implantation of the Absorb everolimus-eluting bioresorbable vascular scaffold: a multi-imaging modality study at 6, 12, 24 and 36 months. *EuroIntervention.* 2013.
29. Van Geuns R. BVS Expand: first result of wide clinical applications of bioresorbable vascular scaffold. Presented at: EuroPCR. Paris, France, 21-24 May 2013.
30. Gori T et al. Early outcome after implantation of absorb bioresorbable drug-eluting scaffolds in patients with acute coronary syndromes. *EuroIntervention.* 2013. [Epub ahead of print].
31. Diletti R et al. Everolimus-eluting bioresorbable vascular scaffolds for treatment of patients presenting with ST-segment elevation myocardial infarction: BVS STEMI first study. *Eur Heart J.* 2014. [Epub ahead of print].
32. Kocka V et al. Bioresorbable vascular scaffolds in acute ST-segment elevation myocardial infarction: a prospective multicentre study 'Prague 19'. *Eur Heart J.* 2014. [Epub ahead of print].
33. Whitbourn R. ABSORB EXTEND: an interim report on the 24-month clinical outcomes from the first 250 patients enrolled. *J Am Coll Cardiol.* 2013;62(18 S1):B11.
34. Ishibashi Y et al. Lessons learned from acute and late scaffold failures in the ABSORB EXTEND trial. *EuroIntervention.* 2014. [Epub ahead of print].
35. Woudstra P et al. Amsterdam Investigator-initiated Absorb strategy all-comers trial (AIDA trial): a clinical evaluation comparing the efficacy and performance of ABSORB everolimus-eluting bioresorbable vascular scaffold strategy vs the XIENCE family (XIENCE PRIME or XIENCE Xpedition) everolimus-eluting coronary stent strategy in the treatment of coronary lesions in

- consecutive all-comers: Rationale and study design. *Am Heart J.* 2014;167(2):133-40.
36. Verheye S et al. A next-generation bioresorbable coronary scaffold system—from bench to first clinical evaluation: six- and 12-month clinical and multimodality imaging results. *JACC Cardiovasc Interv.* 2013;doi:10.1016/j.jcin.2013.07.007. [Epub ahead of print].
37. Campos CM et al. Bioresorbable drug-eluting magnesium-alloy scaffold for treatment of coronary artery disease. *Int J Mol Sci.* 2013;14(12):24492-500.
38. Anstall HB et al. The effect of magnesium on blood coagulation in human subjects. *Lancet.* 1959;1(7077):814-5.
39. Rukshin V et al. Comparative antithrombotic effects of magnesium sulfate and the platelet glycoprotein IIb/IIIa inhibitors tirofiban and eptifibatid in a canine model of stent thrombosis. *Circulation.* 2002;105(16):1970-5.
40. Moravej M, Mantovani D. Biodegradable metals for cardiovascular stent application: interests and new opportunities. *Int J Mol Sci.* 2011;12(7):4250-70.
41. Nishio S et al. Long-Term (>10 Years) clinical outcomes of first-in-human biodegradable poly-L-lactic acid coronary stents: Igaki-Tamai stents. *Circulation.* 2012;125(19):2343-53.
42. Ghimire G et al. Initial evidence for the return of coronary vasoreactivity following the absorption of bioabsorbable magnesium alloy coronary stents. *EuroIntervention.* 2009;4(4):481-4.
43. Haude M. Progress with Drug-eluting Magnesium Resorbable Stents (BIOTRONIK dreams program): DREAMS 2-Year Results. Presented at: Transcatheter Cardiovascular Therapeutics (TCT) Conference. Miami, FL, USA, 22-26 October 2012.
44. Jabara R et al. Novel fully bioabsorbable salicylate-based sirolimus-eluting stent. *EuroIntervention.* 2009;5 Suppl F:F58-64.
45. Jabara R. Bio-mechanical properties and ABC of bioresorption of adipic acid. Presented at: PCR Focus Group on Bioresorbable Vascular Scaffolds. Rotterdam, the Netherlands, 8-9 March 2012.
46. Grube E. Bioabsorbable Stent. The Boston Scientific and REVA Technology. Presented at: EuroPCR. Barcelona, Spain, 19-22 May 2009.
47. Cottone RJ et al. OrbusNeich fully absorbable coronary stent platform incorporating dual partitioned coatings. *EuroIntervention.* 2009;5 Suppl F:F65-71.
48. Costopoulos C et al. Looking into the future with bioresorbable vascular scaffolds. *Expert Rev Cardiovasc Ther.* 2013;11(10):1407-16.
49. Ormiston JA et al. First serial assessment at 6 months and 2 years of the second generation of absorb everolimus-eluting bioresorbable vascular scaffold: a multi-imaging modality study. *Circ Cardiovasc Interv.* 2012;5(5):620-32.
50. Haude M et al. Safety and performance of the drug-eluting absorbable metal scaffold (DREAMS) in patients with de-novo coronary lesions: 12 month results of the prospective, multicentre, first-in-man BIOSOLVE-I trial. *Lancet.* 2013;381(9869):836-44.
51. Onuma Y et al. Five-year clinical and functional multislice computed tomography angiographic results after coronary implantation of the fully resorbable polymeric everolimus-eluting scaffold in patients with de novo coronary artery disease: the ABSORB cohort A trial. *JACC Cardiovasc Interv.* 2013;6(10):999-1009.
52. Liang M et al. Initial experience in the clinical use of everolimus-eluting bioresorbable vascular scaffold (BVS) in a single institution. *Int J Cardiol.* 2013;168(2):1536-7.
53. Naganuma T et al. Bioresorbable Vascular Scaffold Use in Coronary Bifurcation Lesions. Presented at: Transcatheter Cardiovascular Therapeutics. San Francisco, USA. 27 October - 1 November 2013.
54. Costopoulos C et al. Optical coherence tomography of a bifurcation lesion treated with bioresorbable vascular scaffolds with the “mini-crush” technique. *JACC Cardiovasc Interv.* 2013;6(12):1326-7.
55. Dzavik V, Colombo A. The absorb bioresorbable vascular scaffold in coronary bifurcations: insights from bench testing. *JACC Cardiovasc Interv.* 2013;7(1):81-8.
56. Basavarajaiah S et al. Can bioabsorbable scaffolds be used in calcified lesions? *Catheter Cardiovasc Interv.* 2013;doi:10.1002/ccd.24939. [Epub ahead of print].
57. Ielasi A, Anzuini A. Guide-catheter extension system facilitated multiple bioresorbable vascular scaffolds (ABSORB®) delivery in a very long and resistant coronary artery lesion. *Cardiovasc Revasc Med.* 2013;doi:10.1016/j.carrev.2013.08.004. [Epub ahead of print].
58. Latib A et al. Which patients could benefit the most from bioresorbable vascular scaffold implant: from clinical trials to clinical practice. *Minerva Cardioangiol.* 2013;61(3):255-262.
59. Colombo A, Latib A. Can long-term results following balloon angioplasty be the “crystal ball” to predict outcome following bioresorbable vascular scaffolds? *J Am Heart Assoc.* 2012;1(5):e005272.