

HOW BIORESORBABLE VASCULAR SCAFFOLDS CAN BE BENEFICIAL FOR PATIENTS IN THE LONG-TERM

*Antonio Serra,¹ Flavio Ribichini,² Nick West³

1. Interventional Cardiology, Cardiology Department, Hospital de la Santa Creu i Sant Pau, Barcelona, Spain

2. Department of Medicine, University of Verona, Verona, Italy

3. Department of Interventional Cardiology, Papworth Hospital NHS Trust, Cambridge, UK

*Correspondence to aserrap@santpau.cat

Disclosure: Restricted grant from ABBOTT Vascular.

Support: The publication of this article was funded by Abbott Vascular. The views and opinions expressed are those of the authors and not necessarily those of Abbott Vascular.

Received: 05.02.16 **Accepted:** 13.04.16

Citation: EMJ Int Cardio. 2016;4[Suppl 13]:02-14.

ABSTRACT

Coronary artery disease (CAD) is the leading cause of mortality in patients ≥ 60 years old worldwide, and may result in stable angina, acute coronary syndromes (unstable angina or acute myocardial infarction), congestive heart failure, cardiac arrhythmia, or sudden death. A variety of medical therapies can treat the symptoms and arrest progression of CAD, but mechanical revascularisation of affected arteries is widely employed to ameliorate the symptoms of angina and improve prognosis, particularly in situations of multivessel disease, significant ischaemia, and in the setting of acute myocardial infarction.

Rates of surgical revascularisation by coronary artery bypass graft surgery have gradually fallen over recent decades, with a concomitant rise in percutaneous coronary intervention procedures. Such minimally invasive techniques have evolved considerably in the last four decades, from plain old balloon angioplasty, through initial use of bare-metal stents to mitigate acute vessel closure, to the advent of drug-eluting stents designed and proven to reduce rates of restenosis. Bioresorbable vascular scaffolds/bioabsorbable stents are a new and promising generation of intravascular devices that may potentially circumvent many of the problems associated with such permanent metallic implants. This article will review available clinical trial and real-life data on the Absorb™ Bioresorbable Vascular Scaffold (Abbott Vascular, Santa Clara, California, USA), and highlight the potential utility of this novel class of devices in the management of patients with CAD.

Keywords: Bioresorbable vascular scaffold (BRS), drug-eluting stents (DES), coronary angioplasty, coronary artery disease (CAD), interventional cardiology.

INTRODUCTION

Coronary artery disease (CAD) is the leading cause of mortality in patients ≥ 60 years old worldwide, and is the most common type of heart disease.¹ With complications CAD can progress into acute coronary syndrome (ACS), congestive heart failure, cardiac arrhythmia, or sudden death.

A variety of medical therapies can treat the symptoms and arrest progression of CAD, but mechanical revascularisation of affected arteries with percutaneous coronary intervention (PCI) is widely employed to ameliorate symptoms of

angina and improve prognosis. PCI is particularly useful in situations of multivessel disease (MVD), significant ischaemia or stable CAD (when suitable anatomy), unstable angina and acute myocardial infarction (MI), ST-segment elevation MI (STEMI), and non-ST-elevation ACS.²

INTERVENTIONAL CARDIOLOGY FOR CORONARY ARTERY DISEASE

Although the advent of balloon angioplasty (or percutaneous transluminal coronary angioplasty [PTCA]) in the late 1970s revolutionised coronary revascularisation, it was not until the widespread

adoption of intracoronary stents in the late 1980s/early 1990s that the high rates of abrupt vessel closure, peri-procedure heart attack, and requirement for urgent coronary artery bypass graft surgery could be addressed.³⁻⁷ The development of coronary artery stents for PCI in the late 1980s was a giant leap forward in interventional cardiology, with lower incidences of abrupt closure, peri-procedural heart attack, and of late restenosis rates over balloon angioplasty (or PTCA).

The first-generation stents were composed of metallic alloys (bare-metal stents [BMS]), and aimed to prevent acute vessel closure; however, although multicentre clinical trial data revealed that these devices reduced restenosis compared with PTCA, residual risk of clinical restenosis remained as high as 20% after 1 year.^{4,5,8}

Therefore, drug-eluting stents (DES) were developed at the turn of the century to overcome the high risk of acute vessel closure and restenosis and thus the need for target-lesion revascularisation (TLR) became associated with the use of BMS. DES boast an additional polymer coating and are a vehicle for an anti-restenotic drug, (e.g. everolimus [Xience V™, Abbott Vascular, Santa Clara, California, USA], zotarolimus, paclitaxel) which is delivered to the arterial wall over a period of a few months (depending on release kinetics) after implantation. These new-generation stents were demonstrated as superior to BMS with regards to the reduction of the risks for recurrent MI, stent thrombosis (ST), and TLR (about 70% risk reduction), which led to the preferential use of DES in the wide majority of PCIs.⁹⁻¹⁷

However, DES were in turn linked to their own limitations, in addition to the residual rate of late restenosis.^{18,19} ST still occurs in about 1-2% of patients during the first year post-implantation with a DES, warranting the need for new advancements in PCI to overcome these issues.^{20,21} In the long-term, a slow but continuous increase of events over time is observed with DES, as demonstrated by rates of ST of 1.4%, 2.9%, and 4.4% up to 4 years among 12,339 patients treated with everolimus-eluting, sirolimus-eluting, or paclitaxel-eluting stents, respectively, in the Bern-Rotterdam cohort study.²² The rationale behind the clinical need for a bioresorbable vascular scaffold (BRS) emerged because vessel scaffolding is only needed transiently, whilst available stents at the time constrained the vessel permanently. The perspective of positive long-term outcomes for

patients with no residual scaffold seemed appealing and led to the development of BRSs.²³

To date, three fully resorbable, controlled-drug releasing stents have received Conformité Européenne (CE) mark approval: Absorb™ (Abbott Vascular, Santa Clara, California, USA; everolimus-releasing BRS), DESolve™ (Elixir Medical, California, USA; novolimus-releasing BRS), and Magmaris™ (Biotronik, Switzerland; magnesium BRS).^{17,24} Due to the lack of wide availability (and therefore use in daily clinical practice) in Europe, and of real-world clinical data on the DESolve and Magmaris devices (post-approval studies are currently ongoing), this article will only review the available clinical trial and real-life data on the Absorb Vascular Scaffold.

POTENTIAL BENEFITS OF THE FULLY RESORBABLE VASCULAR SCAFFOLD

Principle and Device Technology

Angioplasty causes some injury to the coronary artery intima and media, leading some authors to explore the possibility of local inflammation, granulation, inflammatory cell infiltration, and extracellular matrix remodelling as possible mechanisms for post-procedure intimal hyperplasia restenosis formation.²⁵⁻²⁸

The Absorb Bioresorbable Vascular Scaffold (henceforth Absorb) was first CE marked in 2011 for the treatment of CAD and has since been implanted in over 125,000 patients from 104 countries. This innovative device is a first-of-its-kind everolimus-eluting stent that is naturally resorbed and fully metabolised. Absorb is more flexible (with a lower maximum compressive load) than metallic devices or Xience V™ (henceforth Xience).^{29,30} As it is made of poly-L-lactic acid (PLLA), a resorbable biocompatible material, it dissolves over time (~2-3 years), after which no device will be left.³¹

Potential Benefits of Bioresorbable Vascular Scaffold Technology

Lumen gain

The potential benefits of BRS technology that are not possible to obtain with permanent metallic implants include lumen gain with preserved native anatomy. The gradual hydrolysis and degradation of the device allows the PLLA materials to be replaced by functional cellular matrix, thus allowing

positive remodelling, lumen gain over time, and subsequent natural vasomotion (Figure 1).³¹⁻³³

Restored vessel function

The placement of a fully bioresorbable vascular temporary scaffold maintains the patency of the vessel and provides revascularisation in the short-term, but will gradually leave the vessel uncaged. Ultimately, the restored ability of a treated artery to respond to physiologic stimuli and therefore to flex, move, and pulsate may generate positive structural and functional long-term outcomes, according to some authors.³⁴⁻³⁷

Plaque regression

Absorb has also been shown to decrease total atherosclerotic plaque areas and plaque burden in the treated segment, which could represent a paradigm shift in PCI.³⁷⁻⁴⁰ In the first human case demonstrating the complete resorption *in vivo* of Absorb 5 years after implantation, substantial lumen enlargement due to plaque regression and adaptive remodelling was observed (Figure 2).⁴¹

Possibility for reduction of late events and better long-term outcomes

The eventual absence of a scaffold could eliminate chronic vessel irritation and inflammation, and theoretically the non-permanent modality of BRSs could represent an advantage over metal stents, particularly from the standpoint of long-term safety and device related very late adverse events (AE), as evidenced by recently published clinical and real-world data.^{7,20,38,42-47}

Possibility to perform multislice computed tomography follow-up

Multislice spiral computed tomography (MSCT) is a non-invasive assessment of coronary stenosis that can be hampered by metallic stent strut artefacts. However, BRS technology uses radiolucent materials and therefore does not generate such artefacts, allowing for the use of patency and/or absence of the device as long-term follow-up outcome measures.^{33,48,49}

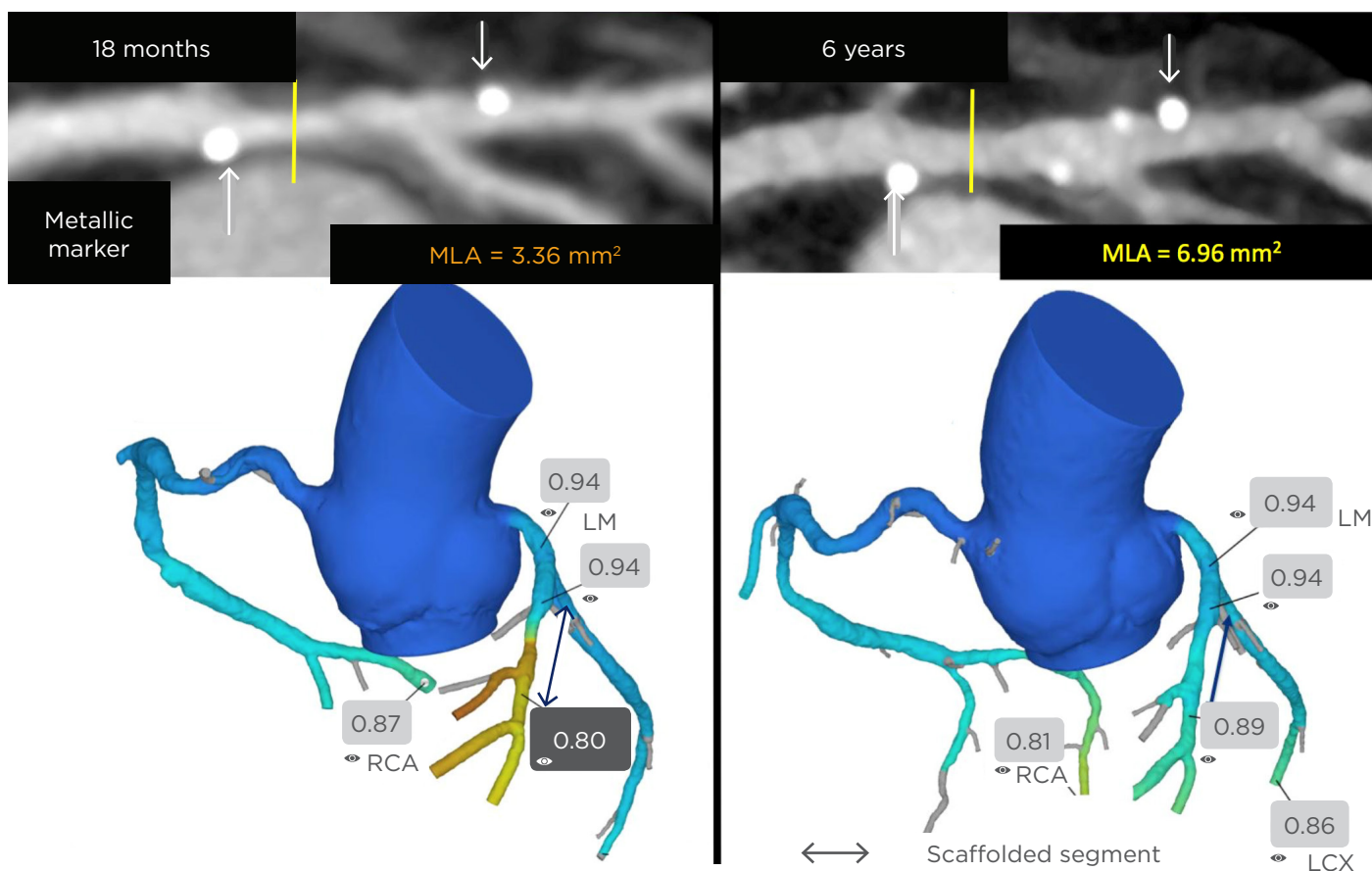


Figure 1: Case example of serial assessment of scaffolded segment at 18 and 72-month follow-up. Data from the ABSORB Cohort B Multislice Spiral Computed Tomography Sub-Study.³³ MLA: minimum lumen area; RCA: right coronary artery; LM: left main; LCX: left circumflex artery.

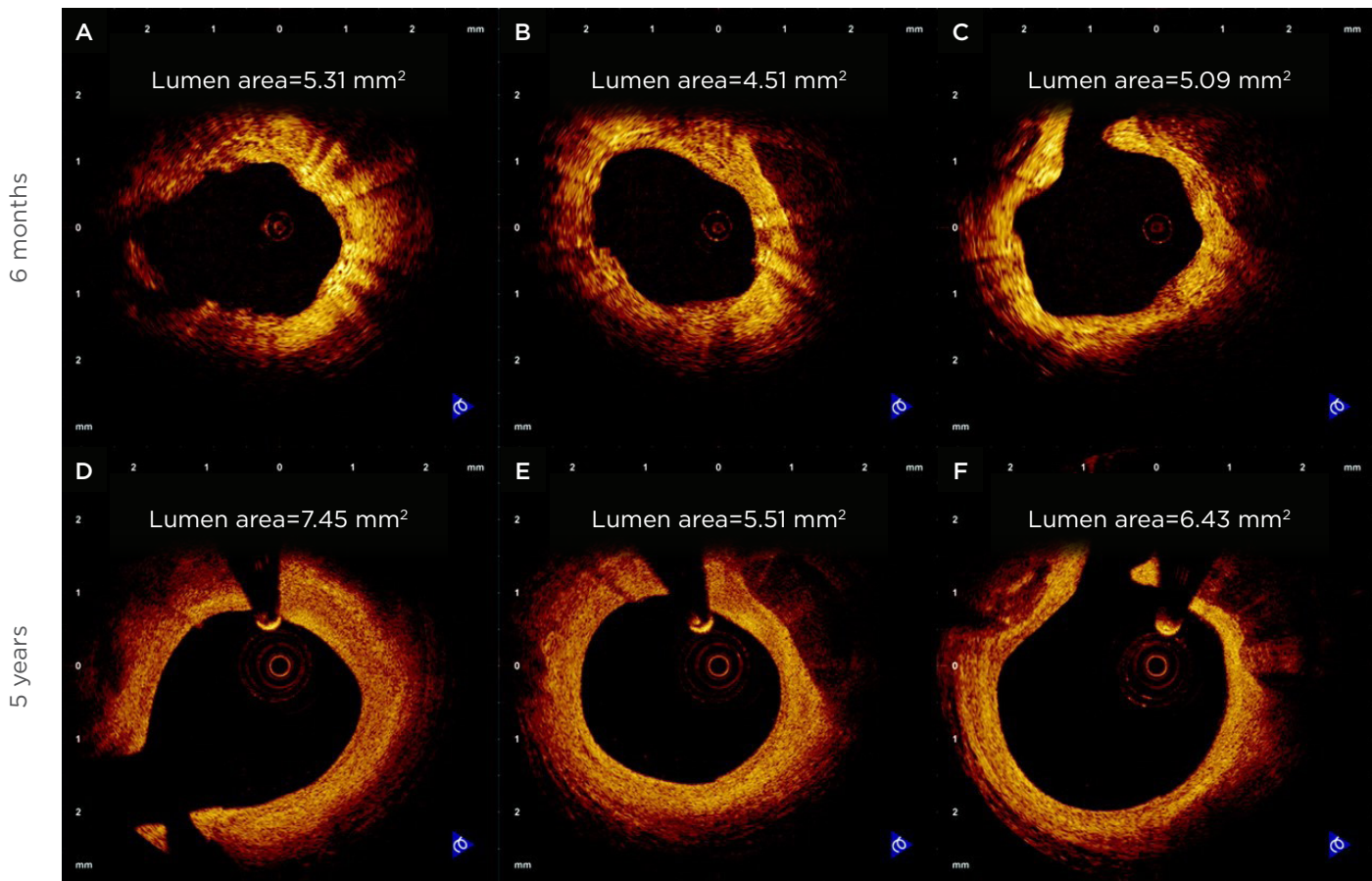


Figure 2. Optical coherence tomography images from matched sites at 6 months (A and C; St. Jude/Lightlab M3 time domain optical coherence tomography system) and 5 years (D and F; St. Jude/Lightlab C7XR Fourier domain OCT system) following stent implantation.⁴¹

Panel B represents the site of the minimal lumen area (4.51 mm²) at 6 months, whereas panel E represents the site of the minimal lumen area at 5 years (5.51 mm²). Lumen area was also increased at the matched sites from 6 months–5 years (5.31 mm² [A] versus 7.45 mm² [D]; 5.09 mm² [C] versus 6.43 mm² [F]). Note the complete disappearance of the scaffold struts at the 5-year follow-up, as well as the regular contour of the lumen compared with the 6-month follow-up.

AVAILABLE CLINICAL DATA ON BIORESORBABLE SCAFFOLD TECHNOLOGY

The ABSORB clinical trial programme is an extensive family of trials comprising several large, randomised clinical trials and registries involving >17,000 patients, exploring a broad range of patient and lesion types including ACS, STEMI, MVD, long lesions, bifurcations, and chronic total occlusion (CTO).

Absorb Cohort B

The programme that initially evaluated the safety and performance of Absorb comprised the ABSORB international study which was split into two cohorts (cohort A, n=30, 4 sites,

5-year follow-up; and cohort B, n=101, 12 sites, 5-year follow-up).^{31,38,46,50}

Study cohort B was a first-in-man, single-arm, non-randomised clinical study conducted within the European and Asia-Pacific regions.^{38,51} This study aimed to evaluate the safety and performance of the device after assessing safety at 180 days in cohort A patients, but also to understand the biological reactions of the vessel wall with multimodality imaging.

Cohort B was divided into two groups: group B1 (n=45) in which patients underwent invasive imaging by quantitative coronary angiography (QCA), intravascular ultrasound (IVUS), virtual histology IVUS (VH-IVUS), and optical coherence tomography (OCT) at baseline, 6, and 24 months;

the second group (B2, n=56) underwent the same invasive imaging at baseline, 12 months, and 3 years.

Results from the ABSORB Cohort B study at 5-year follow-up confirmed the long-term safety of Absorb for the treatment of relatively simple lesions, with a major adverse cardiac event (MACE; i.e. cardiovascular death, any MI, TLR) rate of 11.0% without any scaffold thrombosis. At 5 years, the investigators observed unchanged and stable lumen dimensions from mid to long-term (on OCT, mean lumen area and minimal lumen area were stable from 1-5 years), whereas historical data on late luminal loss up to 3 years after Xience implantation showed moderate but continuous reduction of the stented lumen.

Hyperechogenicity of the vessel wall with IVUS showed a continuous decrease of PLLA in the vessels over time, with undetectable levels at 5 years. The large majority of the scaffolded segments (>80%) exhibited vasodilatation post-nitrate administration, while significant reduction in plaque behind the struts occurred with a trend toward adaptive remodelling of the external elastic membrane (Figure 3).

Six-year follow-up results for Cohort B were presented at the 2016 European Association of Percutaneous Cardiovascular Interventions (EuroPCR) Congress.³³ Long-term serial non-invasive MSCT with functional assessment (FFRCT) was demonstrated as feasible to non-invasively assess the trans-scaffold long-term performance of the device, with qualitative diagnosis of patency obtained in the vast majority of patients (51 out of 54, 94%), and FFRCT was correlated with minimal luminal area ($R^2=0.31$). Late lumen enlargement was related to decrease of plaque/media, which was associated with adaptive remodelling. Although limited by the number of clinical observations, the results of this first-in-man clinical study set an encouraging precedent for the long-term results of other completed or ongoing trials evaluating this device; these data were further ascertained by real-world observational or registry studies conducted in daily clinical practice settings.⁵²⁻⁵⁴

Absorb II and III Clinical Trials

Recently, results from the ABSORB II⁵⁴ and III⁵⁵ randomised trials performed in Europe and the USA showed that treatment of non-complex obstructive CAD with BRS was non-inferior to Xience, the best in class cobalt-chromium everolimus-eluting stent, for target-lesion failure (TLF). The ABSORB

III study was a large, multicentre, non-inferiority, randomised trial with 2,008 patients with stable or unstable angina and up to two *de novo* lesions randomised in 2:1 fashion to the Absorb or Xience devices, and designed to support the US Food and Drug Administration (FDA) approval of the Absorb BRS. In total, 1,322 patients received Absorb and 686 patients received Xience. The primary endpoint was TLF (cardiac death, target lesion MI, or ischaemia-driven TLR) at 1 year.

TLF at 1 year occurred in 7.8% of Absorb patients and 6.1% of Xience patients (95% confidence interval [CI]: 1.7% [-0.5-3.9%], p -non-inferiority=0.007; p -superiority=0.16). Patients treated with Absorb and Xience had non-significantly different rates of cardiac death (0.6% versus 0.1%, $p=0.29$), target lesion MI (6.0% versus 4.6%, $p=0.18$), and ST (1.5% versus 0.7%, $p=0.13$). In addition, there were no statistically significant differences between Absorb and Xience in the 1-year rates of ischaemia-driven TLR (3.0% versus 2.5%, $p=0.50$), angina (18.3% versus 18.4%, $p=0.93$), or ischaemia-driven TLR (5.0% versus 3.7%, $p=0.21$). Long-term follow-up data from this and other large scale trials are required to determine whether these findings translate into improved long-term clinical outcomes beyond 1 year.

Absorb China and Absorb Japan Clinical Trials

Two randomised trials from Asia, ABSORB China⁵⁶ and ABSORB Japan,⁵⁷ enrolled patients with non-complex lesions for elective PCI and were in line with ABSORB III, indicating the consistent non-inferiority of BRS in terms of late lumen loss (LLL) and 1-year TLF when compared with the Xience stent.

Absorb China

ABSORB China enrolled 480 patients undergoing PCI, randomised to receive in a 1:1 ratio, the Absorb BRS or the Xience stent. The non-inferiority trial was designed to assess the angiographic efficacy and clinical safety of Absorb compared with Xience, for regulatory approval in China. The primary endpoint was angiographic in-segment LLL powered for non-inferiority with a margin of 0.15 mm. The Absorb BRS was non-inferior to Xience at 1 year, meeting the primary endpoint of non-inferiority. In-segment LLL (in-device +5 mm proximal and distal edge vascular responses) was 0.19 ± 0.38 mm versus 0.13 ± 0.38 mm, (p -non-inferiority=0.01) in the Absorb BRS versus the Xience stent, respectively. There were no definite scaffold/stent thromboses during the follow-up period.

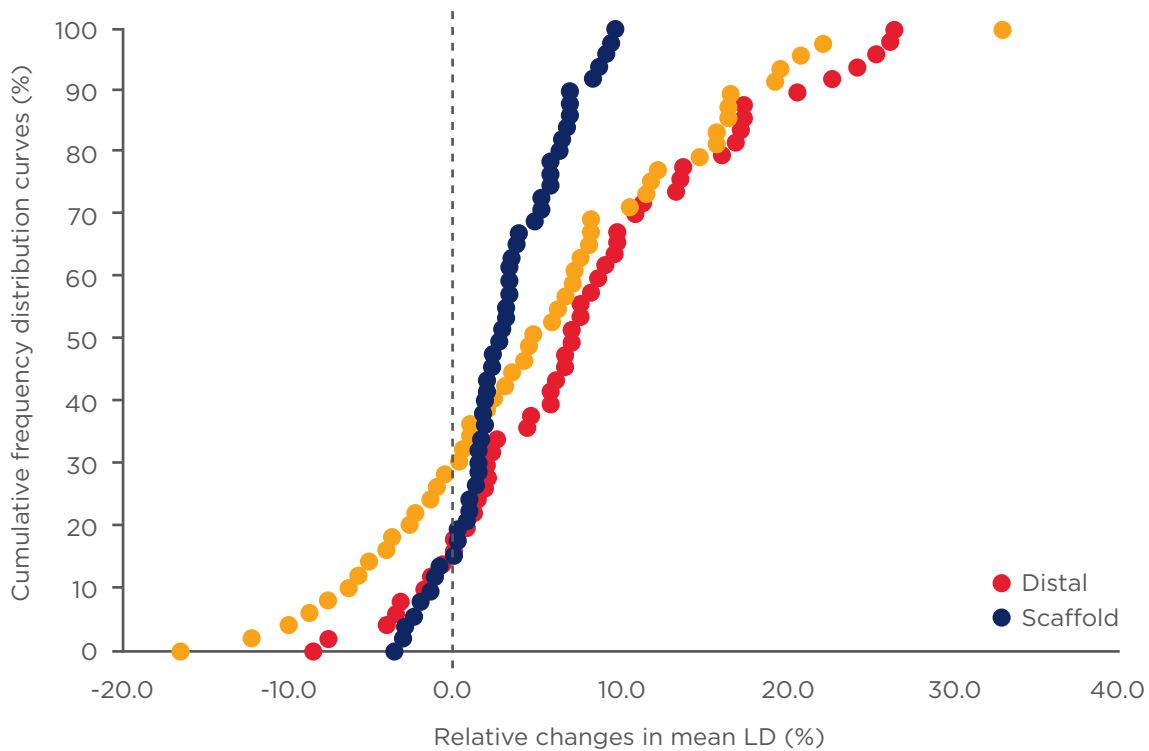


Figure 3: ABSORB COHORT B Study.

Vasomotion test (Relative changes in mean LD) before and after nitrate administration at 5 years (n=53).⁵¹ LD: lumen diameter.

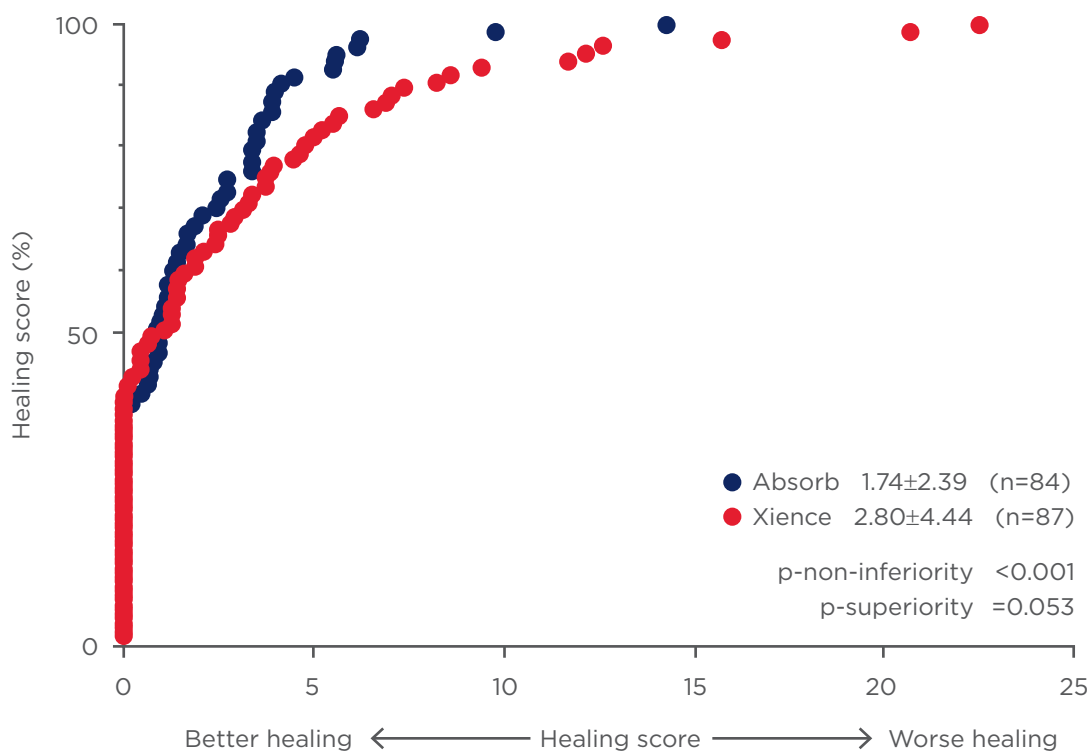


Figure 4: Cumulative distribution curves of the healing score between Absorb and everolimus-eluting stent arms in STEMI patients.⁶³

Healing score in the Absorb arm was non-inferior to that of the everolimus-eluting stent arm with a trend towards superiority.

STEMI: ST-segment elevation myocardial infarction.

TLF rates and individual components of cardiac death, target-vessel MI, and ischaemia-driven TLR were similar among the groups at 1 year.

Absorb Japan

ABSORB Japan enrolled 400 patients undergoing elective PCI, randomised to receive in a 2:1 ratio, Absorb or Xience. The non-inferiority trial was designed to assess the safety and angiographic efficacy of Absorb compared with Xience with the aim of receiving regulatory approval in Japan. The primary clinical endpoint was TLF at 1 year, while the secondary efficacy endpoint was angiographic in-segment LLL at 13 months.

Absorb was non-inferior to Xience at 1 year, as TLF occurred in 4.2% of Absorb patients and in 3.8% of Xience patients. The secondary endpoint of in-segment LLL (in-device +5 mm proximal and distal edge vascular responses) did not differ among the groups and was 0.13 ± 0.30 mm versus 0.12 ± 0.32 mm ($p=0.74$) in the Absorb versus Xience groups, respectively. No differences in the rates of stent/scaffold thrombosis were observed (1.5% in both arms).

FROM CLINICAL DATA TO DAILY CLINICAL PRACTICE: IDENTIFYING PATIENTS WHO COULD BENEFIT FROM BIORESORBABLE VASCULAR SCAFFOLD

Patients with more complex CAD than those enrolled in ABSORB randomised trials (MVD, long lesions, CTO, and STEMI, which are often among exclusion criteria in clinical trials) could very well be the ones to benefit from the advancement of technology and the implementation of BRSs into daily clinical practice. Real-world data on the use of Absorb are becoming available, and may allow clinicians to draw some suggestions on which clinical settings are best suited for BRS implantation.

Patients with ST-Segment Elevation Myocardial Infarction

STEMI patients are usually young patients, often undergoing PCI for the first time for focal soft lesions associated to large necrotic core-containing plaques. In these patients, arterial remodelling and healing is delayed due to chronic inflammation, and malapposed stent struts and residual thrombus are more frequent than in patients with stable CAD.⁵⁸⁻⁶⁰ The possibility of implanting

fully BRSs into culprit lesions in STEMI patients has thus sparked particular interest as a result of their advantageous long-term clinical and safety outcomes, namely the restoration of vessel physiology and the potential for reduced late events frequency.^{61,62}

TROFI-II trial

The TROFI-II trial was a multicentre, single blind, non-inferiority, randomised clinical trial, aiming to evaluate the safety and efficacy of the Absorb device in STEMI patients.^{63,64} This trial was the first conducted in a head-to-head setting against a standard DES.⁶³ Patients (N=191) were randomly assigned (1:1) to undergo PCI with either Absorb (n=95) or a metallic everolimus-eluting stent (Xience, n=96). The primary endpoint was the healing score based on the presence of uncovered and/or malapposed stent struts and intraluminal filling defects (as measured by optical frequency domain imaging).

At 6 months, the primary endpoint of non-inferiority was met, and the healing score was lower in the Absorb arm versus the everolimus-eluting arm (1.74 ± 2.39 versus 2.80 ± 4.44 , p -non-inferiority <0.001) (Figure 4). Of note, one definite sub-acute ST occurred in the Absorb arm (1.1%). After a 6-month follow-up, stenting with Absorb in STEMI patients undergoing PCI resulted in a nearly complete arterial healing comparable with that of a metallic DES, with a trend towards superiority. These findings have relevant clinical implications and support the comparable acute and mid-term performance and safety of both devices in the high-thrombogenic STEMI clinical setting.

Patients with Multivessel Disease

The treatment of MVD requires the use of multiple overlapped long DES, which is challenging on the technical side and increases the risk of repeat interventions; this is all the more difficult due to the previous placement of metallic stents.⁶⁵ MVD was associated with a higher rate of late ST and MACEs, as evidenced in the Arterial Revascularization Therapies Study II (ARTS II) trial (9.4% of ST at 5 years, accounting for 32% of all MACE).⁶⁶ This patient subpopulation could benefit from Absorb as the placement of a BRS prevents the implantation of multiple or metal-caged vessels forming a 'full-metal jacket'.

GABI-R registry

The German-Austrian-ABSORB RegIsteR (GABI-R) aimed to investigate the safety and efficacy of Absorb in an all-comers cohort with CAD.^{67,68} The 30-day follow-up preliminary results were presented at EuroPCR 2016 and demonstrated the acute safety of the device in this real-world registry of 2,168 patients, of which 60.2% had MVD.⁶⁹

The MACE rate (cardiovascular death, any MI, TLR) was very low in this complex cohort of

patients at 1.8%. The definite/probable scaffold thrombosis rate was acceptable at 1.3%. Nineteen events were recorded in the first 7 days, which is probably related to the implantation technique. The importance of technique was shown in a *post hoc* analysis where patients treated before 2015 had higher target-vessel failure (2.3%) and ST (1.5%) compared with patients treated from 2015 onwards, at rates of 1.3% and 0.9%, respectively.⁶⁹ Patient recruitment has now finished and long-term follow-up (5 years) analysis will help ascertain these preliminary findings.

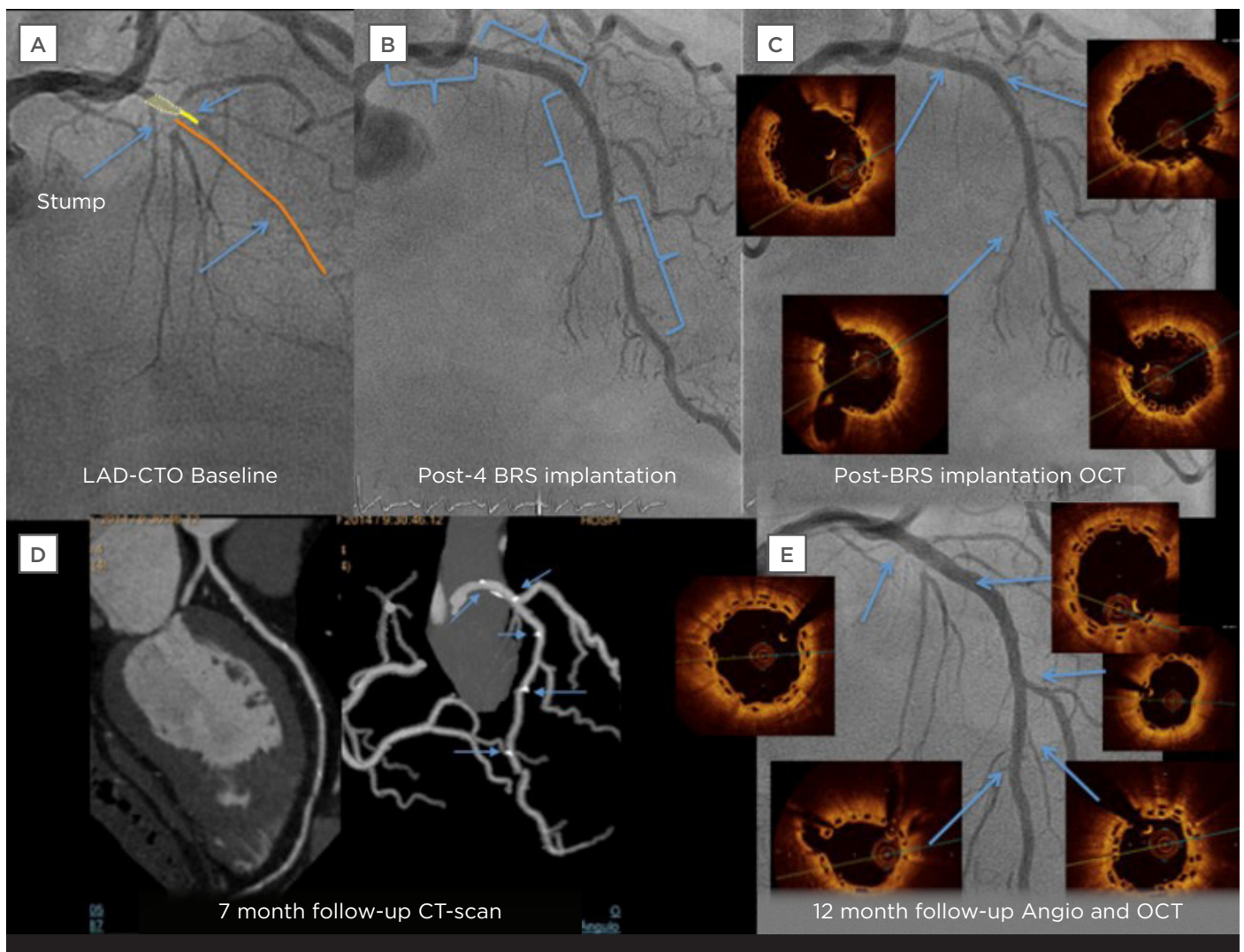


Figure 5: Representative easy chronic total occlusion case with diffuse disease of the prox-mid and distal left anterior descending artery treated with four overlapped Absorb bioresorbable vascular scaffolds.

A) LAD-CTO before PCI. B) Immediate angiographic assessment after BRS implantation. C) Immediate OCT assessment after BRS implantation. D) MSCT at 7 months after BRS implantation in the mid-LAD. Arrows indicate position of the radiopaque markers at the extremities of the scaffold. E) OCT assessment, 12 months after BRS implantation. All struts were covered by neointima. CTO: chronic total occlusion; LAD: left anterior descending artery; PCI: percutaneous coronary intervention; BRS: bioresorbable vascular scaffold; OCT: optical coherence tomography; MSCT: multislice spiral computed tomography; CT: computed tomography.

REPARA trial

The REgistry of PAtients with BioResorbable Device in Daily Clinical Practice (REPARA) was a prospective, open-label, multicentre, Iberian registry comprising 2,448 patients from 60 centres in Spain and Portugal, which aimed to evaluate the safety and efficacy of BRS usage in real-world patients under well-controlled implementation criteria.

Data from 2,448 patients at 30-day follow-up were presented at EuroPCR 2016.⁷⁰ The mean number of diseased vessels was 1.5 ± 0.7 . Stenting with Absorb achieved a high angiographic success rate (procedural success rate of 98.9% for 3,950 implanted stents, of which 83.0% were Absorb). Device safety, specifically regarding 30-day MACE, including acute MI (1.5%), cardiac death (0.3%), and ST (0.9%) seemed comparable to DES and the event occurrence rate was similar to those reported in the GHOST-EU registry at 30-day follow-up.⁷¹ At 6 months, results showed 2.1% MI, 0.6% cardiac death, and 1.4% ST, demonstrating good results with REPARA despite the low pre-dilation (77.5%) and post-dilation (45.6%) used in this trial.

IT-DISAPPEARS Study

The IT-DISAPPEARS study (N=1,002) is a prospective, open-label, multicentre, Italian registry investigating patients with MVD (at least two epicardial vessels) or long lesions (>24 mm).^{72,73} This registry could provide the first evidence worldwide concerning the performance of the Absorb BRS in patients with high-risk diffuse coronary disease.⁷⁴ Preliminary 30-day results were presented at EuroPCR 2016. Ninety-seven point nine percent of the lesions were pre-dilated, and 96% of treated patients received post-dilatation, including 87% with a non-compliant balloon. The rate of scaffold thrombosis was 0.6%, which is equivalent to the 30-day rate of stent thrombosis expected with conventional DES. One patient died from non-cardiac causes and device-related cardiac events occurred in 3.3% of patients. The sub-analysis of MVD patients (n=249) showed excellent results at 30 days: no death, 4% MI, 0.4% TLR, and 0.4% ST. These results demonstrate that a good implantation technique allows the device to be safely implanted in a subset of patients with more complex lesions, such as those with MVD and long lesions.

Patients with Long Lesions

Stent length has been demonstrated as an independent predictor of ST and restenosis. In

metallic stents, the permanent full-metal jacket associated with stent length constitutes a safety limitation and has the potential to interfere with future coronary surgery (especially in younger patients).⁷⁵⁻⁷⁸ Therefore, the placement of a BRS, preventing the implantation of long-segment metal-caged vessels, is an attractive perspective due to the degradation of the scaffold.

Single-centre studies

In a Spanish single-centre ACAR⁷⁹ of 150 consecutive patients, 66 (36%) had long lesions (>25 mm). Mean length of implanted BRS was 40.7 mm. During a mean follow-up of 294-226 days, TLR occurred in 4.5% and scaffold thrombosis in 3.1%, with no cardiac deaths.

Underdog study

In a propensity-matched comparison, multicentre study (underdog), the BRS (n=162) was compared with second-generation DES (n=162) in patients with long coronary lesions requiring overlap.⁸⁰ Safety was evaluated as a device-oriented composite endpoint (DOCE) including cardiac death, target-vessel MI, and TLR. At 1 year, DOCE rates were not significantly different between both arms (BRS: 5.6% versus DES: 7.6%), as well as stent/scaffold thrombosis occurrence (BRS: 1.2% versus DES: 1.9%). While myocardial injury seemed more frequent in the BRS group (25% versus 12%, respectively, $p=0.001$), it was not observed as being DOCE-related (hazard ratio: 1.1, 95% confidence interval: 0.97-1.2, $p=0.2$).

However, BRS was associated to significantly higher imaging technique and enhanced stent visualisation use ($p=0.0001$ for both endpoints).

GABI-R registry

In the GABI-R registry, total scaffold length was 27.6 ± 17.0 mm, and 5.9% of patients had long lesions >34 mm.^{67,68}

IT-DISAPPEAR study

In the IT-DISAPPEAR study, 898 patients had long lesions, with an average scaffold length of 46.9 mm. At 30 days, there were rates of 4% MI, 0.1% deaths, 0.6% ST, and 3.5% DOCE.

Patients with Chronic Total Occlusion

CTOs are the most challenging lesions for PCI. After wire crossing and recanalisation, a long coronary diseased segment must usually be stented.

The length of the stented segment is a predictor of events at follow-up such as need for repeat revascularisation and ST. Moreover, permanent caging of the coronary artery inhibits the recovery of the physiological properties of the vessel. The use of a BRS is an attractive alternative in this setting, avoiding the full-metal jacket of the artery and potentially restoring vessel functionality. Furthermore, BRSs allow for non-invasive imaging of the coronary arteries, such as with MSCT, to verify vessel patency (Figure 5). Despite all those potential advantages, there is as yet no evidence supporting the use of BRSs in CTO. Questions have also been raised concerning the delivery of the scaffold to complex lesions.

Single-centre registries

The ABSORB-CTO Pilot Study⁴⁹ was performed on 35 consecutive patients to assess the safety and performance of BRSs in true CTO lesions. Scaffolds were deployed after mandatory pre-dilation and IVUS analysis to guide the optimal device for pre-dilatation (non-compliant balloon in soft plaques or cutting balloon in fibrocalcific plaques). OCT was performed after BRS implantation and at 10-12 months. MSCT was performed at baseline and at 6-8 months. Mean patient age was 61±10 years. The most frequent vessel treated was the right coronary artery (46%). Lesions were classified as intermediate (49%) or difficult/very difficult (26%), according to the Japanese CTO complexity score. Pre-dilation was performed in 100% of lesions, using cutting balloons in 71% of these. The total scaffold length implanted per lesion was 52±23 mm, and all scaffolds were delivered and deployed successfully. Post-dilation was undertaken in 63% of patients, guided by OCT. Two cases of asymptomatic scaffold restenosis were observed by MSCT at 6 months (5.7%), and subsequently confirmed by angiography. In-scaffold late loss was 0.28±0.31 mm. At 12 months, no scaffold thrombosis or MACE were reported. OCT at follow-up showed that 94% of struts were well apposed and covered (5% of uncovered struts and 1% of non-apposed struts), and only 0.6% of struts were non-apposed and uncovered.

Ojeda et al.⁸¹ conducted a registry on 46 CTO lesions treated with BRSs. Mean scaffold length was 43±21 mm. Technical success was achieved in 45 patients (98%) and one patient presented a non-Q peri-procedural MI (2.4%). At mid-term

follow-up (13±5 months), the overall MACE rate was 4.8% due to two repeat revascularisations.

Overall, these two small registries showed that implantation of Absorb in a population with selected CTO, using a precise BRS implantation technique, is feasible and associated with good angiographic and short-term clinical results that are maintained over 12 months. However, a randomised trial including more complex CTO lesions and long-term follow-up is needed. The use of MSCT for non-invasive assessment of CTO patients treated with radiolucent scaffolds was accurate and could be useful to follow selected patients and complex lesions treated with this new technology.

CONCLUSIONS

The PCI landscape has evolved considerably in the last four decades. BRSs are a new and promising generation of intravascular devices that may potentially circumvent many of the problems of permanently implanted BMSs. Lesion preparation, adequate vessel sizing (including with the use of intravascular imaging techniques), post-dilation while keeping in mind the BRS expansion limits, and the importance of optimised dual antiplatelet therapy (DAPT) are mainstays of BRS PCI.

In non-complex (*de novo*, short, and ideally non-calcified) lesions, Absorb is non-inferior to best-in-class Xience stent in clinical outcomes. The benefit of implanting Absorb is not seen in the short or mid-term. The real potential advantages from this technology are expected to emerge after complete dissolution of the device ≥3-4 years. The final absence of a scaffold may restore the treated vessel to enable natural vascular function and restoration of endothelium-dependent vasomotion. Stable lumen dimension with improved lumen gain over time and the elimination of a permanent source of inflammation when the scaffold disappears may have a positive impact on late clinical events attributed to either late restenosis, late and very late scaffold thrombosis, or neoatherosclerosis. The disappearance of the device also leaves open all options should future interventions be needed.

In some subsets of patients with more complex lesions such as MVD, long diffuse lesions, or CTO, Absorb has been shown to be effective and safe, although registry results need to be validated in randomised trials. Moreover, BRSs offer a new treatment option for long-diffuse coronary disease

and CTO, which today are either left alone and treated medically, or require a full-metal jacket, where the entire vessel is filled with stents. Absorb offers the opportunity to perform a 'full-plastic jacket' that will not permanently stay in the vessel, allowing for vessel restoration and not precluding future interventions. Currently available findings provide the basis for further exploration in clinically oriented outcome trials on complex cases.

Of particular interest is the cohort of patients with STEMI, as thrombotic lesions, which are frequently atheromas with a necrotic core covered by a thin fibrous cap, may represent the best scenario for vascular restoration therapy with BRS. BRSs,

which in the long-term are completely replaced by connective tissue and smooth muscle cells, may overcome the problem of metal persistence into the coronary vessel wall and may at the same time stabilise a thin-cap fibroatheroma with a neointimal layer. However, recent meta-analyses have reported concerns over scaffold thrombosis and MI in BRS after 6-month and 1-year follow-up periods; nevertheless, the mathematical methods used in these statistical analyses have been questioned, and these findings remain to be confirmed in the long-term.⁸²⁻⁸⁴ Refinement and standardisation of implantation technique should contribute to the reduction of acute and late AEs, as also shown in GABI-R.

Acknowledgements

Medical writing assistance was provided by Dr Caroline Charles (Scilink Medical Writing, Biarritz, France).

REFERENCES

1. World Health Organization. Deaths from coronary heart disease. 2004. Available at: http://www.who.int/cardiovascular_diseases/en/cvd_atlas_14_deathHD.pdf. Last accessed: January 2016.
2. Keeley EC et al. Primary angioplasty versus intravenous thrombolytic therapy for acute myocardial infarction: a quantitative review of 23 randomised trials. *Lancet*. 2003;361(9351):13-20.
3. Serruys PW et al. Angiographic follow-up after placement of a self-expanding coronary-artery stent. *N Engl J Med*. 1991; 324(1):13-7.
4. Serruys PW et al. A comparison of balloon-expandable-stent implantation with balloon angioplasty in patients with coronary artery disease. Benestent Study Group. *N Engl J Med*. 1994;331(8):489-95.
5. Fischman DL et al. A randomized comparison of coronary-stent placement and balloon angioplasty in the treatment of coronary artery disease. Stent Restenosis Study Investigators. *N Engl J Med*. 1994;331(8):496-501.
6. Schatz RA et al. Clinical experience with the Palmaz-Schatz coronary stent. Initial results of a multicenter study. *Circulation*. 1991;83(1):148-61.
7. Brodie BR et al. Very late hazard with stenting versus balloon angioplasty for ST-elevation myocardial infarction: a 16-year single-center experience. *J Interv Cardiol*. 2014;27(1):21-8.
8. Cutlip DE et al. Clinical restenosis after coronary stenting: perspectives from multicenter clinical trials. *J Am Coll Cardiol*. 2002;40(12):2082-9.
9. Kolh P et al. 2014 ESC/EACTS Guidelines on myocardial revascularization: the Task Force on Myocardial Revascularization of the European Society of Cardiology (ESC) and the European Association for Cardio-Thoracic Surgery (EACTS). Developed with the special contribution of the European Association of Percutaneous Cardiovascular Interventions (EAPCI). *Eur J Cardiothorac Surg*. 2014;46(4):517-92.
10. Sabate M et al. Everolimus-eluting stent versus bare-metal stent in ST-segment elevation myocardial infarction (EXAMINATION): 1 year results of a randomised controlled trial. *Lancet*. 2012;380(9852):1482-90.
11. Räber L et al. Effect of biolimus-eluting stents with biodegradable polymer vs bare-metal stents on cardiovascular events among patients with acute myocardial infarction: the COMFORTABLE AMI randomized trial. *JAMA*. 2012;308(8):777-87.
12. Sabate M et al. Comparison of newer-generation drug-eluting with bare-metal stents in patients with acute ST-segment elevation myocardial infarction: a pooled analysis of the EXAMINATION (clinical Evaluation of the Xience-V stent in Acute Myocardial InfArcTION) and COMFORTABLE-AMI (Comparison of Biolimus Eluted From an Erodible Stent Coating With Bare Metal Stents in Acute ST-Elevation Myocardial Infarction) trials. *JACC Cardiovasc Interv*. 2014;7(1):55-63.
13. Palmerini T et al. Clinical outcomes with drug-eluting and bare-metal stents in patients with ST-segment elevation myocardial infarction: evidence from a comprehensive network meta-analysis. *J Am Coll Cardio*. 2013;62(6):496-504.
14. Moses JW et al. Sirolimus-eluting stents versus standard stents in patients with stenosis in a native coronary artery. *N Engl J Med*. 2003;349(14):1315-23.
15. Vedat A et al. Treatment of patients with coronary artery disease with biodegradable polymer based paclitaxel-eluting Infimum coronary stent system: results of 1-year clinical follow-up a single center experience. *Indian Heart J*. 2009;61(3):254-7.
16. Stone GW et al. A polymer-based, paclitaxel-eluting stent in patients with coronary artery disease. *N Engl J Med*. 2004;350(3):221-31.
17. Fihn SD et al. 2012 ACCF/AHA/ACP/AATS/PCNA/SCAI/STS Guideline for the diagnosis and management of patients with stable ischemic heart disease: a report of the American College of Cardiology Foundation/American Heart Association Task Force on Practice Guidelines, and the American College of Physicians, American Association for Thoracic Surgery, Preventive Cardiovascular Nurses Association, Society for Cardiovascular Angiography and Interventions, and Society of Thoracic Surgeons. *J Am Coll Cardiol*. 2012;60(24):e44-e164.
18. McFadden EP et al. Late thrombosis in drug-eluting coronary stents after discontinuation of antiplatelet therapy. *Lancet*. 2004;364(9444):1519-21.
19. Lagerqvist B et al. Long-term

- outcomes with drug-eluting stents versus bare-metal stents in Sweden. *N Engl J Med.* 2007;356(10):1009-19.
20. Yamaji K et al. Very long-term (15 to 20 years) clinical and angiographic outcome after coronary bare metal stent implantation. *Circ Cardiovasc Interv.* 2010;3(5):468-75.
21. Gada H et al. 5-year results of a randomized comparison of XIENCE V everolimus-eluting and TAXUS paclitaxel-eluting stents: final results from the SPIRIT III trial (clinical evaluation of the XIENCE V everolimus eluting coronary stent system in the treatment of patients with de novo native coronary artery lesions). *JACC Cardiovasc Interv.* 2013;6(12):1263-6.
22. Räber L et al. Very late coronary stent thrombosis of a newer-generation everolimus-eluting stent compared with early-generation drug-eluting stents: a prospective cohort study. *Circulation.* 2012;125(9):1110-21.
23. Serruys PW et al. Incidence of restenosis after successful coronary angioplasty: A time-related phenomenon. A quantitative angiographic study in 342 consecutive patients at 1, 2, 3, and 4 months. *Circulation.* 1988;77:361-71.
24. Diagnostic and Interventional Cardiology. Elixir Receives European Approval for Fully Bioresorbable Novolimus-eluting Coronary Stent. Available at: <http://www.dicardiology.com/article/elixir-receives-european-approval-fully-bioresorbable-novolimus-eluting-coronary-stent> Last accessed: 23 June 2016.
25. Forrester JS et al. A paradigm for restenosis based on cell biology: clues for the development of new preventive therapies. *J Am Coll Cardiol.* 1991;17(3):758-69.
26. Wilensky RL et al. Vascular injury, repair, and restenosis after percutaneous transluminal angioplasty in the atherosclerotic rabbit. *Circulation.* 1995;92(10):2995-3005.
27. Van der Heiden K et al. The effects of stenting on shear stress: relevance to endothelial injury and repair. *Cardiovasc Res.* 2013;99(2):269-75.
28. Chaabane C et al. Biological responses in stented arteries. *Cardiovasc Res.* 2013;99(2):353-63.
29. Oberhauser JP et al. Design principles and performance of bioresorbable polymeric vascular scaffolds. *Eurointervention.* 2009;5 Suppl F:F15-22.
30. Gundogan B et al. Bioabsorbable stent quo vadis: a case for nano-theranostics. *Theranostics.* 2014;4(5):514-33.
31. Serruys PW et al. A bioabsorbable everolimus-eluting coronary stent system (ABSORB): 2-year outcomes and results from multiple imaging methods. *Lancet.* 2009;373(9667):897-910.
32. Ormiston JA et al. First serial assessment at 6 months and 2 years of the second generation of absorb everolimus-eluting bioresorbable vascular scaffold: a multi-imaging modality study. *Circ Cardiovasc Interv.* 2012;5(5):620-32.
33. Serruys PW. Six-year follow-up of the first-in-man use of a polylactide everolimus-eluting BRS for the treatment of coronary stenosis: An assessment of FFR by multislice CT. ABSORB Cohort B MSCT Sub-Study. Presented at EuroPCR, 17 May 2016.
34. Serruys PW et al. From metallic cages to transient bioresorbable scaffolds: change in paradigm of coronary revascularization in the upcoming decade? *Eur Heart J.* 2012;33(1):16-25b.
35. Waksman R. Biodegradable stents: they do their job and disappear. *J Invasive Cardiol.* 2006;18(2):70-4.
36. Garcia-Garcia HM et al. Assessing bioresorbable coronary devices: methods and parameters. *JACC Cardiovasc Imaging.* 2014;7(11):1130-48.
37. Simsek C et al. Long-term invasive follow-up of the everolimus-eluting bioresorbable vascular scaffold: five-year results of multiple invasive imaging modalities. *Eurointervention.* 2016;11(9):996-1003.
38. Serruys PW et al. Dynamics of vessel wall changes following the implantation of the absorb everolimus-eluting bioresorbable vascular scaffold: a multi-imaging modality study at 6, 12, 24 and 36 months. *Eurointervention.* 2014;9(11):1271-84.
39. Onuma Y et al. Five-year clinical and functional multislice computed tomography angiographic results after coronary implantation of the fully resorbable polymeric everolimus-eluting scaffold in patients with de novo coronary artery disease: the ABSORB cohort A trial. *JACC Cardiovasc Interv.* 2013;6(10):999-1009.
40. Campos CM et al. Impact of the Everolimus-eluting Bioresorbable Scaffold in Coronary Atherosclerosis. *Rev Esp Cardiol (Engl Ed.).* 2016;69(2):109-16.
41. Karanasos A et al. Five-year optical coherence tomography follow-up of an everolimus-eluting bioresorbable vascular scaffold: changing the paradigm of coronary stenting? *Circulation.* 2012;126(7):e89-91.
42. König A et al. Influence of stent design and deployment technique on neointima formation and vascular remodeling. *Z Kardiol.* 2002;91 Suppl 3:98-102.
43. Joner M et al. Pathology of drug-eluting stents in humans: delayed healing and late thrombotic risk. *J Am Coll Cardiol.* 2006;48(1):193-202.
44. Okamura T et al. In vivo evaluation of stent strut distribution patterns in the bioabsorbable everolimus-eluting device: an OCT ad hoc analysis of the revision 1.0 and revision 1.1 stent design in the ABSORB clinical trial. *Eurointervention.* 2010;5(8):932-8.
45. Brugaletta S et al. Comparison between the first and second generation bioresorbable vascular scaffolds: a six month virtual histology study. *Eurointervention.* 2011;6(9):1110-6.
46. Diletti R et al. Clinical and intravascular imaging outcomes at 1 and 2 years after implantation of absorb everolimus eluting bioresorbable vascular scaffolds in small vessels. Late lumen enlargement: does bioresorption matter with small vessel size? Insight from the ABSORB cohort B trial. *Heart.* 2013;99(2):98-105.
47. Guo N et al. Incidence, mechanisms, predictors, and clinical impact of acute and late stent malapposition after primary intervention in patients with acute myocardial infarction: an intravascular ultrasound substudy of the Harmonizing Outcomes with Revascularization and Stents in Acute Myocardial Infarction (HORIZONS-AMI) trial. *Circulation.* 2010;122(11):1077-84.
48. Bruining N et al. Quantitative multi-modality imaging analysis of a bioabsorbable poly-L-lactic acid stent design in the acute phase: a comparison between 2- and 3D-QCA, QCU and QMSCT-CA. *Eurointervention.* 2008;4(2):285-91.
49. Vaquerizo B et al. One-Year Results of Bioresorbable Vascular Scaffolds for Coronary Chronic Total Occlusions. *Am J Cardiol.* 2016;117(6):906-17.
50. Ormiston JA et al. A bioabsorbable everolimus-eluting coronary stent system for patients with single de-novo coronary artery lesions (ABSORB): a prospective open-label trial. *Lancet.* 2008;371(9616):899-907.
51. Serruys PW et al. Five-year Follow-up of the First-in-Man Use of a Polylactide Bioresorbable Scaffold Eluting Everolimus for Treatment of Coronary Stenosis; A Serial Multi-imaging Modality Study. *J Am Coll Cardiol.* 2015;66(15_S).
52. Abbott. Abbott completes enrollment of Absorb™ randomized clinical trials in the United States, Japan and China. 2014. Available at: <http://abbott.mediaroom.com/2014-04-10-Abbott-Completes-Enrollment-of-Absorb-Randomized-Clinical-Trials-in-the-United-States-Japan-and-China>. Last accessed: Jan 2016.
53. Abizaid A et al. The ABSORB EXTEND study: preliminary report of the twelve-month clinical outcomes in the first 512 patients enrolled. *Eurointervention.* 2015;10(12):1396-401.
54. Serruys PW et al. A bioresorbable everolimus-eluting scaffold versus a

- metallic everolimus-eluting stent for ischaemic heart disease caused by de-novo native coronary artery lesions (ABSORB II): an interim 1-year analysis of clinical and procedural secondary outcomes from a randomised controlled trial. *Lancet*. 2015;385(9962):43-54.
55. Ellis SG et al. Everolimus-Eluting Bioresorbable Scaffolds for Coronary Artery Disease. *N Engl J Med*. 2015; 373(20):1905-15.
56. Gao R et al. Bioresorbable Vascular Scaffolds Versus Metallic Stents in Patients With Coronary Artery Disease: ABSORB China Trial. *J Am Coll Cardiol*. 2015;66(21):2298-309.
57. Kimura T et al. A randomized trial evaluating everolimus-eluting Absorb bioresorbable scaffolds vs. everolimus-eluting metallic stents in patients with coronary artery disease: ABSORB Japan. *Eur Heart J*. 2015;36(47):3332-42.
58. Nakazawa G et al. Delayed arterial healing and increased late stent thrombosis at culprit sites after drug-eluting stent placement for acute myocardial infarction patients: an autopsy study. *Circulation*. 2008;118(11):1138-45.
59. Gonzalo N et al. Incomplete stent apposition and delayed tissue coverage are more frequent in drug-eluting stents implanted during primary percutaneous coronary intervention for ST-segment elevation myocardial infarction than in drug-eluting stents implanted for stable/unstable angina: insights from optical coherence tomography. *JACC Cardiovasc Interv*. 2009;2(5):445-52.
60. Räber L et al. Differential healing response attributed to culprit lesions of patients with acute coronary syndromes and stable coronary artery after implantation of drug-eluting stents: an optical coherence tomography study. *Int J Cardiol*. 2014;173(2):259-67.
61. Scalone G et al. ST-segment elevation myocardial infarction - ideal scenario for bioresorbable vascular scaffold implantation? *Circ J*. 2015;79(2):263-70.
62. Bourantas CV et al. Bioresorbable vascular scaffold treatment induces the formation of neointimal cap that seals the underlying plaque without compromising the luminal dimensions: a concept based on serial optical coherence tomography data. *EuroIntervention*. 2015;11(7):746-56.
63. Sabate M et al. Everolimus-eluting bioresorbable stent vs. durable polymer everolimus-eluting metallic stent in patients with ST-segment elevation myocardial infarction: results of the randomized ABSORB ST-segment elevation myocardial infarction-TROFI II trial. *Eur Heart J*. 2016;37(3):229-40.
64. Serruys PW. Comparison of the ABSORBTM everolimus eluting bioresorbable vascular scaffold system with a drug-eluting metal stent (XienceTM) in acute ST-elevation myocardial infarction: Results of TROFI II Study. Presented at the European Society of Cardiology (ESC) Congress, August 29-September 2 2015.
65. Serruys PW et al. Percutaneous coronary intervention versus coronary-artery bypass grafting for severe coronary artery disease. *N Engl J Med*. 2009; 360(10):961-72.
66. Serruys PW et al. 5-year clinical outcomes of the ARTS II (Arterial Revascularization Therapies Study II) of the sirolimus-eluting stent in the treatment of patients with multivessel de novo coronary artery lesions. *J Am Coll Cardiol*. 2010;55(11):1093-101.
67. Nef H et al. Evaluation of the short- and long-term safety and therapy outcomes of the everolimus-eluting bioresorbable vascular scaffold system in patients with coronary artery stenosis: Rationale and design of the German-Austrian ABSORB RegIstRy (GABI-R). *Cardiovasc Revasc Med*. 2016;17(1):34-7.
68. Hamm C. GABI-R: acute performance from German-Austrian real-world experience. Presented at: EuroPCR 2015, Paris, France, 19-22 May 2015.
69. Hamm C. Mid-term results from the GABI-R registry. Presented at: EuroPCR 2015 (European Association of Percutaneous Cardiovascular Interventions), Paris, France, 17-20 May, 2016.
70. Hernandez F. REPARA: acute performance from Iberian real-world experience. Presented at: EuroPCR 2015, Paris, France, 19-22 May 2015.
71. Gori T et al. Percutaneous coronary intervention with everolimus-eluting bioresorbable vascular scaffolds in routine clinical practice: early and midterm outcomes from the European multicentre GHOST-EU registry. *EuroIntervention*. 2015;10(10):1144-53.
72. Testa L et al. Italian Diffuse/Multivessel Disease ABSORB Prospective Registry (IT-DISAPPEARS). Study design and rationale. *J Cardiovasc Med (Hagerstown)*. 2015;16(3):253-8.
73. Abbott Vascular. Italian Diffuse/Multi-vessel Disease ABSORB Prospective Registry: IT-Disappears. *Clinical Trial*: NCT02004730. Available at: <https://clinicaltrials.gov/ct2/show/NCT02004730>.
74. Petronio AS. 30-day results of the Italian diffuse/multivessel disease ABSORB prospective registry (IT-DISAPPEARS). Presented at EuroPCR, 17 May 2016.
75. Kobayashi Y et al. Stented segment length as an independent predictor of restenosis. *J Am Coll Cardiol*. 1999; 34(3):651-9.
76. Suh J et al. The relationship and threshold of stent length with regard to risk of stent thrombosis after drug-eluting stent implantation. *JACC Cardiovasc Interv*. 2010;3(4):383-9.
77. Okumura M et al. Restenosis and stent fracture following sirolimus-eluting stent (SES) implantation. *Circ J*. 2007; 71(11):1669-77.
78. Colombo A, Latib A. Can long-term results following balloon angioplasty be the "crystal ball" to predict outcome following bioresorbable vascular scaffolds? *J Am Heart Assoc*. 2012;1(5):e005272.
79. Camacho Freire SJ et al. Feasibility and performance of everolimus-eluting bioresorbable vascular scaffolds (BVS) in long lesions (>25 mm): All-comers absorb registry with mid-term follow-up. *JACC*. 2015;66(15_S):B212.
80. Biscaglia S et al. Bioresorbable Scaffold vs. Second Generation Drug Eluting Stent in Long Coronary Lesions requiring Overlap: A Propensity-Matched Comparison (the UNDERDOGS study). *Int J Cardiol*. 2016;208:40-5.
81. Ojeda S et al. Outcomes and computed tomography scan follow-up of bioresorbable vascular scaffold for the percutaneous treatment of chronic total coronary artery occlusion. *Am J Cardiol*. 2015;115(11):1487-93.
82. Lipinski MJ et al. Scaffold Thrombosis After Percutaneous Coronary Intervention With ABSORB Bioresorbable Vascular Scaffold: A Systematic Review and Meta-Analysis. *JACC Cardiovasc Interv*. 2016; 9(1):12-24.
83. Stone GW et al. 1-year outcomes with the Absorb bioresorbable scaffold in patients with coronary artery disease: a patient-level, pooled meta-analysis. *Lancet*. 2016;387(10025):1277-89.
84. Kharlamov AN. Scaffold thrombosis: Exaggerated illusion, or when statistics rules. *Int J Cardiol*. 2016;209:206-9.