

RECENT ADVANCES IN SURGICAL AND PERCUTANEOUS MITRAL VALVE THERAPIES - IMPLICATIONS OF AN INTEGRATED APPROACH TO MITRAL REGURGITATION

*Lenard Conradi, Hendrik Treede, Hermann Reichenspurner

*University Heart Center Hamburg, Department of Cardiovascular Surgery,
University Medical Center, Hamburg-Eppendorf, Hamburg, Germany*

**Correspondence to lconradi@uke.de*

Disclosure: No potential conflict of interest.

Received: 02.03.14 **Accepted:** 22.05.14

Citation: EMJ Int Cardiol. 2014;1:44-51.

ABSTRACT

Surgical mitral valve (MV) repair has evolved to become the standard of care for severe mitral regurgitation (MR) with superior acute and long-term results compared to valve replacement. Minimally-invasive surgical techniques have been successful in reducing operative trauma while yielding equivalent or even superior results compared to conventional sternotomy. However, due to elevated operative risk, growing numbers of patients are not referred for surgery, especially elderly patients with reduced ventricular function and functional MR who often present with relevant comorbidities. For these patients, transcatheter-based therapies represent an attractive option. While most interventional techniques are still in experimental or early clinical stages, relevant clinical experience has been gathered with the MitraClip device. More recently, devices for transcatheter MV implantation have entered the clinical stage.

For successful implementation of an interdisciplinary MV programme, integration of surgical and interventional treatment modalities within heart centres is of paramount importance. This is best accomplished by an interdisciplinary heart team consisting of cardiologists and cardiac surgeons. An integrated approach to MV disease will help relieve under-treatment of patients with severe MR and will benefit a true heart centre as a whole by increasing the overall caseload of MV patients, as well as volumes and outcome of MV surgery by more adequate patient allocation for different treatment options.

Keywords: Mitral regurgitation, mitral valve repair, minimally-invasive, transcatheter mitral valve repair, MitraClip, heart team.

INTRODUCTION

Mitral regurgitation (MR) is among the most frequent entities in valvular heart disease, with a prevalence of 1.7% in Western societies. In patients >75 years, relevant MR, as defined by international guidelines, is present in approximately 10% of the population.^{1,2} Furthermore, due to increasing life expectancy and a growing prevalence of cardiovascular risk factors, increasing patient numbers, especially with functional MR and chronic heart failure, can be anticipated.³

Since the basic pathophysiological mechanism of MR was classified by Alain Carpentier⁴ in the 1980s, reconstructive MV surgery has been established as the gold standard treatment. By refinement of surgical techniques, mitral valve repair (MVR) can be performed with low perioperative risk and excellent long-term outcome.⁵ Minimally-invasive techniques (MITs) have reduced operative trauma and have become the standard-of-care at specialised centres.⁶ This expertise is the benchmark for any novel interventional approach. These less invasive approaches are urgently needed since a growing share of patients with

relevant MR are poor surgical candidates.⁷ It is for this growing population of high-risk patients that interventional MV therapies represent an adequate adjunct to surgical therapies.

SURGICAL MVR

Modern Surgical Techniques

MVR has proven superior compared to prosthetic valve replacement with regards to perioperative risk and long-term outcome.^{8,9} Therefore, MVR with preservation of the subvalvular apparatus has to be strived for whenever possible. Depending on the pathology, different surgical techniques are well established. Annuloplasty is indicated in almost every case. Annuloplasty rings allow for downsizing in case of annular dilatation or to stabilise additional valvuloplasty. Different rings are available depending on the individual pathology with the aim of restoring leaflet coaptation.

In degenerative MR, annuloplasty is usually complemented by valvuloplasty. While, in the past, resection of excessive leaflet tissue of the posterior mitral leaflet (PML) was frequently performed, today leaflet-sparing techniques with limited PML triangular resection and/or implantation of neochords are preferred. Neochords are anchored to the papillary muscles and sutured to the free edges of PML or anterior mitral leaflet (AML). By adjusting the length of the neochords, prolapse is corrected to the level of the annular plane.¹⁰

When correcting large prolapse, SAM phenomenon ('systolic anterior motion') can occur leading to systolic obstruction of the left ventricular (LV) outflow tract. A 'sliding plasty' can be performed to reduce the height of the PML to avoid SAM. Alternatively, dedicated annuloplasty rings with increased anterior-posterior diameter can be used.

The Alfieri-stitch is another technique that can be helpful in selected cases. Using a suture, free edges of PML and AML are connected at the origin of the regurgitant jet creating a 'double-orifice' of the MV.¹¹

Despite a large armamentarium of surgical reconstructive techniques, MVR is not always possible. If prosthetic valve replacement is indicated, preservation of the subvalvular apparatus is of paramount importance.¹²

Minimally Invasive Surgery

Beginning in the mid-1990s, MITs for MVR were developed. At specialised centres, minimally-invasive MVR via left antero-lateral minithoracotomy has become the standard access, suitable for a wide range of patients (Figure 1). Contraindications include severe pleural adhesions or pronounced atherosclerosis of peripheral vessels, precluding groin cannulation, and representing a risk of atheroembolism or aortic dissection during retrograde perfusion.

Patients are positioned with slight elevation of the right hemithorax. Via a 4-5 cm skin incision, access is gained through the fourth or fifth intercostal space. Cranial to the incision, an endoscope is inserted for videoscopic vision. Cross-clamping of the aorta is performed by a transthoracic clamp ('Chitwood clamp') or using the 'endo-clamp' technique. The latter technique can be helpful in 'redo cases' to avoid dissection of adhesions of the ascending aorta. Continuous insufflation of CO₂ minimises the risk of air embolisation. Implementation of extracorporeal circulation is achieved by cannulation of arteria and vena femoralis (Figure 1A). Access to the MV is gained via direct left atrial incision. Reconstructive techniques are identical to those used in sternotomy approaches.

Apart from isolated MVR, additional tricuspid valve repair, correction of atrial septal defects, extirpation of atrial myxoma, or atrial ablation for atrial fibrillation can also be performed via the minimally-invasive approach.

Clinical Results

Compared to the conventional sternotomy approach, several advantages have been shown when using MITs. A certain learning curve with initially prolonged operative times is usually without evident clinical consequences. Regarding acute as well as long-term outcome, minimally-invasive MV surgery is non-inferior to sternotomy approaches.¹³ In one of the largest published series operative mortality was 0.2% after minimally-invasive surgery compared to 0.3% after conventional MVR.¹⁴ Freedom from repeat MV surgery is similar after both approaches with rates above 90% up to 7 years of follow-up. Advantages of MITs were demonstrated regarding transfusion requirements, re-exploration for bleeding, postoperative ventilation times, or duration of hospital stay.

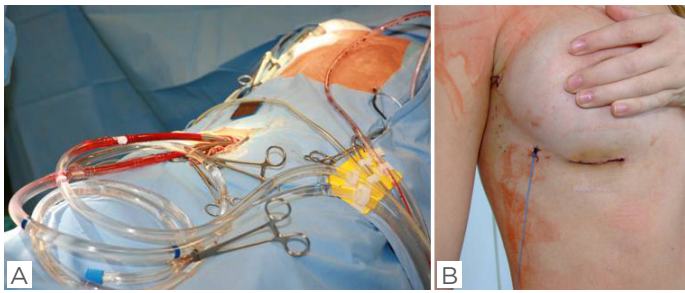


Figure 1: A) Implementation of extracorporeal circulation by cannulation of femoral vessels; B) result after minimally-invasive mitral valve repair via right antero-lateral minithoracotomy.

Also, less postoperative pain, quicker reconvalescence, and improved cosmesis (Figure 1B) speak in favour of minimally-invasive MVR.

After minimally-invasive MVR was introduced, concerns regarding increased incidence of cerebrovascular events were expressed. In a large current meta-analysis¹³ this effect was not found. In our own single-centre experience of >400 consecutive cases since 2001, no periprocedural stroke was observed. Routine use of the technique has allowed us to perform >80% of all isolated MV procedures by minimally-invasive access. Cardiopulmonary bypass times and aortic cross-clamp times are no longer different compared to the standard sternotomy technique. Finally, by reduced complication rates and shorter duration of hospital stay, minimally-invasive MVR can be performed cost-effectively.¹⁵

INTERVENTIONAL MVR

Even though surgical MVR is an established therapeutic concept for patients with relevant MR, a large proportion of patients are denied surgery. According to the European Heart Survey, only 50% of patients receive surgical treatment.⁷ This is true especially in patients of advanced age, reduced LV function, and relevant comorbidities. Furthermore, results after surgical MVR for functional MR are less favourable compared to degenerative MR. Surgical correction of secondary MR leads to some 'reverse remodelling' and moderate improvement of LV function.¹⁶ However, proof of survival advantage is pending.^{17,18} Recently, results of a multicentre study suggested non-inferiority of prosthetic MV replacement compared to MVR in patients with severe ischaemic MR

regarding LV remodelling. While MV replacement provided more durable results regarding recurrence of MR, no significant differences were found with respect to clinical endpoints. However, the trial was only powered to detect differences in the primary endpoint, i.e. reverse remodelling.¹⁹

A number of percutaneous approaches to MR have been developed. According to their mode of action, they can be categorised into systems meant for direct or indirect annuloplasty or for direct valvuloplasty.

Coronary Sinus (CS) Techniques

The anatomical proximity of the CS to the posterior aspect of the mitral annulus (MA) and the uncomplicated transvenous access have led to the development of different systems for indirect annuloplasty. The Carillon Mitral Contour System (Cardiac Dimensions®, Inc., Kirkland, WA, USA) consists of a central nitinol element connecting distal anchors and a proximal anchor. After transjugular access the anchoring portions are placed in the vena cordis magna and proximal CS. By stepwise foreshortening of the central element, the device allows for remodelling of the posterior periannular tissue.

Results of the prospective, multicentre AMADEUS trial (Carillon Mitral Annuloplasty Device European Union Study²⁰) have been published. Implantation of the device was successful in 30 of 48 patients (63%). In 18 patients implantation was impossible or the device was retracted due to dislocation, coronary artery compression, or failure to reduce MR. After successful implantation, 23% of patients had serious adverse events. At 6 months, clinical improvement by a mean of one New York Heart Association (NYHA) functional class was observed. The device carries Conformité Européenne (CE) mark.

The Monarc System (Edwards Lifesciences, Irvine, CA, USA) has self-expanding distal and proximal anchoring segments connected by a central spring. This spring is held under tension by resorbable spacers. During the first weeks following implantation, the central portion foreshortens successively and reduces septal-lateral circumference of the MA. 1-year data of the multicentre EVOLUTION-I trial²¹ have been published. In 82% of 72 patients, successful implantation was documented. In 30%, compression of coronary arteries was noted. The primary safety endpoint was reached by 91% and 82% at 30 days and 12 months, respectively.

In 50%, reduction of MR by ≥ 1 Grade was noted at 12 months. In light of these results, the device is no longer available.

The Viacor PTMA system (Percutaneous transvenous mitral annuloplasty; Viacor, Inc., Wilmington, MA, USA) is a multi-lumen catheter introduced through the subclavian vein. Nitinol rods of differing stiffness are introduced to cause anterior displacement of the posterior MA. As the proximal port of the multi-lumen catheter is left in an infraclavicular subcutaneous pouch, exchange of nitinol rods is possible at later time points. The PTOLEMY-I trial (Percutaneous transvenous mitral annuloplasty)²² has investigated clinical effects following implantation. Only 9 of 27 patients received permanent implants; 4 patients were followed until the end of the study, and all other patients experienced complications requiring surgical removal of the system. These results prompted the company to stop further development of the device.

Limitations of CS techniques

CS techniques have important limitations. Spatial relation of CS and MA is highly variable. This distance increases in patients with severe MR.^{23,24} From surgical literature it is known that annuloplasty needs to address posterior and

anterior MA, and annuloplasty rings need to be anchored at fibrous trigons. Systems inserted into the CS only compress the posterior aspect of the MA.²⁵ Finally, many patients do not qualify because, in up to 80%, circumflex artery compression may occur. Therefore, most CS approaches have been abandoned.

Direct Annuloplasty

Several devices for direct annuloplasty exist mimicking surgical annuloplasty. The issue of circumflex artery compression inherent with CS approaches is circumvented by these techniques. One of the devices with early clinical experience is the Valtech Cardio B (Valtech Cardio, Or Yehuda, Israel), which is delivered via a transvenous, transseptal route, and uses nitinol screws inserted into the atrial aspect of the MA in a commissure-to-commissure fashion. In a second step, a wire is tightened to allow for cinching of the annulus. Experimental and early clinical data have been presented.²⁶

The Mitralign system (Mitralign Inc., Tewksbury, Massachusetts, USA) delivers pledgets via a transventricular route and after puncture of the MA to the atrial aspect. Pledgets are cinched by a suture. A CE mark study is currently being pursued.²⁷

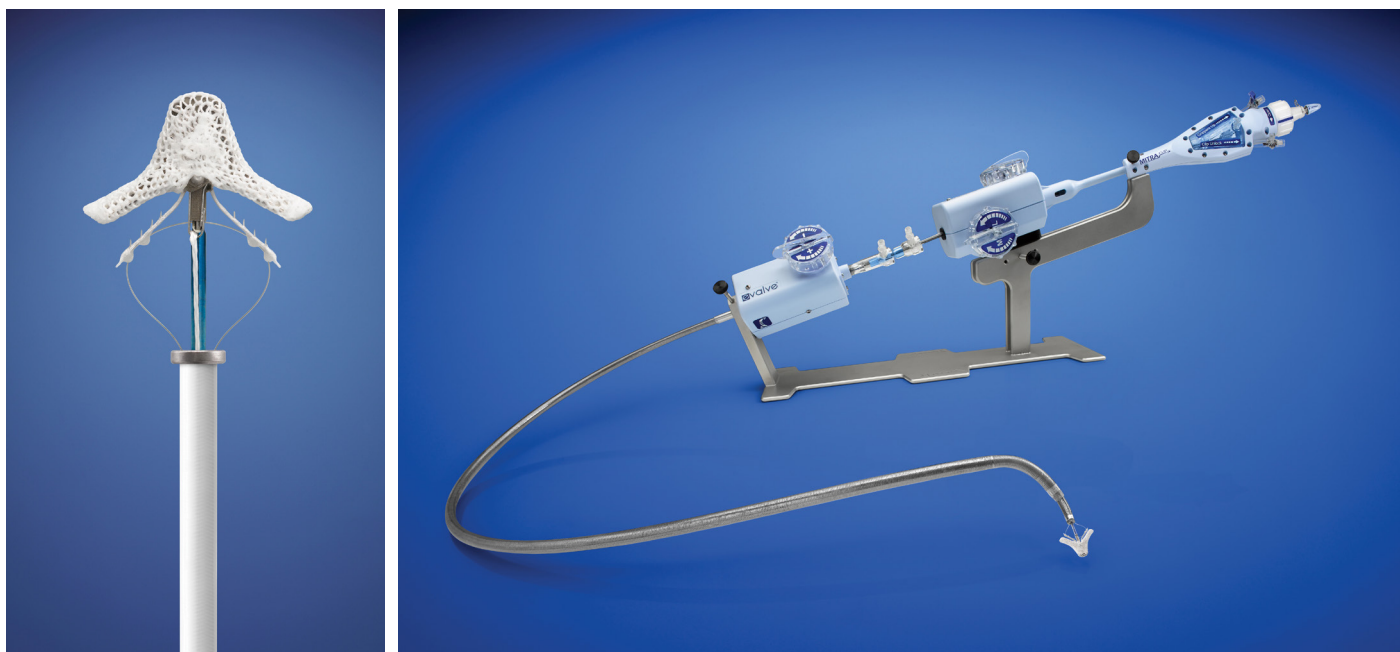


Figure 2: The MitraClip system consists of a polyester-covered cobalt-chromium clip. It represents the interventional extension of the surgical 'edge-to-edge' technique. *Reproduced from Abbott Vascular, Menlo Park, CA, USA.*

Interventional Edge-to-Edge Repair Technique

The MitraClip system (Abbott Vascular, Menlo Park, CA, USA) is a catheter-based extension of the surgical Alfieri technique.¹¹ The device consists of a polyester-covered cobalt-chromium clip (Figure 2). It is introduced by a 24 French (Fr) delivery catheter via the femoral vein into the right atrium and, after transeptal puncture, advanced into the left atrium. Under 2D and 3D echocardiographic and fluoroscopic guidance (Figure 3) the clip is positioned above the MV, opened, and advanced into the left ventricle. Subsequently, it is retracted so that the free edges of AML and PML are loaded onto the clip at the origin of the regurgitant jet; closure of the clip results in a 'double-orifice' MV (Figure 4).

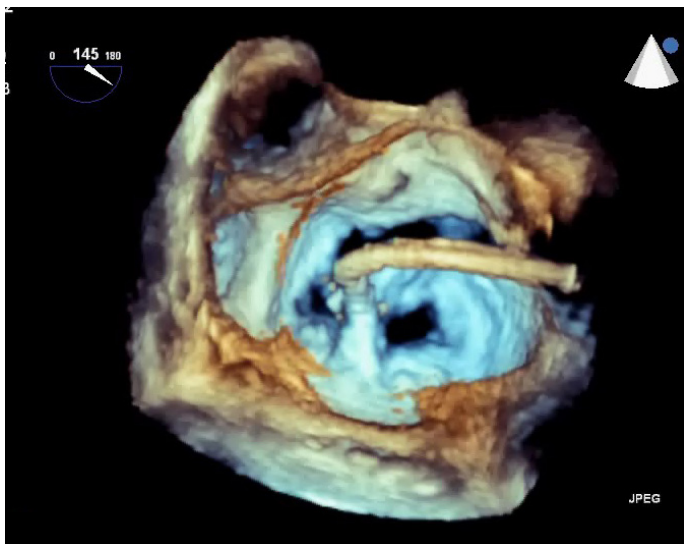


Figure 3: The MitraClip procedure requires optimal visualisation by 2D and 3D echocardiography.

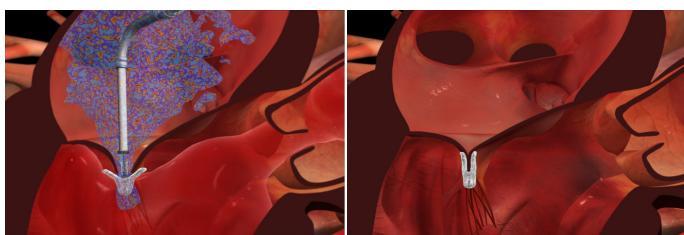


Figure 4: The MitraClip is introduced via the femoral vein and advanced to the right atrium. After transeptal puncture it is positioned above the mitral valve at the origin of the regurgitant jet and inserted into the left ventricle. By retraction of the clip, the free edges of mitral leaflets are loaded onto the clip arms. Closure of the clip results in approximation of the free leaflet edges.

Reproduced from Abbott Vascular, Menlo Park, CA, USA.

Before deployment, the clip can be opened and repositioned or completely retrieved. The implantation results are assessed under physiological haemodynamic conditions. One or more additional clips can be implanted if necessary.

Clinical results

The MitraClip system was initially evaluated in the EVEREST-I (Endovascular Valve Edge to Edge Repair Study) and EVEREST-II trials.^{28,29} Out of 107 patients, acute success with residual MR \leq Grade 2+ was noted in 74%. In 66% of successfully implanted patients, MR was \leq Grade 2+ at 12 months. Severe adverse events were documented in 9% at 30 days. Randomisation for the EVEREST-II trial allocated 279 patients in a 2:1 ratio to MitraClip or surgery.³⁰ Degenerative MR was present in 73% of cases. Primary efficacy endpoint was defined as survival, freedom from reoperation, and freedom from MR \geq Grade 2+ at 12 months, and it was reached in 55% of interventional and 73% of surgical patients in an intent-to-treat analysis ($p=0.007$). The combined safety endpoint (incidence of severe adverse events to 30 days) was reached in 15% of interventional and 48% of surgical patients ($p<0.001$), even though transfusion of ≥ 2 units represented the majority of adverse events. Excluding transfusion, no significant difference in safety was seen ($p=0.23$). In both interventional and surgical cohorts, ventricular remodelling, improved NYHA functional class, and improved quality of life were noted. It has to be emphasised that 20% of MitraClip patients underwent secondary MV surgery. In 46% of interventional patients MR was \geq Grade 2+ at 12 months. Further follow-up resulted in MitraClip FDA approval in October, 2013. Efficacy of the MitraClip device is currently evaluated in randomised controlled trials against best medical therapy in the COAPT (ClinicalTrials.govID:NCT01626079) and RESHAPE-HF (ClinicalTrials.govID:NCT01772108) trials.

Extensive real-world experience with the MitraClip system exists in Europe. The first-in-Europe implantation was performed at the University Heart Center in Hamburg, Germany, in January, 2008. In an interim analysis of 51 patients,³¹ marked reduction of MR and an excellent safety profile of the procedure was documented. Until January 2014, >500 patients have been treated. This represents the world's largest single-centre experience. Meanwhile 2-year data of 202 successfully treated patients (74 \pm 9 years, 65%

male, logEuroSCORE I 25[16-43]%) from our centre have been reported.³² 140 patients were treated for secondary MR, while primary MR was present in 62 patients. Freedom from MR \geq Grade 2+ was 89% at 2 years.

Transapical Implantation of Neochordae

A novel device for transapical implantation of neochordae has been evaluated clinically, and recently, received CE mark (NeoChord DS1000, NeoChord Inc., Minneapolis, Minnesota, USA). Via standard transapical access, the delivery catheter is inserted into the left ventricle. Under 2D and 3D echocardiographic guidance, the free edge of the prolapsing segment of PML or AML are grasped. Colour-sensitive fibre optics ensure grasping of sufficient leaflet tissue. Neochordae are subsequently externalised through the LV apex and fixed at adequate length under echo guidance. Clinical feasibility and safety have recently been demonstrated in the Transapical Artificial Chordae Tendineae (TACT) trial and further evaluation is being pursued in a post-market registry at present.³³

COMMENTARY

Refinement of reconstructive techniques has made surgical MVR the reference treatment for patients with relevant MR. Surgery can be performed with low perioperative complication rates and excellent long-term outcomes. Therefore, surgery may also be justified in asymptomatic patients. In Germany, rates of MVR as compared to prosthetic valve replacement have constantly increased.³⁴ MIT have further improved surgical results and have become the standard of care at specialised centres.

Many interventional treatment strategies for MR have been pursued in the past. However, only the MitraClip system has extensive clinical experience. For patients with elevated surgical risk due to advanced age, reduced LV function, and/or relevant comorbidities it represents an adequate alternative. In a recent analysis, we found that interventional and surgical patients differ fundamentally.³⁵ Interventional patients had significantly higher overall clinical risk profiles compared to surgical patients ($p < 0.001$). Also, MR was of functional or mixed aetiology in 25.3% of surgical compared to 77.8% in interventional patients ($p < 0.001$). While surgery was significantly more likely to reduce MR to

\leq Grade 2+ compared to MitraClip treatment ($p = [\text{log rank}] < 0.001$), risk-adjusted survival was not significantly different at 6 months between the two modalities ($p = 0.642$).

In the years following the introduction of an interventional MV programme at our centre, surgical MV activity has increased.³⁶ This increase in surgical caseload amounted to 32.2% from 2007-2012, and it was well above the national background, which showed an increase in caseload during the same timeframe of 10.2%.³⁷ The overall caseload of interventional and surgical MV patients increased by 71.3% from 2007-2012. In summary, it seems likely that in addition to some crossover of patients initially considered for surgery but then deemed to be high-risk, MitraClip patients stem mainly from an 'on-top recruitment' process. Thus, addition of a MitraClip programme likely relieved undertreatment of patients with relevant MR.

Regarding risk profiles of surgical patients there were also several changes since implementation of a MitraClip programme. Although mean logEuroSCORE I of surgical patients remained unchanged, risk profile decreased significantly regarding several important parameters, such as presence of ischaemic MR, coronary artery disease, status post myocardial infarction, or status post previous cardiac surgery (all $p < 0.01$). In parallel, the adjusted MVR rate (excluding cases of MV stenosis or severe MV endocarditis) increased from 80-89% ($p = 0.02$), while 30-day mortality decreased from 7.2-4.2% ($p = 0.22$) for all MV patients. For isolated MVR, 30-day mortality was 1.5% (6/406 patients) in all patients during the study period. The trend of improved surgical outcomes may be explained by more adequate patient selection.

Recently, MitraClip therapy has been incorporated into international guidelines for treatment of primary or secondary MR in inoperable or high-risk patients.² Patient selection, performance of the procedure, and post-procedural care should be performed by an interdisciplinary team of cardiologists and cardiac surgeons.

FUTURE PERSPECTIVES

For the future, an increasing clinical relevance of endovascular therapies for treatment of MR can be anticipated. New devices for repair are entering the clinical stage for specific subsets of patients.

Even more recently, very early clinical experience has been gathered with devices for transapical or transatrial transcatheter MV implantation, such as the Neovasc Tiara (Neovasc Inc., Richmond, BC, Canada), the Fortis (Edwards Lifesciences, Inc., Irvine, CA, USA), or the CardiAQ device (CardiAQ Valve Technologies, Inc., Irvine, CA, USA). These new devices have the conceptual advantages of potentially abolishing MR altogether without risk of recurrence. Also, treatment of multiple aetiologies of MR by one device seems possible.

In summary, the field of transcatheter MV therapies is quickly evolving with multiple new

repair and replacement strategies in early clinical use. At present, all devices have to be restricted to inoperable patients or to compassionate use settings. However, once clinical proof of safety and efficacy has been demonstrated, extension to a broader patient spectrum seems likely. For a successful clinical programme, an interdisciplinary heart team of multiple specialities, but mandatorily including cardiologists and cardiac surgeons, is needed to ensure optimal patient care and careful evaluation of new techniques against the current surgical gold standard.

REFERENCES

- Nkomo VT et al. Burden of valvular heart diseases: a population-based study. *Lancet*. 2006;368(9540):1005-11.
- Vahanian A et al. Guidelines on the management of valvular heart disease (version 2012): the Joint Task Force on the Management of Valvular Heart Disease of the European Society of Cardiology (ESC) and the European Association for Cardio-Thoracic Surgery (EACTS). *Eur Heart J*. 2012;33(19):2451-96.
- Rosamond W et al. Heart disease and stroke statistics--2008 update: a report from the American Heart Association Statistics Committee and Stroke Statistics Subcommittee. *Circulation*. 2008;117(4):e25-146.
- Carpentier A. Cardiac valve surgery - the "French correction". *J Thorac Cardiovasc Surg*. 1983;86(3):323-37.
- David TE et al. Late outcomes of mitral valve repair for floppy valves: implications for asymptomatic patients. *J Thorac Cardiovasc Surg*. 2003;125(5):1143-52.
- Conradi L et al. Minimally-invasive mitral valve surgery: evolution of the technique to the standard of care for mitral repair. *Thorac Cardiovasc Surg*. 2010;58(Suppl 1):S119.
- Mirabel M et al. What are the characteristics of patients with severe, symptomatic, mitral regurgitation who are denied surgery? *Eur Heart J*. 2007;28(11):1358-65.
- Lawrie GM. Mitral valve repair vs replacement. Current recommendations and long-term results. *Cardiol Clin*. 1998;16(3):437-48.
- Mohty D et al. Very long-term survival and durability of mitral valve repair for mitral valve prolapse. *Circulation*. 2001;104(12 Suppl 1):11-7.
- Perier P et al. Toward a new paradigm for the reconstruction of posterior leaflet prolapse: midterm results of the "respect rather than resect" approach. *Ann Thorac Surg*. 2008;86(3):718-25.
- Alfieri O et al. The double-orifice technique in mitral valve repair: a simple solution for complex problems. *J Thorac Cardiovasc Surg*. 2001;122(4):674-81.
- David TE et al. Left ventricular function after mitral valve surgery. *J Heart Valve Dis*. 1995;4 Suppl 2:S175-80.
- Modi P et al. Minimally invasive mitral valve surgery: a systematic review and meta-analysis. *Eur J Cardiothorac Surg*. 2008;34(5):943-52.
- Mihaljevic T et al. One thousand minimally invasive valve operations: early and late results. *Ann Surg*. 2004;240(3):529-34.
- Reichenspurner H et al. Video and robotic-assisted minimally invasive mitral valve surgery: a comparison of the Port-Access and transthoracic clamp techniques. *Ann Thorac Surg*. 2005;79(2):485-90.
- Bach DS, Bolling SF. Improvement following correction of secondary mitral regurgitation in end-stage cardiomyopathy with mitral annuloplasty. *Am J Cardiol*. 1996;78(8):966-9.
- Wu AH et al. Impact of mitral valve annuloplasty on mortality risk in patients with mitral regurgitation and left ventricular systolic dysfunction. *J Am Coll Cardiol*. 2005;45(3):381-7.
- Mihaljevic T et al. Impact of mitral valve annuloplasty combined with revascularization in patients with functional ischemic mitral regurgitation. *J Am Coll Cardiol*. 2007;49(22):2191-201.
- Acker MA et al. Mitral-valve repair versus replacement for severe ischemic mitral regurgitation. *N Engl J Med*. 2014;370:23-32.
- Schofer J et al. Percutaneous mitral annuloplasty for functional mitral regurgitation: results of the CARILLON Mitral Annuloplasty Device European Union Study. *Circulation*. 2009;120(4):326-33.
- Harnek J et al. Transcatheter implantation of the MONARC coronary sinus device for mitral regurgitation: 1-year results from the EVOLUTION phase I study (Clinical Evaluation of the Edwards Lifesciences Percutaneous Mitral Annuloplasty System for the Treatment of Mitral Regurgitation). *JACC Cardiovasc Interv*. 2011;4(1):115-22.
- Sack S et al. Percutaneous transvenous mitral annuloplasty: initial human experience with a novel coronary sinus implant device. *Circ Cardiovasc Interv*. 2009;2(4):277-84.
- Choure AJ et al. In vivo analysis of the anatomical relationship of coronary sinus to mitral annulus and left circumflex coronary artery using cardiac multidetector computed tomography: implications for percutaneous coronary sinus mitral annuloplasty. *J Am Coll Cardiol*. 2006;48(10):1938-45.
- Tops LF et al. Noninvasive evaluation of coronary sinus anatomy and its relation to the mitral valve annulus: implications for percutaneous mitral annuloplasty. *Circulation*. 2007;115(11):1426-32.
- Lansac E et al. Percutaneous mitral annuloplasty through the coronary sinus: an anatomic point of view. *J Thorac Cardiovasc Surg*. 2008;135(2):376-81.
- Maisano F et al. Direct access transcatheter mitral annuloplasty with a sutureless and adjustable device: preclinical experience. *Eur J Cardiothorac Surg*. 2012;42:524-9.
- Mandinov L et al. Early insight into Mitralign direct annuloplasty for treatment of functional mitral regurgitation. *Interventional Cardiology*

Review. 2011;6:170-2.

28. Feldman T et al. Percutaneous mitral valve repair using the edge-to-edge technique: six-month results of the EVEREST Phase I Clinical Trial. *J Am Coll Cardiol.* 2005;46(11):2134-40.

29. Feldman T et al. Percutaneous mitral repair with the MitraClip system: safety and midterm durability in the initial EVEREST (Endovascular Valve Edge-to-Edge REpair Study) cohort. *J Am Coll Cardiol.* 2009;54(8):686-94.

30. Feldman T et al. Percutaneous repair or surgery for mitral regurgitation. *N Engl J Med.* 2011;364(15):1395-406.

31. Franzen O et al. Acute outcomes of MitraClip therapy for mitral regurgitation in high-surgical-risk patients: emphasis

on adverse valve morphology and severe left ventricular dysfunction. *Eur Heart J.* 2010;31(11):1373-81.

32. Rudolph V et al. Aetiology of mitral regurgitation differentially affects 2-year adverse outcomes after MitraClip therapy in high-risk patients. *Eur J Heart Fail.* 2013;15(7):796-807.

33. Seeburger J et al. Off-pump transapical implantation of artificial neo-chordae to correct mitral regurgitation: the TACT trial (Transapical Artificial Chordae Tendinae) proof of concept. *J Am Coll Cardiol.* 2014;63:914-9.

34. Beckmann A et al. Cardiac surgery in Germany during 2012: a report on behalf of the German Society for Thoracic and Cardiovascular Surgery. *Thorac*

Cardiovasc Surg. 2014;62(1):5-17.

35. Conradi L et al. Surgical or percutaneous mitral valve repair for secondary mitral regurgitation: comparison of patient characteristics and clinical outcomes. *Eur J Cardiothorac Surg.* 2013;44(3):490-6.

36. Conradi L et al. Towards an integrated approach to mitral valve disease: implementation of an interventional mitral valve programme and its impact on surgical activity. *Eur J Cardiothorac Surg.* 2013;44(2):324-8.

37. Funkat AK et al. Cardiac Surgery in Germany during 2011: a report on behalf of the German Society for Thoracic and Cardiovascular Surgery. *Thorac Cardiovasc Surg.* 2012;60(6):371-82.