

USE OF ULTRASOUND FOR DIAGNOSIS AND FOLLOW-UP OF PSORIATIC ARTHRITIS

Rusmir Husic,¹ Anja Ficjan,¹ Christina Duftner,² *Christian Dejaco¹

1. Division of Rheumatology and Immunology, Medical University Graz, Graz, Austria

2. Department of Internal Medicine VI, Medical University Innsbruck, Innsbruck, Austria

*Correspondence to christian.dejaco@gmx.net

Disclosure: No potential conflict of interest.

Received: 01.04.14 **Accepted:** 09.05.14

Citation: EMJ Rheumatol. 2014;1:65-72.

ABSTRACT

Musculoskeletal ultrasound (US) is increasingly used as a bedside tool for diagnostic and monitoring purposes in patients with psoriatic arthritis (PsA). The sonographic differentiation between PsA and rheumatoid arthritis (RA) may be challenging because the morphological appearance of synovitis is similar in both conditions. In contrast, perisynovial inflammation is a specific finding of early PsA, and enthesitis is more frequently detected in PsA than in RA. After initiation of effective therapies, a reduction of US signs of synovitis and enthesitis can be seen along with clinical improvement. A numeric US score for regular monitoring of disease activity and damage in PsA patients has not been established yet. While sonographic findings can be discordant from clinical results, their relevance is unclear, although it is a concern that ongoing subclinical inflammation results in worse structural outcomes. Ongoing studies address the value of sonography as a diagnostic and prognostic marker in PsA, and we expect that these results will emphasise the role of diagnostic US for the routine evaluation of PsA patients.

Keywords: Psoriatic arthritis, ultrasonography, disease activity, spondyloarthritis.

INTRODUCTION

Psoriatic arthritis (PsA) belongs to the group of seronegative spondyloarthropathies and is characterised by inflammation of joints, tendons, and/or entheses associated with psoriatic skin and/or nail lesions.¹ Clinical presentation and clinical course are highly variable, ranging from subtle pain at tendon insertions to mutilating arthritis, from monoarthritis to a 'rheumatoid arthritis (RA)-like' polyarticular phenotype, or from mild spinal inflammation to frank ankylosing spondylitis.² As PsA usually arises in patients with preexisting psoriasis, clinicians have the unique opportunity to screen a defined population (namely patients with psoriasis) in order to identify arthritic patients at an early stage.³

Unfortunately, there are no specific laboratory markers for the disease, and conventional radiography is of limited value for early diagnosis.³ Imaging techniques such as magnetic resonance

imaging (MRI) or musculoskeletal ultrasound (US) are new attractive tools supporting diagnostic and management decisions in PsA.² Sonography has the advantage over MRI of being widely available, having no contraindications, a higher resolution, and causing lower costs. On the other hand, some anatomical locations cannot be judged, and intraosseous lesions, such as bone marrow oedema, cannot be detected by sonography.⁴

Clinical Diagnosis and Overlap of PsA with Other Diseases

For diagnosis of PsA the classification criteria for psoriatic arthritis (CASPAR) are commonly applied, although these criteria were primarily developed for classification of patients in clinical studies.⁵ The diagnostic work-up of PsA patients may further be challenged by a clinical overlap with other diseases. Patients with psoriasis and polyarthritis, for example, may simultaneously fulfil the CASPAR criteria for PsA, and the 2010

American College of Rheumatology/European League Against Rheumatism (ACR/EULAR) criteria for RA.^{5,6} The correct diagnosis, however, has fundamental implications on initial and subsequent treatment strategies; EULAR recommendations suggest the use of non-steroidal anti-inflammatory drugs (NSAIDs) as a first-line treatment in PsA, whereas RA patients are initially treated with conventional synthetic disease-modifying anti-rheumatic drugs (DMARDs), such as ethotrexate.^{7,8} Besides, there are more biologic agents approved for RA than for PsA.

Similarly, patients with distal interphalangeal (DIP) joint arthritis and bony thickening may be either classified as PsA or osteoarthritis (OA) and again, treatment of these two conditions is fundamentally different.⁹ Whether sonography may help to differentiate overlapping conditions in patients with psoriasis will be discussed in the following sections.

THE ROLE OF US IN PSA

Detection of Inflammatory and Structural Lesions in PsA

There is now clear evidence that US has a high sensitivity and specificity to detect inflammatory lesions in patients with rheumatic diseases.⁴ The new EULAR recommendations on the use of imaging methods in RA emphasised the possibility that sonography may be used to confirm the clinical finding of an 'involved' joint for the purpose of classifying patients with at least one joint with definite clinical synovitis.¹⁰ One study in patients with very early arthritis suggested that US investigations may shift the diagnosis from monoarthritis to oligoarthritis or polyarthritis; the addition of sonographic findings to the 2010 CR/EULAR criteria increased the number of patients also fulfilling the 1987 ACR criteria after an 8-month follow-up period.¹¹

In PsA, US studies have focused on the examination of peripheral joints and entheses (see **Figure 1** for examples), although there was also some interest in the examination of sacroiliac joints.²

PsA Associated Arthritis

Similar to the reports in RA, US revealed synovial inflammation more commonly than clinical examination; sonography was useful to exclude arthritis particularly in painful large joints.¹²⁻¹⁴ Besides, the majority of PsA patients with clinically

suspected oligoarthritis were reclassified as having polyarthritis based on the US result.^{12,13} For structural lesions in hands, US and MRI were more sensitive than X-ray examination, and when comparing sonography with MRI, the former identified more osteophytes in small joints and erosions in proximal interphalangeal (PIP) joints, whereas the latter performed better for detection of erosions in metacarpophalangeal (MCP) and DIP joints.¹⁴

PsA Associated Enthesitis

Several studies evaluated the relevance of US for the diagnosis of enthesitis in patients with established spondylarthritis (including PsA patients) revealing an overall better performance of sonography to identify inflammatory lesions as compared to clinical examination.^{15,16} In patients with early or new onset PsA, US was also useful to exclude active inflammation at some tender entheses.^{17,18}

US of Sacroiliac Joints

Sacroiliac joint US was found to have a moderate-to-good sensitivity for diagnosis of spondylarthritis. However, this method is nevertheless of limited value because of the small acoustic window at sacroiliac joints, and because of the fact that bone marrow oedema, the most important sign of spondyloarthritis, cannot be detected by sonography.¹⁹⁻²³

US Findings in PsA Associated Dactylitis

US changes in dactylitis have been reported controversially in the literature.²⁴ The combination of arthritis and tenosynovitis was deemed as the underlying pathology of dactylitis in earlier publications, whereas recent US studies indicate that isolated tenosynovitis is the most common US abnormality, and arthritis occurs in only half of cases.^{24,25} Recent MRI studies further suggest that soft-tissue oedema and/or collateral tendon enthesitis are characteristic findings of dactylitis.²⁶ A project of the Outcome Measures in Rheumatology (OMERACT) is currently underway to agree upon an US definition of dactylitis.²⁴

US of Skin and Nails

US has been used to investigate skin and nail lesions in patients with psoriasis. In B-mode, a psoriatic lesion is characterised by a thickened dermis and epidermis; Power Doppler (PD) may show increased blood flow within the dermis.

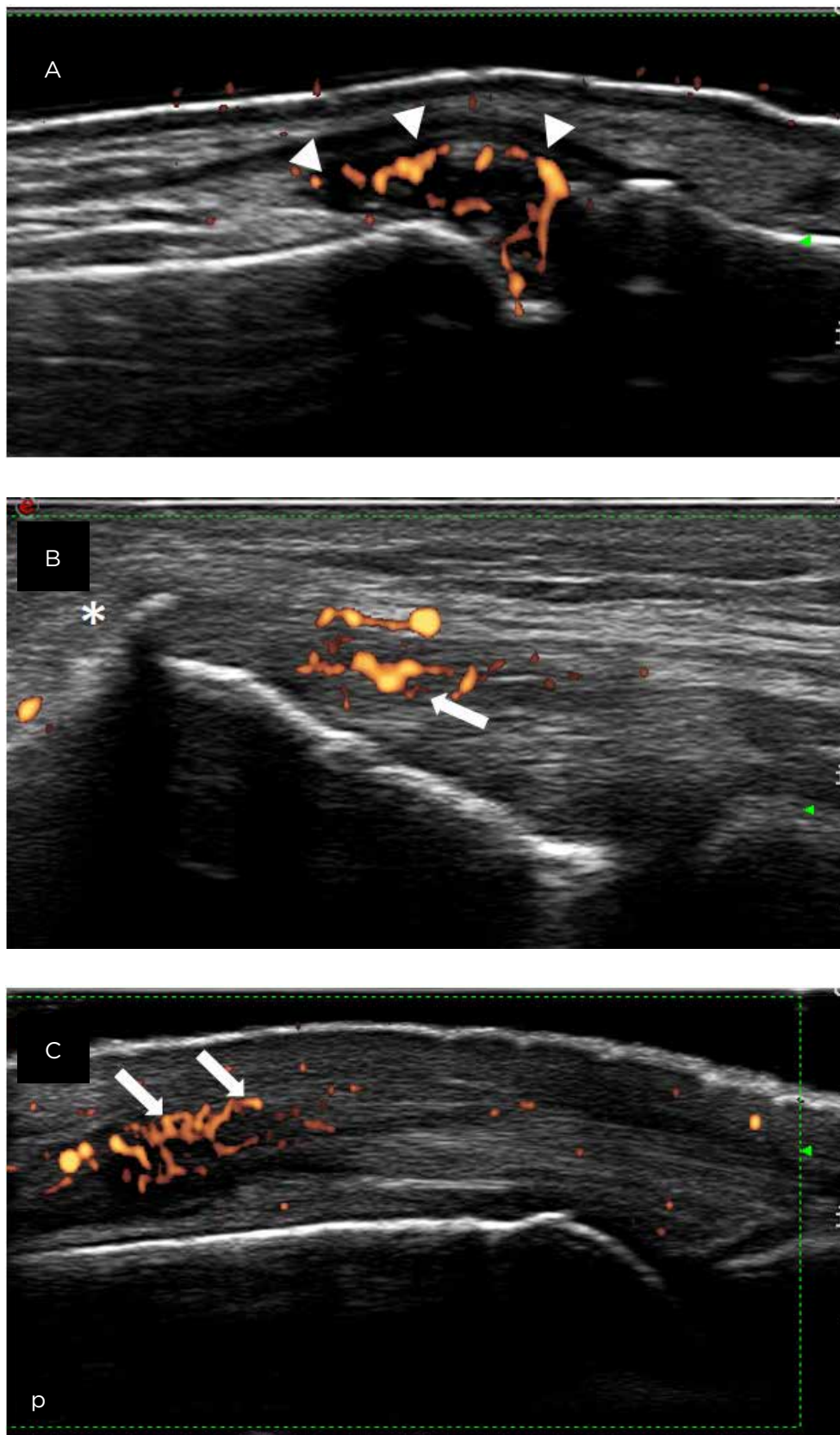


Figure 1: Examples of ultrasound findings in psoriasis arthritis (PsA).

A) Longitudinal dorsal scan of a distal interphalangeal joint from a PsA patient. Arrowheads indicate active synovitis with extensive Power Doppler (PD)-signals; joint space is marked with an asterisk. B) Longitudinal scan of the lateral epicondyle from a PsA patient with enthesitis. Arrows indicate PD-signals within the enthesitis and the open arrow marks an enthesophyte. C) Longitudinal dorsal scan of a metacarpophalangeal joint revealing active perisynovitis (arrows). Synovia are indicated by arrowheads and joint space by an asterisk. p: proximal.

In patients with psoriatic onychopathy, US reveals hyperechoic parts and/or a loss of definition of nail plates. At later stages, a wavy or thickened appearance of plates with or without increased blood flow in the nail bed may be visible.²⁷

DIFFERENTIATION OF PSA FROM CLINICALLY OVERLAPPING CONDITIONS

PsA and RA

Despite the fact that synovial tissue samples have suggested a difference in the histopathology of PsA and RA tissue,²⁸ joint synovitis from PsA and RA patients appears to be indistinguishable by means of MRI or US investigations.^{14,29,30} In contrast, extrasynovial inflammatory changes are deemed as characteristic findings of PsA.^{13,30} An MRI study of hands, for example, reported periarticular inflammation in small finger joints, particularly in collateral ligaments and periarticular soft tissue in PsA but not RA patients.³¹ An Italian US study found that perisynovitis, an extensor peri-tendon inflammation at MCPs, is a specific pathology for patients with early PsA.³² In patients with shoulder pain, synovitis at the acromioclavicular joint suggested underlying PsA, whereas glenohumeral joint effusion was the most common finding in RA patients.³³

The presence and extent of US-verified enthesitis was useful to distinguish PsA from RA in one study,³⁴ whereas in another study clinical but not US scores of enthesitis were greater in PsA compared to RA patients.³⁵ RA patients from the latter study, however, were older and had a longer disease duration possibly affecting the result toward similar US findings in both groups.

The number and size of US-verified erosions at wrists, MCPs, PIPs, and metatarsophalangeal (MTP) joints may help to differentiate PsA from RA and OA. RA patients had generally more and larger erosions than PsA patients and the number and size of erosions was larger in PsA than in OA.³⁶ Besides, we know from a micro-computed tomography study that erosions in PsA are mostly Ω -shaped and tubule-shaped, whereas U-shaped lesions are characteristically found in RA.³⁷ Unfortunately, the morphology of erosions cannot be determined reliably by sonography because the overlying intact bone limits the acoustic window. Osteophytes were generally increased in number, extent, and size in PsA compared to RA,

often affecting the entire circumference of the bone (so called 'bony corona').³⁷

PsA and OA

DIP joint involvement belongs to the most characteristic manifestations of PsA.¹ Differentiation of PsA-related DIP arthritis and (activated) OA, however, might be challenging. In an MRI study comparing DIP joints affected by PsA or OA, enthesal and ligament enhancement, extracapsular changes, and diffuse bone oedema were more commonly observed in PsA than in OA.³⁸ Differentiation of the two conditions by MRI in individual cases, however, was limited because none of the items were specific enough for a reliable diagnosis.

PsA and Psoriasis

The Madrid Sonographic Enthesitis Index (MASEI) was used to distinguish between patients with PsA and psoriasis (without arthritis), revealing higher inflammatory and damage subscores in the former group compared to the latter. A MASEI ≥ 20 had a specificity of 90% to correctly classify PsA patients.³⁹ Another study showed that subclinical enthesitis in PsA is linked with more PD signals than subclinical enthesitis in psoriasis.⁴⁰

Subclinical synovitis and enthesitis was more commonly observed in patients with psoriasis than in healthy individuals, particularly in cases with psoriatic nail disease.^{17,41-44} The relevance of this finding for patients' outcome is elusive so far as only a small study suggested that US-verified subclinical enthesitis in patients with psoriasis might predict later onset of PsA.⁴⁵

CLINICAL AND SONOGRAPHIC MONITORING OF PSA PATIENTS

Association between Clinical Composite Scores and US Findings

Regular measurement of disease activity and adjustment of therapy targeted at remission are important principles of current EULAR guidelines and 'treat to target' recommendations for PsA.^{7,46} In routine practice and clinical trials, PsA disease activity is usually measured with tools 'borrowed' from RA.⁴⁶ Recently, new PsA specific composite scores have been proposed; the Disease Activity Index for Psoriatic Arthritis (DAPSA) combines the number of tender (TJ) and swollen joints (SJ),

patients' pain, and global assessment, as well as the C-reactive protein (CRP) level,⁴⁷ whereas the Composite Psoriatic Disease Activity Index (CPDAI) corroborates PsA specific domains including joint disease, enthesitis, dactylitis, and skin and axial manifestations, as well as quality of life (QoL).⁴⁸ As part of the GRACE (GRAPPA Composite Index Exercise) project, the Psoriatic Arthritis Disease Activity Score (PASDAS) was developed based on the combination of TJ, SJ, global assessments, enthesitis, dactylitis, QoL, and CRP.⁴⁹

None of these new scores, however, has been validated sufficiently so far, and only one study compared the DAPSA and CPDAI with sonography - reporting a considerable disparity between clinical and US results.⁵⁰ In this study, the correlation between clinical examination and US was better in joints compared to other PsA manifestations, and the joint-focused DAPSA performed better to identify patients with US-verified active disease than the multifactorial CPDAI.⁵¹ US-verified enthesitis, dactylitis, tenosynovitis, and perisynovitis were not reflected by clinical parameters.

US as a Tool to Measure Disease Activity in Follow-up Studies

In contrast to the large number of studies investigating the value of sonography for follow-up of RA patients,⁴ a few studies have been performed in PsA so far. One study reported that sonography was helpful to monitor the improvement of knee synovitis in PsA and RA patients treated with etanercept;⁵¹ a retrospective study observed a decrement of both US and clinical signs of inflammation in PsA patients treated with adalimumab,⁵² and a prospective multicentre Spanish study found improvements in sonographic and clinical scores after infliximab therapy.⁵³ In a trial aimed at the validation of the Sonography of Large joints in Rheumatology (SOLAR) score, 126 PsA or AS patients were investigated before and after instigation of conventional synthetic or biologic DMARD therapy.⁵⁴ Grey-scale and PD scores of all joint areas exhibited a significant improvement at follow-up.

The responsiveness of US-verified enthesitis to anti-TNF- α therapy was tested in a large Spanish study involving 35 centres. Naredo et al.⁵⁵ investigated 197 patients with spondyloarthritis including 34 (17%) PsA patients. B-mode abnormalities and PD signals were reduced after therapy, whereas

structural changes such as calcific deposits and cortical abnormalities were not responsive to treatment. Similar observations were made in another study focusing on the Achilles tendon.⁵⁶

Latest US developments also allow for the detection of dermal perfusion changes in patients with psoriatic plaques.⁵⁷ In patients receiving TNF- α blocking therapy, a significant correlation between changes of PD, Psoriasis Area and Severity Index (PASI), and the histologically-determined number of blood vessels within psoriatic lesions was observed.⁵⁸

Remission Assessment in PsA

Although remission is the overarching therapeutic goal in PsA, a definition of clinical remission has not been established so far.⁷ Criteria for minimal disease activity (MDA) were recently validated in two prospective PsA cohorts and were useful to distinguish between patients at high and low risk of radiographic progression.⁵⁹⁻⁶¹ Complete abrogation of structural damage, however, was not achieved despite MDA, and it is concerning that the presence of subclinical inflammation, as observed in a considerable proportion of patients, may be linked with structural deterioration.⁵⁰ A similar concept is currently discussed for RA, but future studies are necessary to test the possible link between US-verified inflammation and radiographic outcomes in both RA and PsA.⁴

US Composite Scores in PsA

In clinical studies and/or routine practice, US composite scores may be applied for a regular sonographic scoring. In RA, several scoring systems have been proposed, whereas in PsA only two US composite scores have been evaluated so far.⁶²⁻⁶⁶ The Italian 'Five Targets Power Doppler for Psoriatic Disease (5TPD)' US score focuses on 'five targets' (joints, tendons, entheses, skin, and nails) and revealed adequate sensitivity to change in the short-term follow-up of anti-TNF- α therapy. However, as only one anatomical site was investigated for each target, this score is of limited value to determine actual disease activity.

The German US7 score was primarily developed for RA and was only later tested in a small group of PsA patients.^{62,65} In RA, the US7 score better reflected the extent of joint inflammation than the DAS28. For PsA, this score is of limited value because of the omission of enthesitis and DIP arthritis, which are important PsA manifestations.

We therefore need a new US composite score that includes all important PsA manifestations, is sensitive, reliable, and feasible in clinical routine.

PROGNOSTIC VALUE OF US IN PSA

Treatment decisions in rheumatology are usually based on prognostic factors predicting clinical, structural, and functional outcomes as well as treatment success. In RA, high disease activity state, autoantibody positivity (rheumatoid factor and/or antibodies to citrullinated proteins), and the early presence of joint damage are associated with a high risk of rapid radiologic damage.^{67,68} Similarly, we know that in PsA a high clinical disease activity, radiographic progression, functional limitations, elevated acute phase reactants, and previous corticosteroid therapy are predictors of a worse outcome.^{8,69}

US for Prediction of Disease Flare and Structural Deterioration

Several studies investigated the prognostic value of sonography in RA, whereas, the number of such studies in PsA is scarce. In RA patients with clinical remission for example, the presence of US-determined synovial hypertrophy and/or enhanced vascularity was associated with an increased risk of developing future clinical flares and experiencing radiographic progression.⁷⁰⁻⁷² In PsA, only a single study evaluated the value of ultrasonography as a predictor of structural progression in patients with recently diagnosed PsA.⁷³ The authors reported that a grey-scale score of ≥ 2 , a PD score of ≥ 2 , the

presence of enthesitis, and US signs of onychopathy at baseline, as well as persistent synovitis and enthesitis after 6 months, were significant predictors of structural deterioration.⁷⁰

US for Prediction of Treatment Response

The value of ultrasonography for predicting therapy response in PsA has not been investigated so far. In RA, it was reported that patients with a high number of PD-signals at baseline have a worse response to biological treatments, and the results of a Danish study revealed that a higher grade of US-verified inflammation predicted a better maintenance of anti-TNF- α therapy after 1 year.^{74,75}

SUMMARY

US may be an attractive tool for the diagnosis and monitoring of PsA patients. Perisynovial inflammation as well as enthesitis appear to be the most characteristic US findings in PsA, enabling the differentiation of the disease from overlapping conditions. During follow-up, US findings in joints, entheses, and skin are responsive to therapy with biological agents. A PsA-specific US composite score is warranted for a standardised sonographic scoring of patients in clinical studies and daily routine. Such a score should include all PsA manifestations and should be sensitive, reliable, and feasible. The relevance of sonography for remission assessment and the value of this tool as a biomarker in PsA have to be clarified by future research.

REFERENCES

1. Wollina U et al. Psoriatic arthritis. *Dermatol Ther.* 2010;23(2):123-36.
2. Coates LC et al. MRI and ultrasonography for diagnosis and monitoring of psoriatic arthritis. *Best Pract Res Clin Rheumatol.* 2012;26(6):805-22.
3. Anandarajah AP, Ritchlin CT. The diagnosis and treatment of early psoriatic arthritis. *Nat Rev.* 2009;5(11):634-41.
4. Schirmer M et al. Ultrasonography in inflammatory rheumatic disease: an overview. *Nat Rev Rheumatol.* 2011;7(8):479-88.
5. Taylor W et al. Classification criteria for psoriatic arthritis: development of new criteria from a large international study. *Arthritis Rheum.* 2006;54(8):2665-73.
6. Aletaha D et al. 2010 Rheumatoid arthritis classification criteria: an American College of Rheumatology/European League Against Rheumatism collaborative initiative. *Arthritis Rheum.* 2010;62(9):2569-81.
7. Gossec L et al. European League Against Rheumatism recommendations for the management of psoriatic arthritis with pharmacological therapies. *Ann Rheum Dis.* 2012;71(1):4-12.
8. Smolen JS et al. EULAR recommendations for the management of rheumatoid arthritis with synthetic and biological disease-modifying antirheumatic drugs: 2013 update. *Ann Rheum Dis.* 2014;73(3):492-509.
9. Altman R et al. The American College of Rheumatology criteria for the classification and reporting of osteoarthritis of the hand. *Arthritis Rheum.* 1990;33(11):1601-10.
10. Colebatch AN et al. EULAR recommendations for the use of imaging of the joints in the clinical management of rheumatoid arthritis. *Ann Rheum Dis.* 2013;doi:10.1136/annrheumdis-2012-203158.
11. Filer A et al. Utility of ultrasound joint counts in the prediction of rheumatoid arthritis in patients with very early synovitis. *Ann Rheum Dis.* 2011;70(3):500-7.
12. Freeston J et al. Is there sub-clinical synovitis in early psoriatic arthritis? A clinical comparison with grey scale and power Doppler ultrasound. *Arthritis Care Res (Hoboken).* 2014;66(3):432-9.
13. Marzo-Ortega H et al. Magnetic

- resonance imaging in the assessment of metacarpophalangeal joint disease in early psoriatic and rheumatoid arthritis. *Scand J Rheumatol.* 2009;38(2):79-83.
14. Wiell C et al. Ultrasonography, magnetic resonance imaging, radiography, and clinical assessment of inflammatory and destructive changes in fingers and toes of patients with psoriatic arthritis. *Arthritis Res Ther.* 2007;9(6):R119.
15. Balint P V et al. Ultrasonography of enthesal insertions in the lower limb in spondyloarthropathy. *Ann Rheum Dis.* 2002;61(10):905-10.
16. Lehtinen A et al. Sonographic analysis of enthesopathy in the lower extremities of patients with spondylarthropathy. *Clin Exp Rheumatol.* 1994;12(2):143-8.
17. Freeston J et al. Is there sub-clinical enthesitis in early psoriatic arthritis? A clinical comparison with power Doppler ultrasound. *Arthritis Care Res (Hoboken).* 2012;64(10):1617-21.
18. Bandinelli F et al. Ultrasound detects occult enthesal involvement in early psoriatic arthritis independently of clinical features and psoriasis severity. *Clin Exp Rheumatol.* 2013;31(2):219-24.
19. Unlü E et al. Color and duplex Doppler sonography to detect sacroiliitis and spinal inflammation in ankylosing spondylitis. Can this method reveal response to anti-tumor necrosis factor therapy? *J Rheumatol.* 2007;34(1):110-6.
20. Klauser A et al. Inflammatory low back pain: high negative predictive value of contrast-enhanced color Doppler ultrasound in the detection of inflamed sacroiliac joints. *Arthritis Rheum.* 2005;53(3):440-4.
21. Soriano A et al. Polymyalgia rheumatica in 2011. *Best Pract Res Clin Rheumatol.* 2012;26(1):91-104.
22. Spadaro A et al. Sonographic-detected joint effusion compared with physical examination in the assessment of sacroiliac joints in spondyloarthritis. *Ann Rheum Dis.* 2009;68(10):1559-63.
23. Bandinelli F et al. Clinical and radiological evaluation of sacroiliac joints compared with ultrasound examination in early spondyloarthritis. *Rheumatology.* 2013;52(7):1293-7.
24. Bakewell CJ et al. Ultrasound and magnetic resonance imaging in the evaluation of psoriatic dactylitis: status and perspectives. *J Rheumatol.* 2013;40(12):1951-7.
25. Kane D et al. Ultrasonography in the diagnosis and management of psoriatic dactylitis. *J Rheumatol.* 1999;26(8):1746-51.
26. Healy PJ et al. MRI changes in psoriatic dactylitis--extent of pathology, relationship to tenderness and correlation with clinical indices. *Rheumatology.* 2008;47(1):92-5.
27. Gutierrez M et al. High-frequency sonography in the evaluation of psoriasis: nail and skin involvement. *J Ultrasound Med.* 2009;28(11):1569-74.
28. Reece RJ et al. Distinct vascular patterns of early synovitis in psoriatic, reactive, and rheumatoid arthritis. *Arthritis Rheum.* 1999;42(7):1481-4.
29. Cimmino MA et al. Dynamic magnetic resonance of the wrist in psoriatic arthritis reveals imaging patterns similar to those of rheumatoid arthritis. *Arthritis Res Ther.* 2005;7(4):R725-31.
30. Fournié B et al. Extrasynovial ultrasound abnormalities in the psoriatic finger. Prospective comparative power-doppler study versus rheumatoid arthritis. *Joint Bone Spine.* 2006;73(5):527-31.
31. Jevtic V et al. Distinctive radiological features of small hand joints in rheumatoid arthritis and seronegative spondyloarthritis demonstrated by contrast-enhanced (Gd-DTPA) magnetic resonance imaging. *Skeletal Radiol.* 1995;24(5):351-5.
32. Gutierrez M et al. Differential diagnosis between rheumatoid arthritis and psoriatic arthritis: the value of ultrasound findings at metacarpophalangeal joints level. *Ann Rheum Dis.* 2011;70(6):1111-4.
33. Ottaviani S et al. Ultrasonography of shoulders in spondyloarthritis and rheumatoid arthritis: a case-control study. *Joint Bone Spine.* 2013;doi:10.1016/j.jbspin.2013.08.002. [Epub ahead of print].
34. D'Agostino MA et al. Assessment of peripheral enthesitis in the spondyloarthropathies by ultrasonography combined with power Doppler: a cross-sectional study. *Arthritis Rheum.* 2003;48(2):523-33.
35. Ibrahim G et al. Clinical and ultrasound examination of the leeds enthesitis index in psoriatic arthritis and rheumatoid arthritis. *ISRN Rheumatol.* 2011;2011:731917.
36. Zayat AS et al. The specificity of ultrasound-detected bone erosions for rheumatoid arthritis. *Ann Rheum Dis.* 2014;doi:10.1136/annrheumdis-2013-204864.
37. Finzel S et al. A comparative study of periarticular bone lesions in rheumatoid arthritis and psoriatic arthritis. *Ann Rheum Dis.* 2011;70(1):122-7.
38. Tan AL et al. A high-resolution magnetic resonance imaging study of distal interphalangeal joint arthropathy in psoriatic arthritis and osteoarthritis: are they the same? *Arthritis Rheum.* 2006;54(4):1328-33.
39. Eder L et al. Is the madrid sonographic enthesitis index useful for differentiating psoriatic arthritis from psoriasis alone and healthy controls? *J Rheumatol.* 2014;41(3):466-72.
40. Aydin SZ et al. The link between enthesitis and arthritis in psoriatic arthritis: a switch to a vascular phenotype at insertions may play a role in arthritis development. *Ann Rheum Dis.* 2013;72(6):992-5.
41. Naredo E et al. High prevalence of ultrasonographic synovitis and enthesopathy in patients with psoriasis without psoriatic arthritis: a prospective case-control study. *Rheumatology.* 2011;50(10):1838-48.
42. Gutierrez M et al. Subclinical enthesal involvement in patients with psoriasis: an ultrasound study. *Semin Arthritis Rheum.* 2011;40(5):407-12.
43. Gisondi P et al. Lower limb enthesopathy in patients with psoriasis without clinical signs of arthropathy: a hospital-based case-control study. *Ann Rheum Dis.* 2008;67(1):26-30.
44. Ash ZR et al. Psoriasis patients with nail disease have a greater magnitude of underlying systemic subclinical enthesopathy than those with normal nails. *Ann Rheum Dis.* 2012;71(4):553-6.
45. Tinazzi I et al. Preliminary evidence that subclinical enthesopathy may predict psoriatic arthritis in patients with psoriasis. *J Rheumatol.* 2011;38(12):2691-2.
46. Smolen JS et al. Treating spondyloarthritis, including ankylosing spondylitis and psoriatic arthritis, to target: recommendations of an international task force. *Ann Rheum Dis.* 2014;73(1):6-16.
47. Schoels M et al. Application of the DAREA/DAPSA score for assessment of disease activity in psoriatic arthritis. *Ann Rheum Dis.* 2010;69(8):1441-7.
48. Mumtaz A et al. Development of a preliminary composite disease activity index in psoriatic arthritis. *Ann Rheum Dis.* 2011;70(2):272-7.
49. Helliwell PS et al. The development of candidate composite disease activity and responder indices for psoriatic arthritis (GRACE project). *Ann Rheum Dis.* 2013;72(6):986-91.
50. Fiocco U et al. Rheumatoid and psoriatic knee synovitis: clinical, grey scale, and power Doppler ultrasound assessment of the response to etanercept. *Ann Rheum Dis.* 2005;64(6):899-905.
51. Husic R et al. Disparity between ultrasound and clinical findings in psoriatic arthritis. *Ann Rheum Dis.* 2013;doi:10.1136/annrheumdis-2012-203073.
52. Teoli M et al. Evaluation of clinical and ultrasonographic parameters in psoriatic arthritis patients treated with adalimumab: a retrospective study. *Clin Dev Immunol.* 2012:823854.
53. De Agustín JJ et al. A multicentre study

- on high-frequency ultrasound evaluation of the skin and joints in patients with psoriatic arthritis treated with infliximab. *Clin Exp Rheumatol*. 2012;30(6):879-85.
54. Schäfer VS et al. Evaluation of the novel ultrasound score for large joints in psoriatic arthritis and ankylosing spondylitis: six month experience in daily clinical practice. *BMC Musculoskelet Disord*. 2013;14:358.
55. Naredo E et al. Power Doppler ultrasonography assessment of entheses in spondyloarthropathies: response to therapy of enthesal abnormalities. *J Rheumatol*. 2010;37(10):2110-7.
56. Aydin SZ et al. Monitoring Achilles enthesitis in ankylosing spondylitis during TNF-alpha antagonist therapy: an ultrasound study. *Rheumatology (Oxford)*. 2010;49(3):578-82.
57. Gutierrez M et al. Sonographic monitoring of psoriatic plaque. *J Rheumatol*. 2009;36(4):850-1.
58. Gutierrez M et al. Clinical, power Doppler sonography and histological assessment of the psoriatic plaque: short-term monitoring in patients treated with etanercept. *Br J Dermatol*. 2011;164(1):33-7.
59. Coates LC et al. Defining minimal disease activity in psoriatic arthritis: a proposed objective target for treatment. *Ann Rheum Dis*. 2010;69(1):48-53.
60. Coates LC, Helliwell PS. Validation of minimal disease activity criteria for psoriatic arthritis using interventional trial data. *Arthritis Care Res (Hoboken)*. 2010;62(7):965-9.
61. Coates LC et al. Frequency, predictors, and prognosis of sustained minimal disease activity in an observational psoriatic arthritis cohort. *Arthritis Care Res (Hoboken)*. 2010;62(7):970-6.
62. Scheel AK et al. A novel ultrasonographic synovitis scoring system suitable for analyzing finger joint inflammation in rheumatoid arthritis. *Arthritis Rheum*. 2005;52(3):733-43.
63. Naredo E et al. Validity, reproducibility, and responsiveness of a twelve-joint simplified power doppler ultrasonographic assessment of joint inflammation in rheumatoid arthritis. *Arthritis Rheum*. 2008;59(4):515-22.
64. Dougados M et al. Evaluation of several ultrasonography scoring systems for synovitis and comparison to clinical examination: results from a prospective multicentre study of rheumatoid arthritis. *Ann Rheum Dis*. 2010;69(5):828-33.
65. Backhaus M et al. Evaluation of a novel 7-joint ultrasound score in daily rheumatologic practice: a pilot project. *Arthritis Rheum*. 2009;61(9):1194-201.
66. Gutierrez M et al. Development of a preliminary US power Doppler composite score for monitoring treatment in PsA. *Rheumatology (Oxford)*. 2012;51(7):1261-8.
67. Visser K et al. A matrix risk model for the prediction of rapid radiographic progression in patients with rheumatoid arthritis receiving different dynamic treatment strategies: post hoc analyses from the BeSt study. *Ann Rheum Dis*. 2010;69(7):1333-7.
68. Vastesaeger N et al. A pilot risk model for the prediction of rapid radiographic progression in rheumatoid arthritis. *Rheumatology (Oxford)*. 2009;48(9):1114-21.
69. Ritchlin CT et al. Treatment recommendations for psoriatic arthritis. *Ann Rheum Dis*. 2009;68(9):1387-94.
70. Miedany Y et al. Tailored approach to early psoriatic arthritis patients: clinical and ultrasonographic predictors for structural joint damage. *Clin Rheumatol*. 2014. [Epub ahead of print].
71. Ellegaard K et al. Ultrasound Doppler measurements predict success of treatment with anti-TNF- α ; drug in patients with rheumatoid arthritis: a prospective cohort study. *Rheumatology (Oxford)*. 2011;50(3):506-12.
72. Brown AK et al. Presence of significant synovitis in rheumatoid arthritis patients with disease-modifying antirheumatic drug-induced clinical remission: evidence from an imaging study may explain structural progression. *Arthritis Rheum*. 2006;54(12):3761-73.
73. Saleem B et al. Can flare be predicted in DMARD treated RA patients in remission, and is it important? A cohort study. *Ann Rheum Dis*. 2012;71(8):1316-21.
74. Scire CA et al. Ultrasonographic evaluation of joint involvement in early rheumatoid arthritis in clinical remission: power Doppler signal predicts short-term relapse. *Rheumatology*. 2009;48(9):1092-7.
75. Kamishima T et al. Semi-quantitative analysis of rheumatoid finger joint synovitis using power Doppler ultrasonography: when to perform follow-up study after treatment consisting mainly of antitumor necrosis factor alpha agent. *Skeletal Radiol*. 2010;39:457-65.