

# ENDOSCOPIC NECROSECTOMY AS TREATMENT FOR INFECTED PANCREATIC NECROSIS

Dr. Christian Jürgensen

Head of Endoscopy CCM, Department of Gastroenterology, Charité University, Berlin, Germany

**Disclosure:** No potential conflict of interest.

**Received:** 07.08.13 **Accepted:** 02.12.03

**Citation:** EMJ Gastroenterol. 2013;1:102-105.

---

## ABSTRACT

Necrotising pancreatitis can be life-threatening, but the introduction of endoscopic necrosectomy has led to a tremendous reduction of lethality. This review describes the technique and role of this method between conservative treatment and other interventional methods such as percutaneous drainage and surgery of superinfected necrosis. A little more than a decade after its introduction, endoscopic necrosectomy has become the gold standard in the interventional treatment of superinfected necrosis.

**Keywords:** Endoscopic necrosectomy, necrotising pancreatitis, interventional therapy, NOTES.

---

## INFECTION IN NECROTISING PANCREATITIS

### The Lethal Complication of the Second Phase

Acute pancreatitis is a common disease with a low morbidity in mild forms. However, severe acute pancreatitis can be life-threatening.<sup>1</sup> The lethality during the first 2 weeks is mostly due to consequences of (multi) organ failure.<sup>2</sup> This phase is dominated by the treatment of its different manifestations, such as acute respiratory distress syndrome (ARDS).

From the beginning of the third week, septic complications become dominant and are the main reason for lethality during the second phase of acute pancreatitis. Endoscopic necrosectomy, as well as other interventions, address these infectious problems. To know the onset of the pancreatitis can be helpful to distinguish these two phases, both being associated with signs of inflammation such as fever or leukocytosis.

### Indication for Intervention and Timing

The treatment of the infected necrosis has shifted from aggressive and early surgery to a delayed and less invasive approach. Asymptomatic patients can usually be followed without any

intervention. Conservative treatment has been shown to be successful in many patients, even for necrosis with proven infection.<sup>3</sup> However, the clinical course can force one to act. Like other treatment options, endoscopic necrosectomy is indicated only for those patients who suffer from symptoms such as sepsis, pain, or inability to take food orally. Procedures such as surgery, drainage, or endoscopic necrosectomy intend to control infection by drainage of pus, which is supplemented by removal of necroses. These necroses can be judged as fertile soil for bacteria and its extraction facilitates healing. The diagnosis of necrosis within a cavity is a challenge, but is of great impact for further treatment. Endoscopic ultrasound (EUS) can be helpful to diminish solid necrosis from fluid. As discussed above, infection is a problem not before the third week in the course of acute pancreatitis. Therefore, patients do not benefit from an earlier infection-driven therapeutic approach. This pathophysiological principle is supported by clinical data from surgical cohorts,<sup>4</sup> and likewise accepted for endoscopic necrosectomy.

## Growing Acceptance

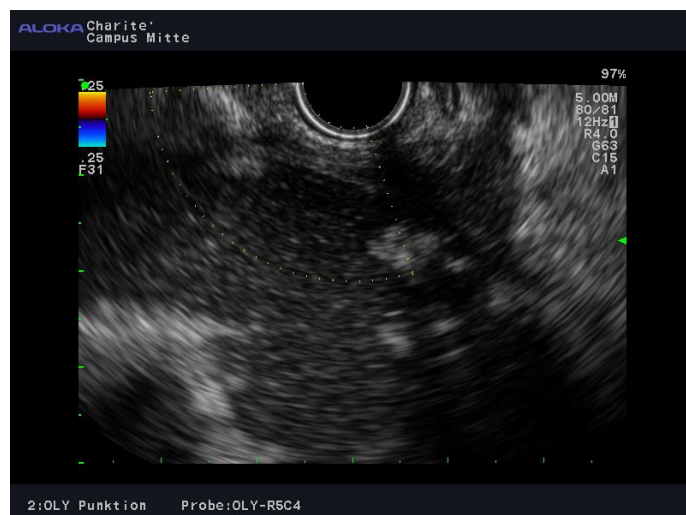
The initial description of endoscopic necrosectomy in 2000 by Seifert et al.<sup>5</sup> has been a milestone in the history of endoscopy technique. It is the first clinically established application of NOTES (natural orifice transluminal endoscopic surgery) and avoids much of the lethality related to superinfection in necrotising pancreatitis. It has passed the stages of a new method, from case report to small case series, multicentre studies<sup>6-8</sup> and a randomised study.<sup>9</sup>

The mentioned multicentre studies demonstrated a mortality of endoscopic necrosectomy of 6-8%, which is far less than reported for surgical cohorts (25-34%).<sup>10-12</sup> The minimal invasiveness, but also the option of early mobilisation, immediate enteral feeding, and the pain reduction by avoiding a transcutaneous approach, may contribute to its success. However, the mentioned randomised trial<sup>9</sup> was small (n=22) and addressed inflammatory markers, where a significant benefit for endoscopic necrosectomy was shown. The difference in lethality (n=4 for the surgical group versus n=1 for endoscopic necrosectomy) did not reach significance, since the study was underpowered to answer the superiority of one or both approaches. Therefore, the question of superiority in terms of mortality is not answered definitively. In light of the above mentioned studies, a recruitment for a larger randomised study may have become impossible and even expert surgical centres have started to refer to endoscopic necrosectomy as first-step treatment. Major drawbacks are the limitation to specialised centres and the high demand on endoscopy time. Additionally, the method is associated with risks such as perforation, bleeding, and air embolism.

## Technique

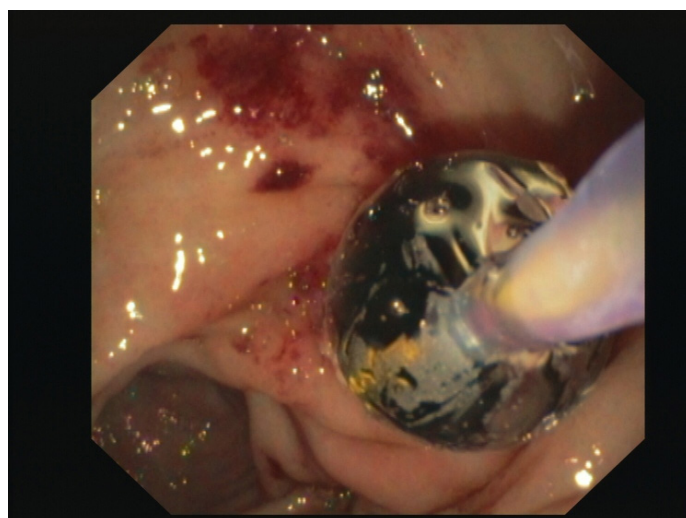
The endoscopic procedures constituting endoscopic necrosectomy can be assigned to three steps: access, necrosectomy and consolidation.<sup>13</sup>

The access to symptomatic pancreatic necrosis is the first step in the endoscopic treatment. The drainage of infected fluids results in a tremendous improvement in the patient's clinical situation. The location of the transluminal



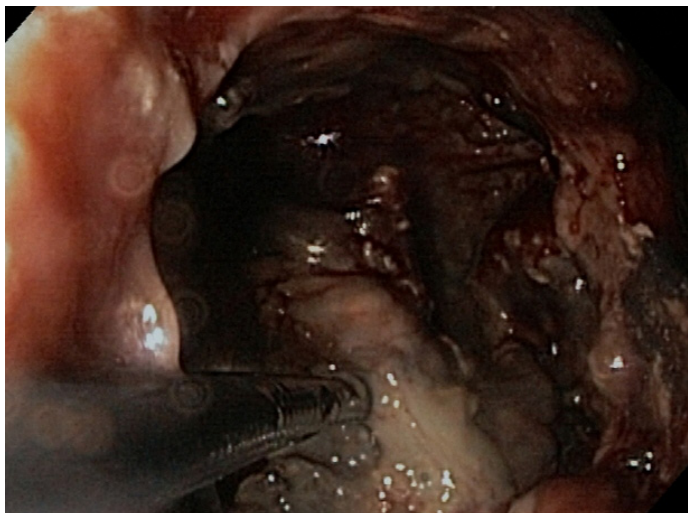**Figure 1. Endoscopic ultrasound from a gastral position before cyst drainage: colour Doppler mode is able to exclude intervening vessels.**

The cavity is shown with echogenic fluid and echogenic solid structures (bottom left) corresponding with necrotic material. Note close contact of gastric wall and necrotic cavity.

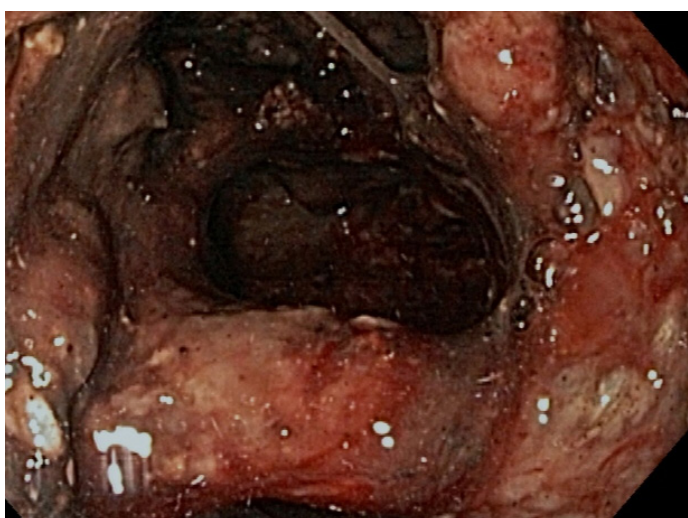

**Figure 2. Endoscopic view from a gastric position: wire guided balloon dilation to broaden an access into the cavity at the gastric posterior wall.**

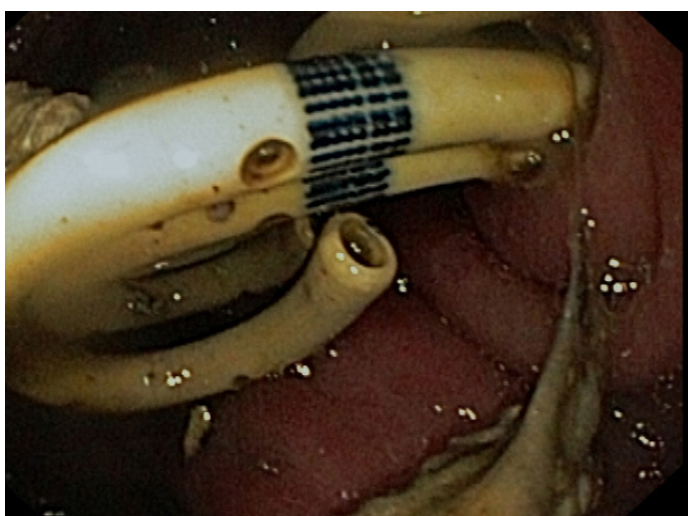puncture has to be chosen carefully, since it defines the route for further interventions. The formerly blind procedure has become controlled to the millimetre since the introduction of endoscopic ultrasound, and interposing vessels can be circumvented (Figure 1). Additionally, non-bulging cavities or those with more than 10 mm distance to the gastrointestinal wall have become accessible.<sup>14,15</sup>



**Figure 3. Internal endoscopic aspect of the cavity: removal of necrosis by use of a polyp grasper.**



**Figure 4. Internal endoscopic aspect of the cavity after removal of most of the necroses: vital splenic artery crossing the lumen.**



**Figure 5. Endoscopic view of the gastric posterior wall: three double pigtail drainages left in place to keep the access open until a complete resolution of the cavity is achieved.**

EUS-guided needle puncture is followed by the introduction of a guide wire under fluoroscopic co-control and dilation with a plethora of instruments (Soehendra-retriever, bougies, and dilation balloons, see [Figure 2](#)). The resulting channel is maintained by drainages or stents to offer time for subsequent consolidation before proceeding to necrosectomy. In most patients, a maximum diameter of 18 to 20 mm can be achieved during the first procedure. Broad access usually results in rapid general improvement and easier manoeuvring during the following interventions.

The necrosectomy itself may require many hours of endoscopy in order to remove the necrotic material with suboptimal instruments such as snares and polyp graspers still used today. The aim is to track the necrotic material into the stomach and to spare vital structures such as remaining pancreatic tissue or the splenic artery ([Figure 3, 4](#)). Sometimes the discrimination of these structures can be difficult but re-inspection during a follow-up session is helpful in most cases. In total, a number of three necrosectomy sessions each lasting roughly 2 hours may be required.

After removal of the necrotic material, the cavity is left with several transmural drains in place to ascertain the flow of remaining fluids during regression ([Figure 5](#)). The patient is sent home. After achieving remission of the cavity, 6 to 8 weeks later, the drains can be removed. The risk of persisting or recurrent infection becomes negligible by complete removal of the necrotic material.

## ROLE OF SURGERY AND PERCUTANEOUS DRAINAGE

The role of surgery in the treatment of infected pancreatic necrosis has shifted from being the gold standard to a backup method. However, indications persist where surgical intervention may be needed, when:

- endoscopic necrosectomy as treatment modality is not available and transport to a specialised endoscopy centre is not feasible;
- no endoscopic access to symptomatic necrosis could be achieved;
- complications of endoscopic therapy such as perforation or sustained bleeding occurred;

• cholecystectomy after biliary pancreatitis is necessary.

In return, endoscopic necrosectomy may be helpful in patients when remnant necrotic tissue becomes symptomatic after initial surgery.

Sole percutaneous drainage is feasible for infected pancreatic necrosis, but it is time consuming and may require large diameter drains. Today it can be a part of the treatment.<sup>16</sup> It may be combined with endoscopic necrosectomy in situations such as:

- initial stabilisation by percutaneous drainage resulting in decompression and regression of septic symptoms;
- additional access to flush from outside;
- drainage of remnant infected fluid collections not accessible by transluminal endoscopic approach.

It should be kept in mind that the endoscopic approach can be easier if the cavity is not 'emptied' by too long lasting initial external drainage. The otherwise resulting smaller size of

the cavity and the more or less solid remnant necroses can hinder endoscopic manoeuvres within the cavity. Additionally, external drainage may increase the distance to the gastric wall and thereby hamper to achieve an endoscopic access.

## CONCLUSION

Within a little more than a decade, endoscopic necrosectomy - if available - has become the method of choice for symptomatic pancreatic necrosis. The decision for endoscopic intervention has to be carefully balanced between conservative treatment and the requirement of additional and alternative options. The time consuming technique and the need of high level endoscopy are limiting this method to highly specialised referral endoscopy centres. The best treatment for patients with symptomatic necrosis depends on the locally available treatment options and the ability to transfer a patient to an expert endoscopic centre. As long as high level endoscopic necrosectomy is limited to these centres, the proclamation of a new gold standard has to be postponed.

## REFERENCES

1. Pandolfi SJ et al. Acute pancreatitis: bench to the bedside. *Gastroenterology*. 2007;132:1127-51.
2. Carnovale A et al. Mortality in acute pancreatitis: is it an early or a late event? *JOP*. 2005;6:438-44.
3. Runzi M et al. Severe acute pancreatitis: nonsurgical treatment of infected necroses. *Pancreas*. 2005;30:195-9.
4. Hartwig W et al. Reduction in mortality with delayed surgical therapy of severe pancreatitis. *J Gastrointest Surg*. 2002;6:481-7.
5. Seifert H et al. Retroperitoneal endoscopic debridement for infected peripancreatic necrosis. *Lancet*. 2000;356:653-5.
6. Seifert H et al. Transluminal endoscopic necrosectomy after acute pancreatitis: a multicentre study with long-term follow-up (the GEPARD Study). *Gut*. 2009;58:1260-6.
7. Gardner TB et al. Direct endoscopic necrosectomy for the treatment of walled-off pancreatic necrosis: results from a multicenter U.S. series. *Gastrointest Endosc*. 2011;73:718-26.
8. Yasuda I et al. Japanese multicenter experience of endoscopic necrosectomy for infected walled-off pancreatic necrosis: The JENIPaN study. *Endoscopy*. 2013;45:627-34.
9. Bakker OJ et al. Endoscopic transgastric vs surgical necrosectomy for infected necrotizing pancreatitis: a randomized trial. *JAMA*. 2012;307:1053-61.
10. Connor S et al. Early and late complications after pancreatic necrosectomy. *Surgery*. 2005;137:499-505.
11. Rau B et al. Surgical treatment of necrotizing pancreatitis by necrosectomy and closed lavage: changing patient characteristics and outcome in a 19-year, single-center series. *Surgery*. 2005;138:28-39.
12. Besselink MG et al. Surgical intervention in patients with necrotizing pancreatitis. *Br J Surg*. 2006;93:593-9.
13. Jurgensen et al. Endoscopic ultrasound-guided endoscopic necrosectomy of the pancreas: is irrigation necessary? *Surg Endosc*. 2012;26:1359-63.
14. Varadarajulu S et al. Role of EUS in drainage of peripancreatic fluid collections not amenable for endoscopic transmural drainage. *Gastrointest Endosc*. 2007;66:1107-19.
15. Park DH et al. Endoscopic ultrasound-guided versus conventional transmural drainage for pancreatic pseudocysts: a prospective randomized trial. *Endoscopy*. 2009;41:842-8.
16. Ross A et al. Combined endoscopic and percutaneous drainage of organized pancreatic necrosis. *Gastrointest Endosc*. 2010;71:79-84.