

NON-SURGICAL THERAPY FOR UNRESECTABLE HILAR CHOLANGIOCARCINOMA

Manuel Liberato,¹ Jorge Canena²

1. Director of University Gastroenterology Centre-Nova Medical School, Hospital Cuf Infante Santo, Lisbon, Portugal

2. Professor and Chairman of Gastroenterology, Faculty of Medical Sciences and Gastroenterology Consultant, University Gastroenterology Centre - Nova Medical School, Lisbon, Portugal

Disclosure: No potential conflict of interest.

Received: 10.09.13 **Accepted:** 08.12.13

Citation: EMJ Gastroenterol. 2013;1:92-100.

ABSTRACT

Hilar cholangiocarcinoma (HCCA) is characterised by late clinical symptoms. As a consequence, most patients will not undergo surgery, and palliation is the main goal of therapy. For the few patients that undergo potentially curative surgery, the need for preoperative biliary drainage (PBD) continues to be debated and remains controversial, as there are many reports with conflicting results. For the palliation of unresectable HCCA, endoscopic or percutaneous transhepatic drainage (PTD) is typically preferred over surgical palliative resection. PTD can be useful in patients with altered anatomy, as a guide to endoscopic procedures (rendezvous technique), after failure of endotherapy or as a rescue therapy for the drainage of segments that have been opacified by endoscopy. Endoscopic palliative bile duct drainage can be performed with plastic stents (PSs) or self-expandable metal stents (SEMSs). Several studies have compared PSs and SEMSs for the palliation of HCCA, and all have been in favour of SEMS placement, which is associated with a lower number of reinterventions, superior cumulative stent patency and even improved survival. The optimal technique for endoscopic palliative metal stent placement and the benefits of bilateral versus unilateral stenting remain controversial and highly debated. Drainage of only 25-30% of the liver volume may be sufficient to ameliorate jaundice in most cases of HCCA. However, reports of bilateral drainage are associated with longer stent patency, lower reintervention rates and, perhaps, a better quality of life for patients. Furthermore, newly available stents may be associated with higher rates of technical success and increasing successful reintervention rates in bilateral stenting.

Keywords: Cholangiocarcinoma, endotherapy, metal stents, plastic stents.

INTRODUCTION

Cholangiocarcinoma (CCA) is a primary cancer of the bile ducts and it arises from the malignant transformation of cholangiocytes - the epithelial cells that line the biliary tract. CCA is the second most common primary hepatobiliary cancer after hepatocellular carcinoma, and it accounts for 3% of all gastrointestinal cancers worldwide.¹ More than 90% of CCAs are adenocarcinomas.² According to its location in the biliary tree, CCA may be classified into extrahepatic and intrahepatic types. The extrahepatic type is further divided into hilar (HCCA), middle and distal tumours.³

The most common location of CCA is the main confluence of the hepatic ducts, which accounts for 60-70% of all CCAs.⁴ First described by Altmeier et al.⁵ in 1957, HCCA was only recognised as a distinct clinical entity in 1965 when Klatskin⁶ reported a series of 13 patients. Now known as Klatskin tumours, HCCA has a reported annual incidence of 1.2 per 100,000 individuals in the United States, with males being the most affected.^{1,3,4} The incidence of HCCA varies across the world, and it has been reported to be highest in the Khon Kaen province in the northeast region of Thailand, probably because of the high prevalence of liver fluke infestations.^{3,7}

Table 1. The Bismuth-Corlette classification for malignant hilar stenosis.

Type	Lesion
I	Stricture is located in the proximal common hepatic duct and spares the confluence of hepatic ducts.
II	Stricture includes the confluence and spares the segmental hepatic ducts.
IIIa	Stricture reaches the right hepatic duct.
IIIb	Stricture reaches the left hepatic duct.
IV	Stricture is multicentric or involves the right and left hepatic ducts.

HCCA has an extremely poor prognosis, with a 5-year survival rate of <10%, and most patients are in their sixth or seventh decade of life.^{1,3,4,8} Bismuth and Corlette⁹ classified malignant hilar stenosis into four categories^{9,10} according to the type of involvement of the hepatic ducts (Table 1). Although this classification does not characterise other structures such as the portal vein or the hepatic artery (which may help to predict surgical resectability), it is helpful when planning surgical resection or for endoscopic stent placement.^{1,8}

Unfortunately, HCCA is characterised by late clinical symptoms such as jaundice, pruritus, malaise, and weight loss. As a consequence, patients with Klatskin tumours typically present at an advanced stage of disease and/or have associated significant comorbidities that make them poor candidates for potential curative surgery. Overall, only 10-20% of patients with HCCA will undergo complete surgical resection with tumour-free margins, which is associated with the best prognosis and the best long-term survival.^{1,4,8} The need for preoperative biliary drainage (PBD) continues to be debated and remains controversial.¹¹⁻¹⁷ Some reports have suggested that PBD offers no advantage in decreasing perioperative mortality and morbidity.^{11-13,15} Furthermore, PBD has been associated with an increased risk of infectious complications, prolonged hospital stays, and increased costs. Finally, there is an increased incidence of tumour seeding through the biliary system that is associated with percutaneous drainage and can lead to poor surgical outcomes.¹⁵ A recent systematic review concluded that PBD had no clinical benefit in jaundiced patients with HCCA who were planned for

surgery.¹³ However, PBD is the established therapy in most centres with the rationale that PBD reverses cholestasis-associated hepatic and systemic toxicity as well as impaired hepatic regeneration.¹⁷ A recent multicentre European study of PBD for HCCA evaluated 366 patients, and PBD was performed in 180 patients. The authors concluded that PBD did not affect overall postoperative mortality, but it was associated with a decreased mortality rate after right hepatectomy and an increased mortality rate after left hepatectomy. A preoperative serum bilirubin level >50 µmol/L was also associated with increased mortality, but only after right hepatectomy.¹⁷ Furthermore, Japanese surgeons consider PBD to be mandatory in patients undergoing major hepatectomy.¹⁴ A recent paper compared endoscopic stenting, endoscopic nasobiliary drainage and percutaneous drainage for PBD, and the authors concluded that endoscopic nasobiliary drainage was the most suitable method for initial PBD in patients with HCCA.¹⁶

For patients who will not undergo surgery, palliation is the main goal of therapy. The relief of biliary obstruction not only reduces jaundice and associated pruritus but also improves related symptoms such as anorexia and disturbed sleep patterns and leads to an improved quality of life. For palliation of unresectable HCCA, endoscopic or percutaneous transhepatic drainage (PTD) is typically preferred over surgical palliative resection. Surgical procedures are associated with increased morbidity, and no survival benefits have been demonstrated in patients submitted to palliative surgery.^{1,2,4,8}

PERCUTANEOUS TRANSHEPATIC DRAINAGE VERSUS ENDOTHERAPY

Before any intervention for malignant hilar decompression, magnetic resonance cholangiopancreatography (MRCP) is strongly recommended to delineate the anatomy and plan the strategy for drainage.^{1,2,4,8} PTD is more invasive than the endoscopic approach and is associated with several disadvantages: haemorrhage during liver puncture, the need for the placement of external biliary catheters before internal drainage with stent insertion is attempted, longer hospitalisation, patient discomfort and inflammation, and pain at the puncture site.¹ However, PTD can be useful in altered anatomy or as a guide to endoscopic procedures (in a rendezvous manoeuvre). Furthermore, PTD is indicated when MRCP reveals that endotherapy is not likely to be successful in patients with Bismuth III or IV complex strictures.⁴ A recent retrospective study comparing endoscopy versus PTD with internal drainage with metal stents after external drainage in patients with Bismuth type III or IV HCCA demonstrated a higher initial success rate and a low level of procedure-related cholangitis in favour of the PTD approach.¹⁸ Finally, PTD can be used after failure of endotherapy or as a rescue therapy for the

drainage of segments that have been opacified by endoscopy and were not decompressed, as this is associated with poor outcomes. Endoscopic drainage should be recommended as the first-line drainage technique for malignant HCCA,^{1,4,8} however, the final decision about the method of drainage should be considered along with anatomical factors, MRCP results, and local expertise with both methods.

ENDOTHERAPY

Plastic Stents Versus Self-Expandable Metal Stents

Endoscopic palliative bile duct drainage was first reported by Soehendra et al.¹⁹ Currently, two types of endoscopic stents are available. With the introduction of duodenoscopes with 4.2 mm working channels in 1982, the endoscopic insertion of large-bore plastic biliary stents (PSs) became possible.²⁰ The main disadvantage of plastic endoprostheses is the relatively high occlusion rate caused by biliary sludge, which occurs at a median interval of 3 to 4 months after placement.²¹ First described in 1989,^{22,23} self-expandable metal stents (SEMSs) are available with different lengths, diameters, and delivery devices. SEMSs with a maximum diameter of 10

Table 2. Studies comparing the placement of plastic stents versus metal stents for palliation of hilar cholangiocarcinoma.

Author	Study design	Patients (n)	Main outcomes
Wagner et al. ²⁸ 1993	RCT	Plastic (n=9) Metal (n=11)	Significantly long-term patency technical success rates, lower reintervention rates and diminished costs for SEMS group.
Sangchan et al. ⁷ 2012	RCT	Plastic (n=54) Metal (n=54)	Significantly longer patency, successful drainage and longer survival for SEMS group.
Mukai et al. ²⁹ 2013	RCT	Plastic (n=30) Metal (n=30)	Significantly longer patency, lower costs and lower number of reinterventions for SEMS group. No survival benefit.
Liberato and Canena. ²⁷ 2012	Retrospective	Plastic (n=231) Metal (n=249)	Significantly higher technical and clinical success rates in the intention-to-treat analysis, lower reintervention rates and longer patency for SEMS group in all Bismuth classifications. No survival benefit.
Perdue et al. ²⁶ 2008	Prospective (30-day outcomes)	Plastic (n=28) Metal (n=34)	Significantly higher number of adverse outcomes including cholangitis, stent occlusion, migration, perforation, and/or the need for unplanned ERCP or PTD in plastic group.
Raju et al. ²⁴ 2011	Retrospective	Plastic (n=52) Metal (n=48)	Significantly longer patency and lower number of reinterventions for SEMS group. No survival benefit.

RCT: randomised controlled trial; SEMS: self-expandable metal stent; PTD: percutaneous transhepatic drainage; ERCP: endoscopic retrograde cholangiopancreatography.

mm theoretically offer the optimal conditions for long-term drainage; in addition to having a larger diameter, SEMs also have a fenestrated mesh that permits drainage from secondary branch ducts. PSs and SEMs placed in HCCA have been associated with a lower duration of patency when compared to the median patency of PSs and SEMs in the palliation of malignant distal obstruction.^{21,24,25}

Several studies have compared PSs and SEMs for the palliation of HCCA, and all have been in favour of SEM placement (Table 2).^{7,24,26-29} Three randomised controlled trials have compared PSs with SEMs for unresectable HCCA drainage.^{7,28-29} In an older study, 20 patients with type II-IV hilar malignancies were randomly assigned to receive PSs or SEMs, which were placed using a combined endoscopic-percutaneous technique.²⁸ Although the sample size was small and most of the stents were placed by the percutaneous route, the authors observed higher long-term patency with a decreased incidence of cholangitis, higher technical success rates, significantly lower reintervention rates for stent failure, and diminished costs with reduced hospital stay for patients who received SEMs. In another study from the Khon Kaen province, 108 patients were randomly allocated to receive SEM or PS placement.⁷ The authors reported that endoscopic biliary drainage with SEMs was associated with a significantly increased successful drainage rate and longer survival compared with PS placement. In another study from Japan, 60 patients were enrolled and prospectively randomised into the PS or SEM group.²⁹ SEMs were significantly associated with longer patency, lower reintervention rates and lower overall treatment costs. No survival benefit was found in this trial.

In a recent study,²⁷ 480 patients with inoperable HCCA were retrospectively reviewed. Patients were divided into three groups according to the Bismuth classification and underwent PS or SEM placement. The authors concluded that SEM insertion for the palliation of hilar cholangiocarcinoma offered higher technical and clinical success rates in the intention-to-treat (ITT) analysis as well as lower reintervention rates and superior cumulative stent patency when compared with PS placement in all Bismuth classifications. Again, no survival benefit was found.

Endoscopic palliation of HCCA with SEMs should be considered the gold standard of care, as it is associated with a lower number of reinterventions, superior cumulative stent patency and even improved survival.^{1,4,7,8,24-29} Furthermore, the lower number of reinterventions, days of hospitalisation and hospital re-admissions observed for patients submitted to SEM placement indicate a clear benefit for SEMs, which can be translated into improved patient quality of life. A recent systematic review of the literature comparing PSs versus SEMs concluded that the use of metal stents was associated with a significantly higher successful drainage rate, a lower early complication rate, longer stent patency, and longer patient survival.³⁰ PSs should be reserved for patients with a very low expected survival (1-2 months), for PBD (when it is considered and depending on the centre and country, as previously discussed in this article), and whether the patient is receiving photodynamic therapy because PSs should be removed during this treatment.³¹⁻³⁵ However, delivery of photodynamic therapy (PDT) is possible with an inserted SEM as long as the dose is reduced.³⁵ PDT for palliation of HCCA has been shown to prolong survival in two randomised trials that included patients treated with PSs^{32,33} and also in a non-randomised controlled study that included patients submitted to palliation with SEMs.³⁴

Unilateral Versus Bilateral Endoscopic Biliary Stenting

The optimal technique for endoscopic palliative metal placement and the benefits of bilateral versus unilateral stenting remain controversial and highly debated. De Palma et al.³⁶ reported the only prospective, randomised, controlled study comparing unilateral and bilateral drainage using PSs in 157 patients. In the ITT analysis, unilateral placement resulted in a significantly higher rate of stent insertion (88.6% versus 76.9%) and a lower rate of complications and early cholangitis when compared with bilateral placement. The authors concluded that the routine insertion of more than one stent would not be justified and that single stent insertion avoids the risk of further procedure-related complications and mortality. However, these results need to be interpreted with caution because of some study biases. Information about stent patency and occlusion rates in both groups

was not available. Furthermore, patient subgroup analyses were not performed, and there was a high number of patients with Bismuth type I stricture included, for which the placement of one stent is sufficient; thus, it is impossible to determine how the results might have been affected by their inclusion.

Bilateral drainage is, theoretically, more physiological than unilateral drainage,^{8,37} although this may be disputed by reports suggesting that drainage of a mere 25-30% of the liver volume may be sufficient to ameliorate jaundice^{37,38} in most cases of HCCA. Indeed, bilateral drainage

may not be necessary in some cases, particularly if previous MRCP is used to select the optimal lobe and biliary segment(s) to be drained.^{39,40} However, to preserve functional liver volume, unilateral drainage may be less effective than bilateral drainage. Furthermore, a report that assessed the relative volumetry of the liver on CT scans suggested that drainage of more than 50% of the liver volume is associated with prolonged survival.⁴¹ Bilateral stenting has been reported to be more technically demanding.^{42,43} Various techniques have been described for bilateral SEMs placement.⁴²⁻⁵⁰ The most commonly used technique is the stent-in-stent (SIS) method (Figure 1),

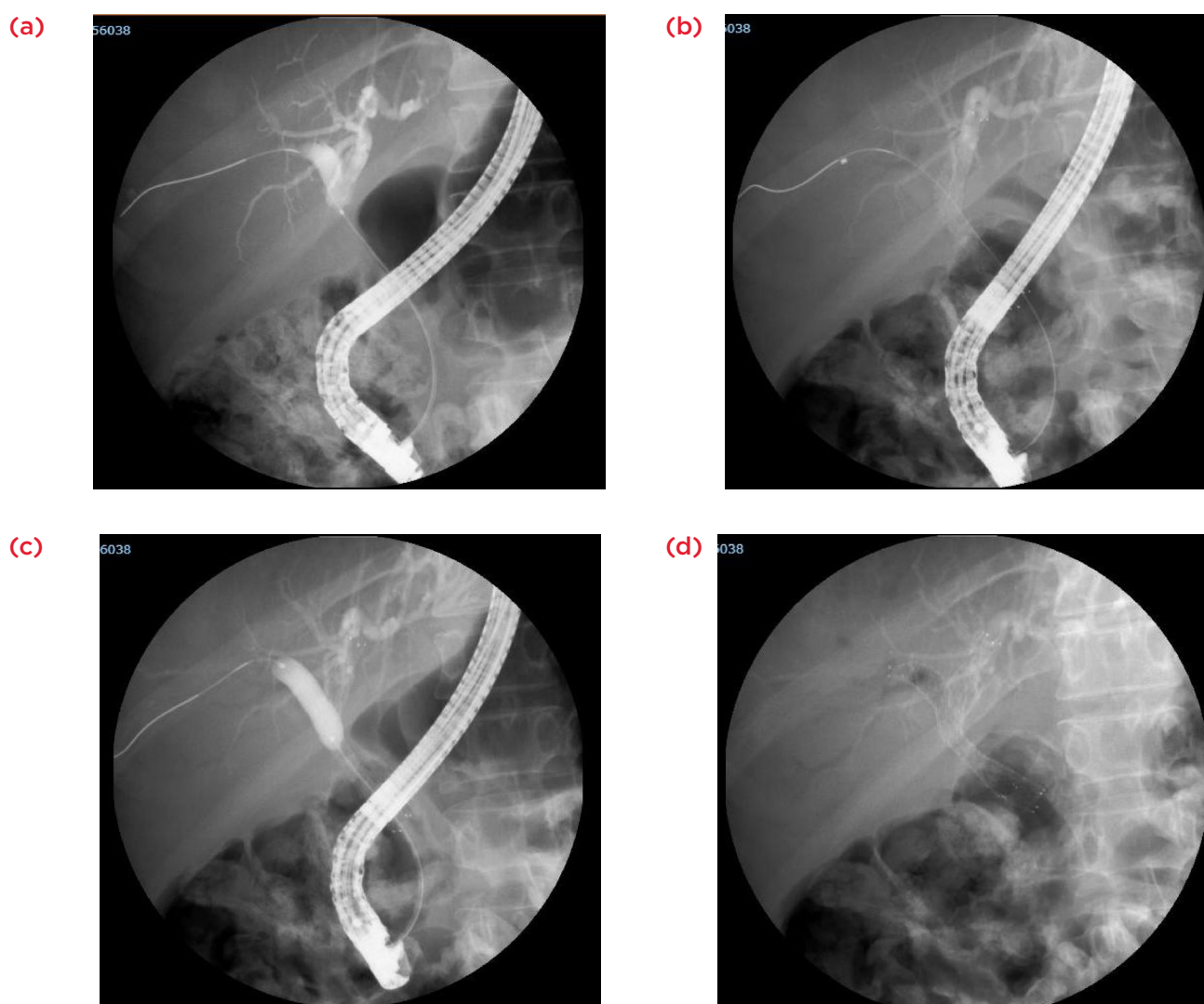


Figure 1. The stent-in-stent (SIS) method for bilateral SEMs placement.

(a) Cholangiogram of a malignant hilar stenosis (Bismuth II).

(b) After placement of the first SEMS in the left hepatic duct the guidewire was inserted, under fluoroscopic guidance, into the contralateral hepatic duct through the interstices of the initial SEMS.

(c) Balloon dilatation of the mesh interstices of the SEMS placed in the left hepatic duct to facilitate the passage of the second SEMS to the right hepatic duct.

(d) Fluoroscopic view of bilateral stenting to form a Y-shaped configuration.

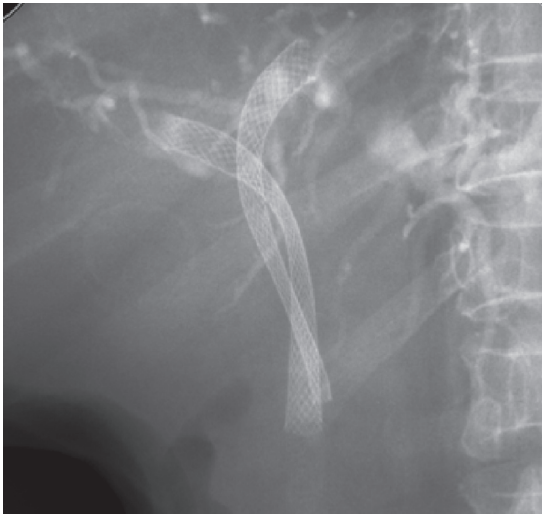


Figure 2. Bilateral stenting in a side by side configuration.

Reproduced with permission²⁷

in which a wide-mesh SEMS (although a stent with a closed-cell configuration can also be used) is inserted into one side of the hepatic duct, and a second SEMS is positioned on the contralateral side across the mesh.^{45,46} Recently, SEMSs with extra-wide open-mesh designs in the central portion to facilitate bilateral placement have been described, with encouraging results.^{47,50,51} Other studies have described techniques to place an SEMS in a side by side (SBS) configuration (Figure 2),²⁷ with good results.⁴²⁻⁴⁴ Recently, a novel SEMS

was developed with a 6-French delivery system to allow the SBS insertion of bilateral SEMSs^{49,52} (Figure 3).²⁷ No randomised trials comparing unilateral versus bilateral SEMS deployment are available. However, several reports have compared the deployment of one or the bilateral placement of SEMSs in unresectable HCCA^{27,29,44,53} (Table 3). A recent retrospective review of 46 patients with hilar malignant obstruction compared unilateral (n=17) with bilateral (n=29) SEMS stenting.⁴⁴ Cumulative stent patency was significantly increased with bilateral stenting (median patency of 488 days versus 210 days, p=0.009), particularly in cases of CCA. Moreover, there were no significant differences between the two groups in terms of successful stent insertion, successful drainage or early or late complications. In a retrospective review, the outcomes of the unilateral (n=35) or bilateral (n=42) placement of SEMSs in patients with type II HCCA were analysed.²⁷ Bilateral stenting was associated with significantly fewer reinterventions and increased median stent patency. Again, technical success and clinical success were similar in the two groups.

One important issue is the determination of the technique that is better or associated with a lower complication rate. SBS deployment has been reported to occasionally cause portal vein occlusion and increase the rate of cholangitis due to the excessive expansion of the bile duct by parallel stents.

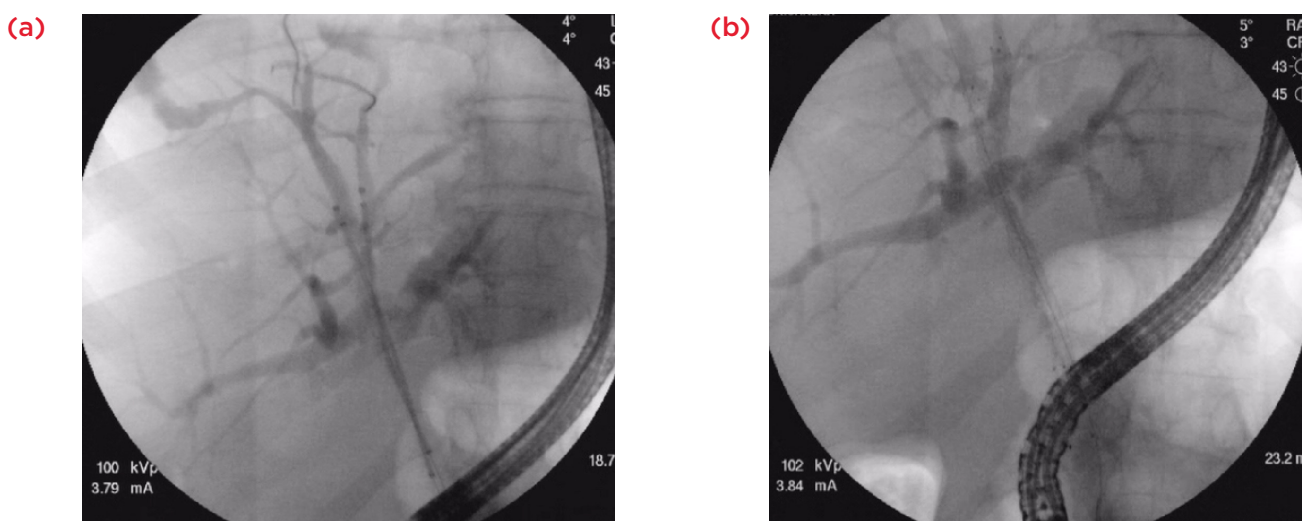


Figure 3. Bilateral stenting using a 6-French delivery system.

Reproduced with permission²⁷

- (a) Fluoroscopic view of side by side delivery systems pre-deployment.
- (b) Fluoroscopic view of post-deployment bilateral stenting.

Table 3. Studies comparing unilateral placement versus bilateral placement of metal stents for palliation of hilar cholangiocarcinoma.

Author	Study design	Patients (n)	Main outcomes
Naitoh et al. ⁴⁴ 2009	Retrospective	Uni (n=17) Bi (n=29)	Significantly cumulative stent patency in Bil group. Similar stent insertion, successful drainage and survival in two groups/Bil.
Iwano et al. ⁵³ 2011	Retrospective	Uni (n=65) Bil (n=17)	Similar median stent patency, complication-free survival and survival in two groups. Significantly higher incidence of liver abscess in Bil group/Uni.
Liberato and Canena. ²⁷ 2012	Retrospective	Uni (n=35) Bil (n=42)	Significantly longer stent patency and lower number of reinterventions for Bil group. Similar stent insertion and survival in two groups /Bil.
Mukai et al. ²⁹ 2013	Prospective	Uni (n=14) Bil (n=26)	Similar stent patency in two groups. Significantly higher success rate of reintervention in Uni group/Uni.

Uni: unilateral; Bil: bilateral.

However, a recent study⁵⁴ compared SBS versus SIS deployment in 52 consecutive patients with malignant hilar obstruction. The authors found no differences in technical success and functional success between groups. SBS deployment was associated with a higher rate of complications and significantly better stent patency in a Kaplan-Meier analysis but not in a multivariate analysis. Overall, it is unclear whether one technique is better than the other, and further studies on this issue are warranted.

One other concern with bilateral SEMS deployment is reintervention for stent dysfunction, which has been reported to be much more challenging in bilateral stenting.^{24,29} However, two recent studies have reported a high success rate for reintervention after bilateral SEMS placement. One study using cross-wired SEMSs reported a technical success of 83.3% for the revision of cases where the primary deployed bilateral SEMSs were occluded. Another study using SBS deployment reported a revision success rate of 92% after stent occlusion.⁵⁵

Therefore, the placement of unilateral or bilateral SEMSs in HCCA remains controversial. Selected cases with previous imaging guidance (MRCP) may be better served with unilateral drainage. In

unilateral stenting, contrast medium injection into the intrahepatic ducts without adequate drainage should be avoided, as this is associated with uncontrolled cholangitis and poor prognosis.⁵⁶ However, bilateral stenting is associated with longer stent patency, a lower reintervention rate and, perhaps, better patient quality of life. Furthermore, newly available stents may be associated with higher rates of technical success and increasing successful reintervention rates. Hopefully, future well-designed, large-scale, multicentre studies will bring further light to the question of which technique (bilateral or unilateral stenting) should be recommended for the treatment of unresectable HCCA.

CONCLUSION

In conclusion, the endoscopic palliation of unresectable HCCA should be the preferred technique and should be performed with SEMSs. PTD can be useful in patients with altered anatomy, after failure of endotherapy or as a rescue therapy for the drainage of segments that have been opacified by endoscopy. Unilateral or bilateral stenting remains controversial although there are increasing reports that bilateral drainage is associated with better outcomes than unilateral drainage in selected cases.

REFERENCES

1. Larghi A et al. Management of hilar biliary strictures. *Am J Gastroenterol.* 2008;103:458-73.
2. Singh P, Patel T. Advances in the diagnosis, evaluation and management of cholangiocarcinoma. *Curr Opin Gastroenterol.* 2006;22:294-9.
3. Lazaridis KN, Gores GJ. Cholangiocarcinoma. *Gastroenterology.* 2005;128:1655-67.
4. Gerges C et al. Expandable metal stents for malignant hilar biliary obstruction. *Gastrointest Endosc Clin N Am.* 2011;21:481-97.
5. Altemeier WA et al. Sclerosing carcinoma of the major intrahepatic bile ducts. *AMA Arch Surg.* 1957;75:450-60.
6. Klatskin G. Adenocarcinoma of the hepatic duct at its bifurcation within the porta hepatitis: an usual tumor with distinctive clinical and pathologic features. *Am J Med.* 1965;38:241-7.
7. Sangchan A et al. Efficacy of metal and plastic stents in unresectable complex hilar cholangiocarcinoma: a randomized controlled trial. *Gastrointest Endosc.* 2012;76:93-9.
8. Srinivasan I, Kahaleh M. Metal stents for hilar lesions. *Gastrointest Endosc Clin N Am.* 2012;22:555-65.
9. Bismuth H, Corlette MB. Intrahepatic cholangioenteric anastomosis in carcinoma of the hilus of the liver. *Surg Gynecol Obstet.* 1975;140:170-8.
10. Bismuth H et al. Resection or palliation: priority of surgery in the treatment of hilar cancer. *World J Surg.* 1988;12:39-47.
11. Hatfield AR et al. Preoperative external biliary drainage in obstructive jaundice. A prospective controlled clinical trial. *Lancet.* 1982;2:896-9.
12. Ferrero A et al. Preoperative biliary drainage increases infectious complications after hepatectomy for proximal bile duct tumor obstruction. *World J Surg.* 2009;33:318-25.
13. Liu F et al. Preoperative biliary drainage before resection for hilar cholangiocarcinoma: Whether or not? A systematic review. *Dig Dis Sci.* 2011;56:663-72.
14. Yasuda I et al. Unilateral versus bilateral endoscopic biliary stenting for malignant hilar biliary strictures. *Dig Endosc.* 2013;25 (Suppl. 2):81-5.
15. Takahashi Y et al. Percutaneous transhepatic biliary drainage catheter tract recurrence in cholangiocarcinoma. *Br J Surg.* 2010;97:1860-6.
16. Kawakami H et al. Endoscopic nasobiliary drainage is the most suitable preoperative biliary drainage method in the management of patients with hilar cholangiocarcinoma. *J Gastroenterol.* 2011;46:242-8.
17. Farges O et al. Multicentre European study of preoperative biliary drainage for hilar cholangiocarcinoma. *Br J Surg.* 2013;100:274-83.
18. Paik WH et al. Palliative treatment with self-expandable metallic stents in patients with advanced type III or IV hilar cholangiocarcinoma: a percutaneous versus endoscopic approach. *Gastrointest Endosc.* 2009;69:55-62.
19. Soehendra N, Reynders-Frederix V. Palliative bile duct drainage - A new endoscopic method of introducing a transpapillary drain. *Endoscopy.* 1980;12:8-11.
20. Huibregtse K, Tytgat GN. Palliative treatment of obstructive jaundice by transpapillary introduction of large bore bile duct endoprosthesis. *Gut.* 1982;23:371-5.
21. Cheng JL et al. Endoscopic palliation of patients with biliary obstruction caused by nonresectable hilar cholangiocarcinoma: efficacy of self-expandable metallic Wallstents. *Gastrointest Endosc.* 2002;56:33-9.
22. Huibregtse K et al. Endoscopic placement of expandable metal stents for biliary strictures-a preliminary report on experience with 33 patients. *Endoscopy.* 1989;21:280-2.
23. Neuhaus H et al. Self-expanding biliary stents: preliminary clinical experience. *Endoscopy.* 1989;21:225-8.
24. Raju RP et al. Optimum palliation of inoperable hilar cholangiocarcinoma: comparative assessment of the efficacy of plastic and self-expanding metal stents. *Dig Dis Sci.* 2011;56:1557-64.
25. Chang WH et al. Outcome in patients with bifurcation tumors who undergo unilateral versus bilateral hepatic duct drainage. *Gastrointest Endosc.* 1998;47:354-62.
26. Perdue DG et al. Plastic versus self-expanding metallic stents for malignant hilar biliary obstruction: a prospective multicenter observational cohort study. *J Clin Gastroenterol.* 2008;42:1040-6.
27. Liberato M, Canena J. Endoscopic stenting for hilar cholangiocarcinoma: efficacy of unilateral and bilateral placement of plastic and metal stents in a retrospective review of 480 patients. *BMC Gastroenterol.* 2012;12:103.
28. Wagner HJ et al. Plastic endoprostheses versus metal stents in the palliative treatment of malignant hilar biliary obstruction. A prospective and randomized trial. *Endoscopy.* 1993;25:213-18.
29. Mukai T et al. Metallic stents are more efficacious than plastic stents in unresectable malignant hilar biliary strictures: a randomized controlled trial. *J Hepatobiliary Pancreat Sci.* 2013;20:214-22.
30. Hong W et al. Endoscopic stenting for malignant hilar biliary obstruction: should it be metal or plastic and unilateral or bilateral? *Eur J Gastroenterol Hepatol.* 2013;25:1105-12.
31. Dumonceau JM et al. Biliary stenting: indications, choice of stents and results: European Society of Gastrointestinal Endoscopy (ESGE) clinical guideline. *Endoscopy.* 2012;44:277-98.
32. Ortner MEJ et al. Successful photodynamic therapy for nonresectable cholangiocarcinoma: a randomized prospective study. *Gastroenterology.* 2003;125:1355-63.
33. Zoepf T et al. Palliation of nonresectable bile duct cancer: improved survival after photodynamic therapy. *Am J Gastroenterol.* 2005;100:2426-30.
34. Gerhardt T et al. Combination of bilateral metal stenting and trans-stent photodynamic therapy for palliative treatment of hilar cholangiocarcinoma. *Z Gastroenterol.* 2010;48:28-32.
35. Wang L-W et al. Self-expandable metal stents and trans-stent light delivery: are metal stents and photodynamic therapy compatible? *Lasers Surg Med.* 2008;40:651-9.
36. De Palma GD et al. Unilateral versus bilateral endoscopic hepatic duct drainage in patients with malignant hilar biliary obstruction: results of a prospective, randomized, and controlled study. *Gastrointest Endosc.* 2001;53:547-53.
37. Kato H et al. Endoscopic bilateral deployment of multiple metallic stents for malignant hilar biliary strictures. *Dig Endosc.* 2013;25 (Suppl 2):75-80.
38. De Palma GD et al. Unilateral placement of metallic stents for malignant hilar obstruction: a prospective study. *Gastrointest Endosc.* 2003;58:50-3.
39. Hintze RE et al. Magnetic resonance cholangiopancreatography-guided unilateral endoscopic stent placement for Klatskin tumors. *Gastrointest Endosc.* 2001;53:40-6.
40. Freeman ML, Overby C. Selective MRCP and CT-targeted drainage of malignant hilar biliary obstruction with self-expanding metallic stents. *Gastrointest Endosc.* 2003;58:41-9.
41. Vienne A et al. Prediction of drainage effectiveness during endoscopic stenting

- of malignant hilar strictures: the role of liver volume assessment. *Gastrointest Endosc.* 2010;72:728-35.
42. Hookey LC et al. Use of a temporary plastic stent to facilitate the placement of multiple self-expanding metal stents in malignant biliary hilar strictures. *Gastrointest Endosc.* 2005;62:605-9.
43. Dumas R et al. Endoscopic bilateral metal stent placement for malignant hilar stenoses: identification of optimal technique. *Gastrointest Endosc.* 2000;51:334-8.
44. Naitoh I et al. Unilateral versus bilateral endoscopic metal stenting for malignant hilar biliary obstruction. *J Gastroenterol Hepatol.* 2009;24:552-7.
45. Neuhaus H et al. The "stent through wire mesh technique" for complicated biliary strictures. *Gastrointest Endosc.* 1993;39:553-6.
46. Chahal P, Baron T. Expandable metal stents for endoscopic stent-within-stent placement for malignant hilar biliary obstruction. *Gastrointest Endosc.* 2010;71:195-9.
47. Kim JY et al. Usefulness of slimmer and open-cell-design stents for endoscopic bilateral stenting and endoscopic revision in patients with hilar cholangiocarcinoma (with video). *Gastrointest Endosc.* 2009;70:1109-15.
48. Park DH et al. Newly designed stent for endoscopic bilateral stent-in-stent placement of metallic stents in patients with malignant hilar biliary strictures: multicenter prospective feasibility study (with videos). *Gastrointest Endosc.* 2009;69:1357-60.
49. Chennat J, Waxman I. Initial performance profile of a new 6F self-expanding metal stent for palliation of malignant hilar biliary obstruction. *Gastrointest Endosc.* 2010;72:632-6.
50. Liberato M, Pontes J. "Tumores de las Vías Biliares y del Páncreas," Vázquez-Iglesias J, Aguirre P (eds.), In *Endoscopia Digestiva Diagnóstica y Terapéutica* (2008), Madrid: Editorial Medica Panamericana, pp. 551-72.
51. Lee TH et al. Primary and revision efficacy of cross-wired metallic stents for endoscopic bilateral stent-in-stent placement in malignant hilar biliary strictures. *Endoscopy.* 2013;45:106-13.
52. Law R, Baron TH. Bilateral metal stents for hilar biliary obstruction using a 6Fr delivery system: outcomes following bilateral and side-by-side stent deployment. *Dig Dis Sci.* 2013;58:2667-72.
53. Iwano H et al. Unilateral versus bilateral drainage using self-expandable metallic stent for unresectable hilar biliary obstruction. *Dig Endosc.* 2011;23:43-8.
54. Naitoh I et al. Side-by-side versus stent-in-stent deployment in bilateral endoscopic metal stenting for malignant hilar biliary obstruction. *Dig Dis Sci.* 2012;57:3279-85.
55. Lee TH et al. Technical feasibility and revision efficacy of the sequential deployment of endoscopic bilateral side-by-side metal stents for malignant hilar biliary strictures: a multicenter prospective study. *Dig Dis Sci.* 2013;58:547-55.
56. Chang WH et al. Outcome in patients with bifurcation tumors who undergo unilateral versus bilateral hepatic duct drainage. *Gastrointest Endosc.* 1998;47:354-62.