

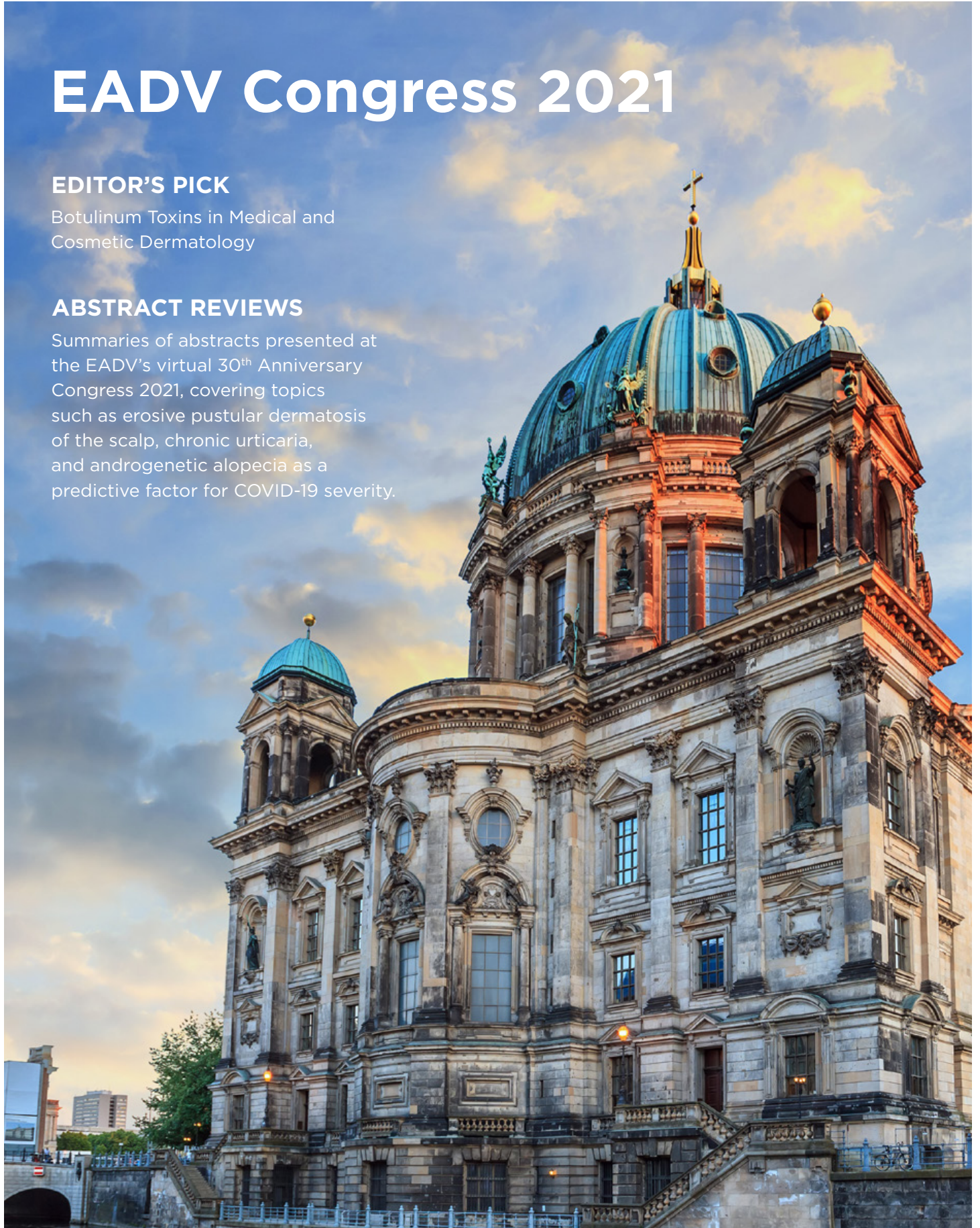## EADV Congress 2021

### EDITOR'S PICK

Botulinum Toxins in Medical and  
Cosmetic Dermatology

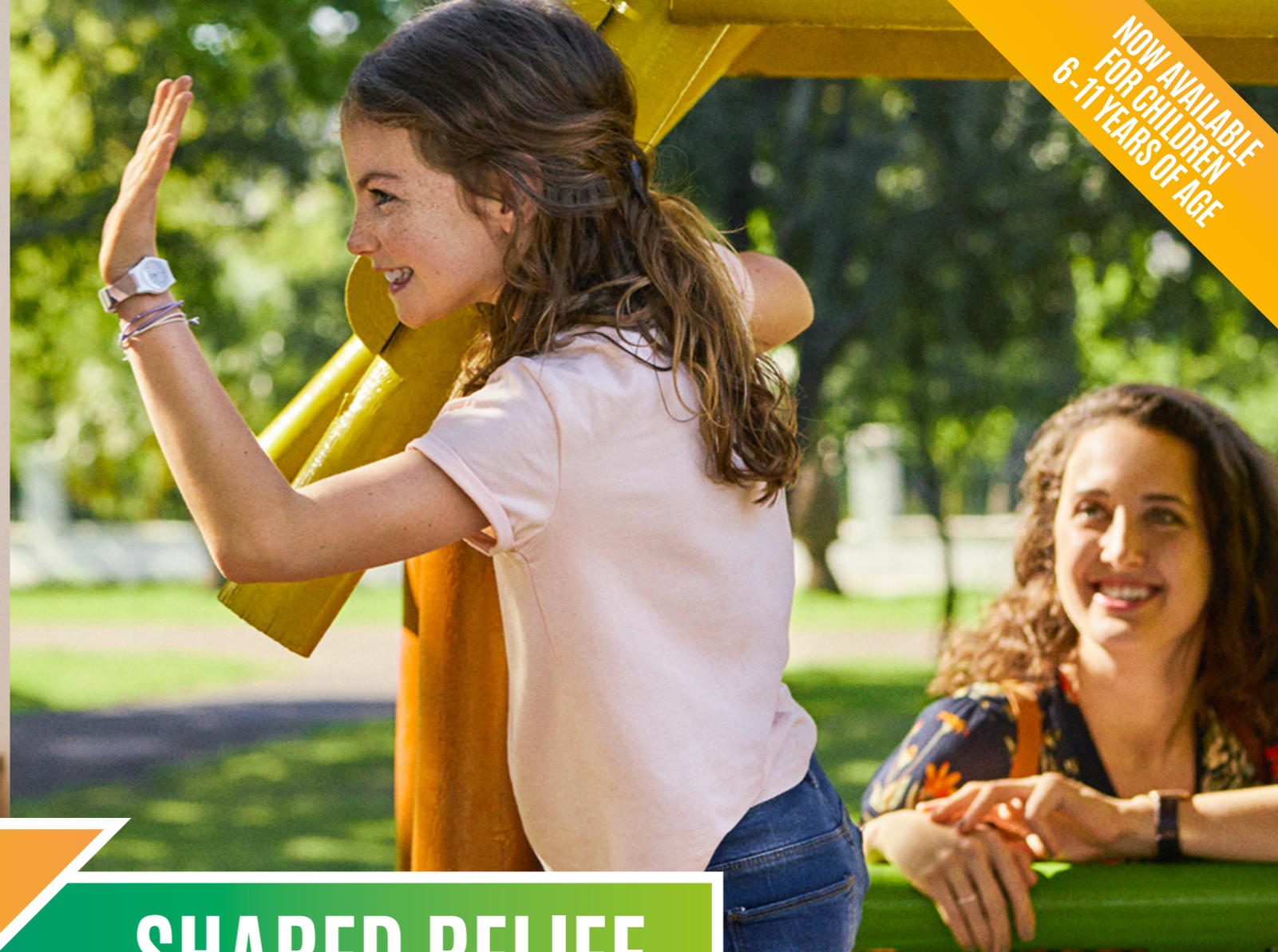### ABSTRACT REVIEWS

Summaries of abstracts presented at the EADV's virtual 30<sup>th</sup> Anniversary Congress 2021, covering topics such as erosive pustular dermatosis of the scalp, chronic urticaria, and androgenetic alopecia as a predictive factor for COVID-19 severity.





## SHARED RESULTS



## SHARED RELIEF

### FOR ADULTS, ADOLESCENTS, AND CHILDREN (6 YEARS AND OLDER) WITH ATOPIC DERMATITIS WHO ARE INADEQUATELY CONTROLLED ON TOPICAL THERAPIES\*

- » First and **only targeted immunomodulator to specifically inhibit IL-4 and IL-13 signaling**, thereby reducing persistent underlying type 2 inflammation<sup>1,2</sup>
- » **Rapid and sustained improvement** in lesion extent and severity, pruritus intensity, and quality-of-life measures<sup>1,3-12</sup>
- » **Demonstrated safety profile in patients as young as 6 years old**  
— **No monitoring for organ toxicities required**<sup>1</sup>
  - Most common adverse reactions were injection site reactions, conjunctivitis, blepharitis, and oral herpes<sup>1</sup>

\***DUPIXENT** is indicated to treat adults and adolescents with moderate-to-severe atopic dermatitis, and children with severe atopic dermatitis aged 6–11 years old who are candidates for systemic therapy.<sup>1</sup>

References: 1. DUPIXENT Summary of Product Characteristics. 2021. 2. Gandhi NA et al. *Nat Rev Drug Discov* 2016; 15:35–50. 3. Blauvelt A et al. *Lancet* 2017; 389:2287–2303. 4. de Bruin-Weller M et al. Presentation at the 27th European Academy of Dermatology and Venereology Congress; 2018; September 12–16; Paris, France. 5. Simpson EL et al. *JAMA Dermatol* 2020; 156(1):44–56. 6. Paller AS et al. *Am J Clin Dermatol* 2020; 21:119–131. 7. Paller AS et al. *J Am Acad Dermatol* 2020; 83:1282–1293. 8. Data on file (AD\_1652 CDLQI). Sanofi and Regeneron Pharmaceuticals, Inc. 2019. 9. Bagel J et al. Poster presented at the 30th Congress of the European Academy of Dermatology and Venereology (EADV); 2021; September 29 – October 2, Virtual Meeting. Poster P0257. 10. Cork MJ et al. Poster presented at the Revolutionizing Atopic Dermatitis (RAD) Conference; 2021; June 13, Virtual Conference. Poster 468. 11. Blauvelt A et al. Poster presented at the Revolutionizing Atopic Dermatitis (RAD) Conference; 2021; June 13, Virtual Conference. Poster 469. 12. de Wijs LEM et al. *Br J Dermatol*. 2021; 185(3):555–562.

The content of this advertisement is based on the EU SmPC which can be accessed by clicking the link [here](#). Sanofi Genzyme and Regeneron do not recommend the use of its products in any manner inconsistent with that described in the label available in your country. Please refer to your local product labelling information before prescribing.

▼ This medicinal product is subject to additional monitoring. This will allow quick identification of new safety information. Healthcare professionals are asked to report any suspected adverse reactions.

SANOFI GENZYME 

REGENERON

© 2020 Sanofi and Regeneron Pharmaceuticals, Inc. All Rights Reserved. MAT-GL-2000500(v3.0) 10/2021

**DUPIXENT**   
(dupilumab)  
CONTINUOUS CONTROL

# Contents

+ EDITORIAL BOARD	6
+ WELCOME	9
+ FOREWORD	13
+ CONGRESS REVIEW	
Review of the European Academy of Dermatology and Venereology (EADV) Congress 2021	14
+ CONGRESS FEATURES	
Celebrating Outstanding Science at the European Academy of Dermatology and Venereology's 30 <sup>th</sup> Anniversary Congress Bilgiç et al.	24
Emerging Drugs in Dermatology Janet Nzisa	29
+ SYMPOSIUM REVIEWS	
The Benefits of Achieving Complete Control in Patients with Chronic Spontaneous Urticaria	35
Tailored Injection Techniques in the Mid- and Lower Face Using a Multilayering Approach	42
+ ABSTRACT REVIEWS	
Androgenetic Alopecia: Predictive Factor for COVID-19 Severity Rotaru et al.	51
Histopathological Findings In COVID-19 Necrotic Lesions Tammaro et al.	52
Sexually Transmitted Infections in Northern Greece During the COVID-19 Pandemic Sidiropoulos et al.	55
Treatment of Facial Cutaneous Leishmaniasis with Photodynamic Therapy Alamon-Reig et al.	57
Defining 'Freedom from Disease' in Plaque Psoriasis: Preliminary Outputs Using Delphi Methodology, Involving Nurses, Physicians, and People with Psoriasis Bewley and Deprez	59

<b>Diagnostic and Management Challenges of Erosive Pustular Dermatitis of the Scalp: A Retrospective Study in a Greek Population</b>	<b>61</b>
Siskou et al.	
<b>Nemolizumab Rapidly Relieves Itch and Sleep Disturbances in Patients with Prurigo Nodularis</b>	<b>63</b>
Ständer et al.	
<b>Chronic Urticaria: Clinical Characteristics, Epidemiology, and Impact on the Quality of Life of Patients</b>	<b>65</b>
Saad et al.	
<b>Blueberry Muffin Baby Secondary to a Ganglioneuroblastoma: A Case Report</b>	<b>66</b>
Montero-Vilchez et al.	
<b>Features of the Course of Condyloma Acuminata in Women Against the Background of Herpesvirus Infections</b>	<b>67</b>
Porsokhonova et al.	
<b>Overlapping DRESS and Stevens Johnson Syndrome: A Case Report</b>	<b>69</b>
Jihane et al.	
<b>+ CONGRESS INTERVIEWS</b>	
<b>Dedee Murrell</b>	<b>71</b>
<b>Marie-Aleth Richard</b>	<b>75</b>
<b>+ INTERVIEWS</b>	
<b>Peter Lio</b>	<b>77</b>
<b>Roxana Daneshjou</b>	<b>80</b>
<b>+ FEATURE</b>	
<b>Eleven Myths on Nail Melanoma</b>	<b>83</b>
Eckart Haneke	
<b>+ ARTICLES</b>	
<b>Editor's Pick: Botulinum Toxins in Medical and Cosmetic Dermatology</b>	<b>87</b>
Juhász et al.	
<b>Mosaicism in Tuberous Sclerosis Complex: A Case Report, Literature Review, and Original Data from Danish Hospitals</b>	<b>98</b>
Nagel et al.	
<b>Emerging Treatment Regimens in Psoriasis: Are There Advantages Over Current Biologic Therapies?</b>	<b>106</b>
Nenow et al.	

# Editorial Board

## Editor-in-Chief

Dr Simone Ribero

University of Turin, Italy

## Editorial Board

Dr Michael Gold

The Chicago Medical School, USA

Dr Jennifer Cather

Modern Research Associates, USA

Dr Vishalakshi Viswanath

Rajiv Gandhi Medical College, India

Dr Richard Warren

University of Manchester, UK

Prof Francesca Farnetani

Univeristy of Modena and Reggio Emilia, Italy

Dr Hassan Galadari

United Arab Emirates University, United Arab Emirates

Dr Jaishree Sharad

Skinfinti Aesthetic Skin and Laser Clinic, India

Prof Alin Laurentiu Tatu

“Dunărea de Jos” University of Galati, Romania

Prof Des Tobin

University College Dublin, Ireland

[VIEW IN FULL](#) ←

## Aims and Scope

EMJ is an online only, peer-reviewed, open access general journal, targeted towards readers in the medical sciences. We aim to make all our articles accessible to readers from any medical discipline.

EMJ allows healthcare professionals to stay abreast of key advances and opinions across Europe.

EMJ aims to support healthcare professionals in continuously developing their knowledge, effectiveness, and productivity. The editorial policy is designed to encourage discussion among this peer group.

EMJ is published quarterly and comprises review articles, case reports, practice guides, theoretical discussions, and original research.

EMJ also publishes 16 therapeutic area journals, which provide concise coverage of salient developments at the leading European congresses. These are published annually, approximately 6 weeks after the relevant congress. Further details can be found on our website: [www.emjreviews.com](http://www.emjreviews.com)

## Editorial Expertise

EMJ is supported by various levels of expertise:

- Guidance from an Editorial Board consisting of leading authorities from a wide variety of disciplines.
- Invited contributors are recognised authorities from their respective fields.
- Peer review, which is conducted by EMJ's Peer Review Panel as well as other experts appointed due to their knowledge of a specific topic.
- An experienced team of editors and technical editors.

## Peer Review

On submission, all articles are assessed by the editorial team to determine their suitability for the journal and appropriateness for peer review.

Editorial staff, following consultation with either a member of the Editorial Board or the author(s) if necessary, identify three appropriate reviewers, who are selected based on their specialist knowledge in the relevant area.

All peer review is double blind.

Following review, papers are either accepted without modification, returned to the author(s) to incorporate required changes, or rejected.

Editorial staff have final discretion over any proposed amendments.

## Submissions

We welcome contributions from professionals, consultants, academics, and industry leaders on relevant and topical subjects.

We seek papers with the most current, interesting, and relevant information in each therapeutic area and accept original research, review articles, case reports, and features.

We are always keen to hear from healthcare professionals wishing to discuss potential submissions, please email: [editorial.assistant@emjreviews.com](mailto:editorial.assistant@emjreviews.com)

To submit a paper, use our online submission site: [www.editorialmanager.com/e-m-j](http://www.editorialmanager.com/e-m-j)

Submission details can be found through our website: [www.emjreviews.com/contributors/authors](http://www.emjreviews.com/contributors/authors)

## Reprints

All articles included in EMJ are available as reprints (minimum order 1,000). Please contact [hello@emjreviews.com](mailto:hello@emjreviews.com) if you would like to order reprints.

## Distribution and Readership

EMJ is distributed through controlled circulation to healthcare professionals in the relevant fields across Europe.

## Indexing and Availability

EMJ is indexed on DOAJ, the Royal Society of Medicine, and Google Scholar<sup>®</sup>; selected articles are indexed in PubMed Central<sup>®</sup>.

EMJ is available through the websites of our leading partners and collaborating societies.

EMJ journals are all available via our website: [www.emjreviews.com](http://www.emjreviews.com)

## Open Access

This is an open-access journal in accordance with the Creative Commons Attribution-Non Commercial 4.0 (CC BY-NC 4.0) license.

## Congress Notice

Staff members attend medical congresses as reporters when required.

## This Publication

ISSN 2054-6211

EMJ Dermatology is published once a year. For subscription details please visit: [www.emjreviews.com](http://www.emjreviews.com)

All information obtained by EMJ and each of the contributions from various sources is as current and accurate as possible. However, due to human or mechanical errors, EMJ and the contributors cannot guarantee the accuracy, adequacy, or completeness of any information, and cannot be held responsible for any errors or omissions. EMJ is completely independent of the review event (EADV 2021) and the use of the organisations does not constitute endorsement or media partnership in any form whatsoever.

Front cover and contents photograph: Berlin, Germany, home of the EADV 2021. © noppasinw / 123rf.com

# EMJ Dermatology 9.1

## **Chairman of Advisory Board**

Prof Jonathan Sackier

## **Managing Director**

Dan Scott

## **Chief Commercial Officer**

Daniel Healy

## **Executive Assistant**

Samantha Knights

## **Head of Marketing**

Marc Koskela

## **Key Account Director**

Pavan Ramrakha

## **Performance Manager**

Darren Brace

## **Project Team Leader**

Robert Hancox

## **Senior Project Managers**

Kelly Byrne, Drew Dirvin, Nabihah Durrani,  
Millie McGowan, Max Roy, Ben Wilcock

## **Project Managers**

Lee Bourke, George Dawson, Emilie De Meritens,  
Rebecca Harrison, Andrew Hodding, Mark Kirwan,  
Lewis Mackie, Thomas Madden, Nishal Mohanlal,  
Jack Moore, Billy Nicholson, Aleksandar Popovic,  
Julia Porzuc

## **Sales Administrator**

Jannet Ip

## **Client Services Manager**

Caleb Wright

## **Client Services Senior Project Managers**

Vanessa Frimpong, Alexander Skedd

## **Client Services Associate Project Managers**

Jessica Alcock, Andrew Le Baigue, Monique  
Fernandes, Nicola Ip, William Lambert,  
Kealan McCrarren, Natasha Moriarty, Ben Whitcher

## **Head of Special Projects**

Jayne Logan

## **Finance Manager**

Antony Kindell

## **Credit Controller**

Ana Testemitanu

## **Recruitment Manager**

Melissa Leeks

## **Head of Operations**

Keith Moule

## **Operations Manager**

Nikki Curtis

## **Operations Assistants**

Satkartar Chaggar, Jeramel Corsino,  
April McCaffrey

## **Business Analyst**

Rajdeep Bhangoo

## **Editor (EMJ)**

Evgenia Koutsouki

## **Editor (GOLD)**

Helena Beer

## **Editorial Managers**

Katherine Colvin, Anaya Malik

## **Content & Editorial Executive**

Isabel O'Brien

## **Content & Editorial Assistants**

Cheyenne Eugene, Jade Williams

## **Copy Editors**

Millie Giles, Kirsty Hewitt, Jaki Smith

## **Editorial Assistants**

Evan Kimber, Natasha Meunier-McVey, Janet Nzisa,  
Heeral Patel, Robin Stannard, Theo Wolf

## **Head of Design**

Tian Mullarkey

## **Design Manager**

Stacey Rivers

## **Graphic Designers**

Gennaro Draisci, Roy Ikoroha, Emma Rayner

## **Junior Designer**

Steven Paul

## **Digital and Data Innovation Manager**

Louis Jonesco

## **Digital and Database Analyst**

Irina Surducan

## **SEO Manager**

Nilla Scaramozzino

## **Marketing Co-ordinator**

Noah Banienuba

## **Marketing Assistants**

Annabel Gibson, Holly Kraiss

## **Video Editor**

Dominic Garwood

# Welcome

Dear Readers,

Welcome to the latest issue of *EMJ Dermatology*. This open-access eJournal is packed with the most important developments in the speciality, including peer-reviewed articles and exclusive interviews with internationally renowned experts. Further, we are excited to share with you an in-depth review of this year's virtual European Academy of Dermatology and Venereology (EADV) Congress, alongside abstract review summaries from the 30<sup>th</sup> iteration of this world-leading event.

The Editor's Pick for this publication is a fascinating manuscript by Juhász et al., titled 'Botulinum Toxins in Medical and Cosmetic Dermatology'. The authors conducted an extensive and up-to-date retrospective review of the on- and off-label applications of botulinum toxin in the dermatologic field and highlighted the need for well-developed clinical trials to determine the true clinical efficacy of botulinum toxin in the off-label setting, as well as potential long-term safety concerns.

For those who were unable to attend EADV's 2021 Congress, please enjoy our comprehensive review of this fantastic event. Summaries of stand-out abstract reviews are included in this issue, with topics covering erosive pustular

dermatosis of the scalp, chronic urticaria, and more. In addition, our unique EADV-written feature, which provides an overview of their 30<sup>th</sup> Anniversary Congress, is another valued addition and not to be missed. The same is true of our compelling in-house feature, based on the 'Emerging Drugs in Dermatology' congress session. These are included alongside interviews with Dedee Murrell and Marie-Aleth Richard, two eminent EADV board members.

EMJ also spoke with Peter Lio and Roxana Daneshjou about subjects such as recent advances in the management of atopic dermatitis, the effects of the COVID-19 pandemic on the field of dermatology, and the introduction of artificial intelligence into the discipline.

I hope that our superb selection of hand-picked articles, case reports, abstracts, and interviews provide thought-provoking and essential information for all dermatologists, and that you enjoy reading them as much as I did.

Finally, I would like to thank all collaborators, contributors, and the Editorial Board members for their excellent work in creating the 2021 issue of *EMJ Dermatology*. The EMJ team has provided a plethora of innovative, multidisciplinary journals in 2021 and I am confident we shall continue supplying high-quality content throughout 2022.

**EMJ Editorial Team**

**EMJ**



# FIGHT



# FIGHT DIFFERENT



**Abbreviated Prescribing Information for Kyntheum® 210mg solution for injection in prefilled syringe**  
Please refer to the full Summary of Product Characteristics (SmPC) approved in your country before prescribing. ▼ This medicinal product is subject to additional monitoring. This will allow quick identification of new safety information. Healthcare professionals are asked to report any suspected adverse reactions. **Indication:** Treatment of moderate to severe plaque psoriasis in adult patients who are candidates for systemic therapy. **Active ingredient:** Each pre-filled syringe contains 210mg brodalumab in 1.5ml solution. 1ml solution contains 140mg brodalumab. **Dosage and administration:** Posology: Adults: The recommended dose is 210mg administered by subcutaneous injection at weeks 0, 1, and 2 followed by 210mg every 2 weeks. Consideration should be given to discontinuing treatment in patients who have shown no response after 12-16 weeks of treatment. Some patients with initial partial response may subsequently improve with continued treatment beyond 16 weeks. Each pre-filled syringe is for single use only. Elderly: No dose adjustment recommended. Hepatic and renal impairment: No dose recommendations can be made. Children and adolescents below the age of 18 years: Safety and efficacy of Kyntheum have not been established. Method of administration: Subcutaneous (SC) injection. Kyntheum should not be injected into areas where the skin is tender, bruised, red, hard, thick, scaly, or affected by psoriasis. The pre-filled syringe must not be shaken. After proper training in SC injection technique, patients may self-inject Kyntheum when deemed appropriate by a physician. Patients should be instructed to inject the full amount of Kyntheum according to the instructions provided in the package leaflet. **Contraindications:** Hypersensitivity to the active substance or to any of the excipients. Active Crohn's disease. Clinically important active infections (e.g. active tuberculosis). **Precautions and warnings:** *Inflammatory bowel disease (including Crohn's disease and ulcerative colitis):* Cases of new or exacerbations of inflammatory bowel disease have been reported with IL-17 inhibitors. Therefore, Kyntheum is not recommended in patients with inflammatory bowel disease. If a patient develops signs and symptoms of inflammatory bowel disease, or experiences an exacerbation of pre-existing inflammatory bowel disease, Kyntheum should be discontinued and appropriate medical management should be initiated. *Suicidal ideation and behaviour:* Suicidal ideation and behaviour, including completed suicide, have been reported in patients treated with Kyntheum. The majority of patients with suicidal behaviour had a history of depression and/or suicidal ideation or behaviour. A causal association between treatment with Kyntheum and increased risk of suicidal ideation and behaviour has not been established. Carefully weigh the risk and benefit of treatment with Kyntheum for patients with a history of depression and/or suicidal ideation or behaviour, or patients who develop such symptoms. Patients, caregivers and families should be advised of the need to be alert for the emergence or worsening of depression, suicidal ideation, anxiety, or other mood changes, and they should contact their healthcare provider if such events occur. If a patient suffers from new or worsening symptoms of depression and/or suicidal ideation or behaviour is identified, it is recommended to discontinue treatment with Kyntheum. *Hypersensitivity reactions:* Rare cases of anaphylactic reactions have been reported in the post-marketing setting. In the event of an anaphylactic reaction, or any other serious allergic reaction,

administration of Kyntheum should be discontinued and appropriate therapy initiated. *Infections:* Kyntheum may increase the risk of infections. Caution should be exercised when considering the use of Kyntheum in patients with a chronic infection or a history of recurrent infection. Patients should be instructed to seek medical advice if signs or symptoms suggestive of an infection occur. If a patient develops a serious infection, they should be closely monitored and Kyntheum should not be administered until the infection resolves. Kyntheum should not be given to patients with active tuberculosis. Anti-tuberculosis therapy should be considered prior to initiation of Kyntheum in patients with latent tuberculosis. *Vaccinations:* It is recommended that patients be brought up-to-date with all immunisations in accordance with local immunisation guidelines prior to initiation of treatment with Kyntheum. Live vaccines should not be given concurrently with Kyntheum. The safety and efficacy of Kyntheum in combination with immunosuppressants, including biologics, or phototherapy have not been evaluated. **Drug interactions:** Live vaccines should not be given concurrently with Kyntheum. **Fertility, pregnancy and lactation:** *Women of childbearing potential:* Use an effective method of contraception during treatment and for at least 12 weeks after treatment. *Pregnancy:* There are no or limited amount of data from the use of brodalumab in pregnant women. As a precautionary measure, it is preferable to avoid the use of Kyntheum in pregnancy. Benefit risk for exposure of the infant to live vaccines following third trimester exposure to Kyntheum should be discussed with a physician. *Breast-feeding:* It is unknown whether brodalumab is excreted in human milk. A risk to the newborns/infants cannot be excluded. Whether to discontinue breastfeeding of discontinue Kyntheum therapy should be decided, taking into account the benefit of breast-feeding for the child and the benefit of therapy for the woman. **Fertility:** No data are available on the effect of brodalumab on human fertility. **Adverse reactions:** *Common (≥1/100 to <1/10):* Influenza, tinea infections (including tinea pedis, tinea versicolor, tinea cruris), headache, oropharyngeal pain, diarrhoea, nausea, arthralgia, myalgia, fatigue, injection site reactions (including injection site erythema, pain, pruritus, bruising, haemorrhage). *Uncommon (≥1/1,000 to <1/100):* Candida infections (including oral, genital and oesophageal infections), neutropenia, conjunctivitis. *Rare (≥1/10,000 to <1/1,000):* anaphylactic reaction. **See SmPC for a full list of adverse reactions.** **Precautions for storage:** Store in a refrigerator (2°C-8°C). Do not freeze. Keep the pre-filled syringe in the outer carton in order to protect from light. Kyntheum may be stored at room temperature (up to 25°C) once, in the outer carton, for a maximum single period of 14 days. Once Kyntheum has been removed from the refrigerator and has reached room temperature (up to 25°C) it must either be used within 14 days or discarded. **Marketing authorisation number and holder:** EU/1/16/1155/001, LEO Pharma A/S, Ballerup, Denmark. **Last revised:** July 2020

**Reporting of Suspected Adverse Reactions**  
Adverse reactions should be reported according to local guidelines.

All LEO Pharma trademarks mentioned belong to the LEO Group.  
© LEO Pharma A/S, Industriparken 55, DK-2750 Ballerup, Denmark.

PASI 100 at 12 weeks with Kyntheum®: 44% in AMAGINE-2 (n=612) and 37% in AMAGINE-3 (n=624) using NRI for missing data.<sup>1</sup>  
IL, interleukin; NRI, non responder imputation; PASI, Psoriasis Area and Severity Index.

Kyntheum® (brodalumab) is indicated for the treatment of moderate to severe plaque psoriasis in adult patients who are candidates for systemic therapy.<sup>2</sup> Kyntheum® is a fully human monoclonal antibody and the only biologic that selectively targets the IL-17 receptor subunit A.<sup>2-5</sup>

**kyntheum®**  
Brodalumab  
**IN THE FIGHT AGAINST PSORIASIS**  
**THINK RECEPTOR BLOCKADE**

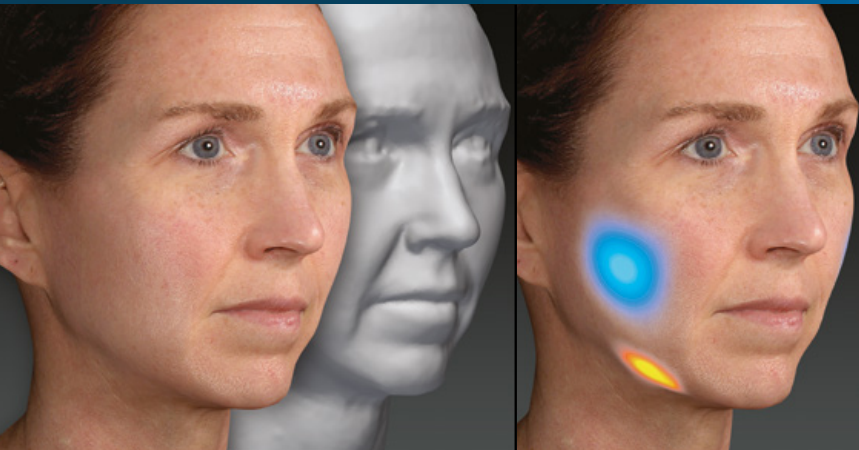**References:**

- Lebwohl M, et al. *N Engl J Med* 2015;373:1318-28.
- Kyntheum® (brodalumab) EU Summary of Product Characteristics. July 2020. Available from: <https://www.ema.europa.eu/en/medicines/human/EPAR/kyntheum>. Last Accessed: January 2021.
- Brembilla NC et al. *Front Immunol* 2018;9:1682.
- Pappu R et al. *Immunology* 2011;134:8-16.
- Baker KF and Isaacs JD. *Ann Rheum Dis* 2018;77:175-87.

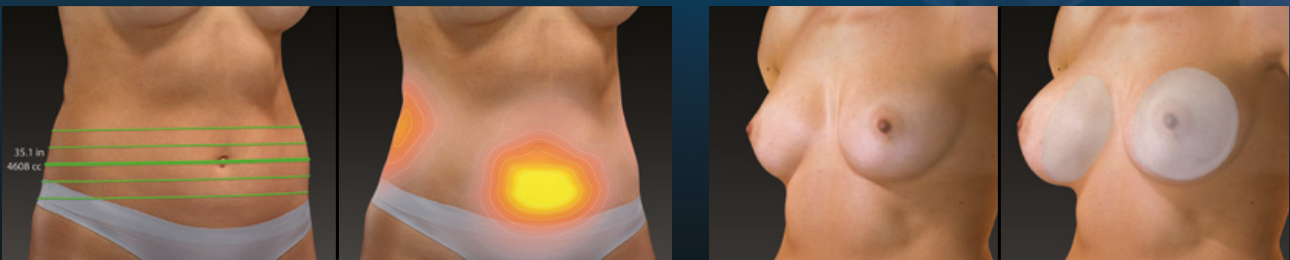


# VECTRA<sup>H2</sup>

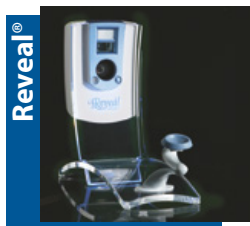The 3D imaging solution for  
**FACE, BREAST, and BODY.**



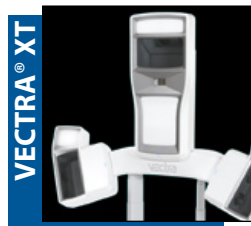*Photographic quality 3D images with unrivaled  
assessment and consultation software.*



VISIA<sup>®</sup>



Reveal<sup>®</sup>



VECTRA<sup>®</sup> XT



IntelliStudio<sup>®</sup>



IntelliStage<sup>™</sup>

IMAGING EXCELLENCE FROM



[www.canfieldsci.com](http://www.canfieldsci.com) | [info@canfieldsci.com](mailto:info@canfieldsci.com) | phone +1 973 434 1201 | phone (Europe) +49 521 329 856 0

VECTRA, VISIA, Reveal, IntelliStudio, and IntelliStage are trademarks of Canfield Scientific, Inc.

# Foreword

Dear Colleagues,

It is a great pleasure to introduce the latest issue of *EMJ Dermatology*. As with previous issues, you will find an immersive array of expertly written, peer-reviewed articles and case reports contained within these pages, which focus on the hot topics and highly relevant advances from across the discipline.

My Editor's Pick for this publication is the article by Juhász et al., titled 'Botulinum Toxins in Medical and Cosmetic Dermatology'. The authors conducted a comprehensive and up-to-date systematic review of the PubMed database using Preferred Reporting Items for Systematic Reviews and Meta-Analyses (PRISMA) guidelines in order to describe the multitude of on- and off-label applications of botulinum toxin in the dermatologic field. This paper makes valuable contributions to the existing body of literature and will be a stimulus for the EMJ readership.

For those who were unable to attend this year's European Academy of Dermatology and Venereology (EADV) Congress, or simply wish to relive the highlights, I highly recommend the Congress Review. This features late-breaking research news from the meeting on characteristic differences in chronic spontaneous urticaria in children

versus adults, the safety of biologics for psoriasis and the reasons for COVID-19 vaccine hesitancy in patients with psoriasis, and a link between genital warts and the human leukocyte antigen system.

The abstract review summaries are another valued edition and not to be missed. These cover topics such as the case of a newborn presenting with blueberry muffin syndrome secondary to ganglioneuroblastoma; chronic urticaria and its clinical characteristics, epidemiology, and impact on the quality of life of patients; and the diagnostic and management challenges of erosive pustular dermatosis of the scalp. These are included alongside exclusive interviews with two prominent EADV board members: Dedee Murrell and Marie-Aleth Richard. Finally, I would like to draw your attention to our compelling in-house feature based on the 'Emerging Drugs in Dermatology' congress session, as well as the unique EADV-written overview of their 30<sup>th</sup> Anniversary Congress.

I would like to thank all the authors, contributors, Editorial Board members, and reviewers for their outstanding work in creating the 2021 issue of *EMJ Dermatology*. I hope that this journal will prove an inspiring read and source of valuable information to assist in daily practice.



A handwritten signature in blue ink that reads "Desmond Tobin". The signature is fluid and cursive.

**Desmond Tobin**

Full Professor of Dermatological Science, Director of the Charles Institute of Dermatology, UCD School of Medicine, University College Dublin, Dublin, Republic of Ireland



# Congress Review

## Review of the European Academy of Dermatology and Venereology (EADV) Congress 2021

Location: EADV 2021 Virtual Congress  
Date: 29<sup>th</sup> September–2<sup>nd</sup> October 2021  
Citation: EMJ Dermatol. 2021;9[1]:15-22. Congress Review

THE EUROPEAN Academy of Dermatology and Venereology (EADV) 2021 Virtual Congress successfully brought together influential clinicians and academics from across the globe, working to achieve the EADV's aims of "improving the quality of patient care, furthering knowledge and education of dermatologists and venereologists globally through innovation, and advocating on behalf of the speciality and patients." Rather than viewing the online conference as an obligation, born out of necessity during the COVID-19 pandemic, the EADV instead transformed it into an opportunity. This was underscored by Alexander Stratigos, President of the EADV, during the welcome address: "As we move toward a post-pandemic era, our Academy is emerging ever stronger, with a vibrant day-to-day education programme that exploits the unique opportunities presented by digital learning." Stratigos added: "Through our evolving digital learning ecosystem, we are able to deliver a multitude of online

experiences, including webinars, enhanced digital communications, e-learning, and web-based tools to support continuous medical education and allow a broader diffusion of knowledge."

The EADV's 30<sup>th</sup> Anniversary Congress was notable for its Opening Plenary lectures. Margaritis Schinas, Vice President of the European Commission, provided his perspectives on Europe after the pandemic. In addition, Chris Griffiths, Foundation Professor of Dermatology at the University of Manchester, UK, delivered a talk entitled 'The Future of Dermatology'. The special Anniversary Edition also featured an important patient-focused session, which addressed the physical and emotional pain of skin disorders and considered what else dermatologists and venereologists can do in their daily practice, beyond proper medical treatments. Patient perspectives and expert opinions on incorporating novel solutions such as music and virtual reality into care practices were explored.

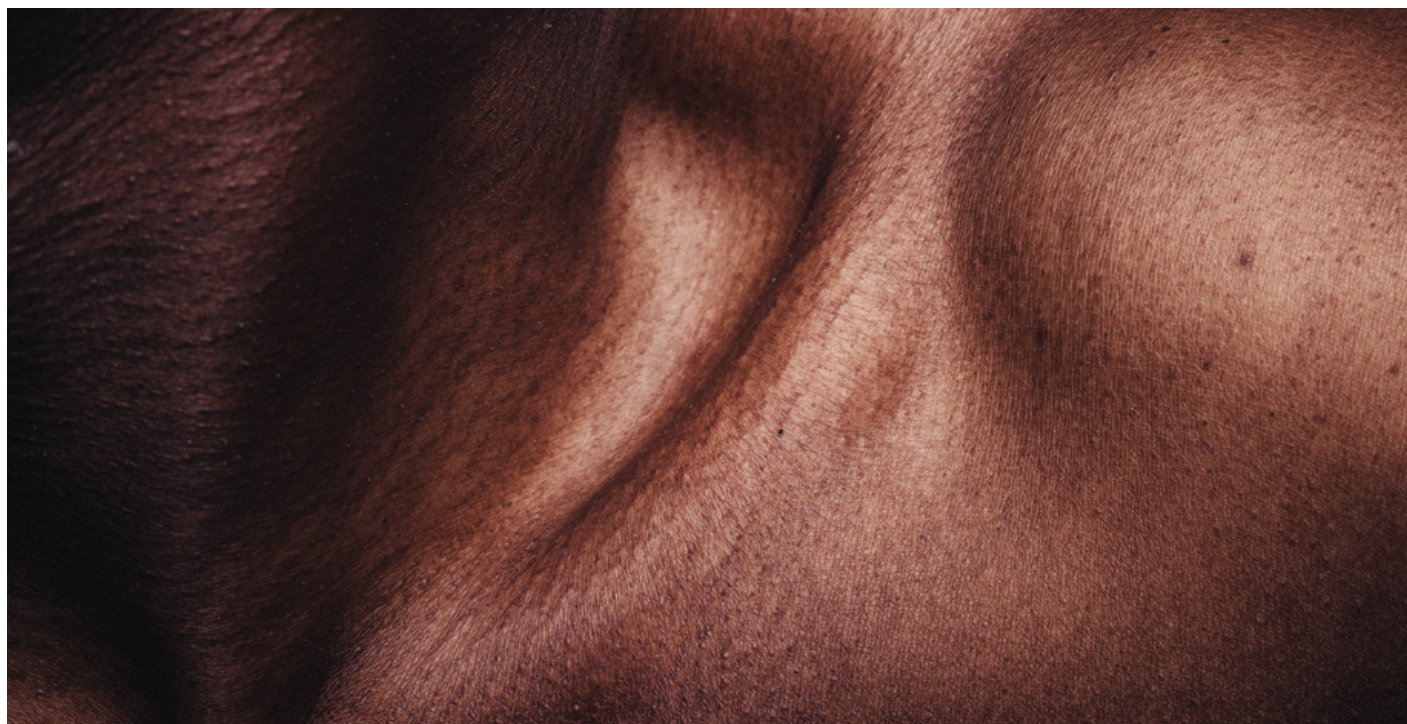
With over 550 prominent speakers, 10 plenary lectures, and 160 'simulive' sessions, participants were granted access to 4-days' worth of outstanding content. Presentation topics spanned across the discipline and included anti-fibrotic therapy for scleroderma, the classification of COVID-19-associated skin manifestations, the microbiome and its relevance in wound healing, the impact of pregnancy on autoimmune and inflammatory skin diseases, conventional and novel treatment modalities in rosacea, and the pathophysiology of atopic dermatitis. Keynote speakers at the 30<sup>th</sup> EADV Congress included Richard L. Gallo, distinguished Professor and founding Chairman of Dermatology, University of California, San Diego, California, USA, who spoke about emerging priorities for microbiome research, and Marta Szell, Head of Department of Medical Genetics at the Faculty of Medicine, University of Szeged, Hungary, who discussed the identification and functional characterisation of phenotype modifying genetic variants in CYLD cutaneous syndrome.

A multitude of abstracts were presented over the course of the meeting, providing insights across the various sub-disciplines of dermatology and venereology. Several standout abstracts have been summarised in this issue of *EMJ*

*Dermatology*, covering highly relevant topics such as diagnostic and management challenges of erosive pustular dermatosis of the scalp; chronic urticaria and its clinical characteristics, epidemiology, and impact on the quality of life of patients; and a case report documenting overlapping drug reaction with eosinophilia and systematic symptoms and Stevens-Johnson syndrome.

An overview of hot-topic EADV press releases can also be found within these pages, including a safety analysis of biological therapies for psoriasis and reasons for COVID-19 vaccine hesitancy in patients with psoriasis, characteristic differences in chronic spontaneous urticaria in children and adults and its impact on management strategies, a link between genital warts and the immune system, and the shortcomings of direct-to-consumer skin cancer detection apps. Each groundbreaking news story featured in this publication was based on research presented during the EADV 2021 Congress.

EMJ looks forward to welcoming you all, hopefully in-person, to Milan, Italy, next year for the 2022 meeting for the premier dermato-venereology conference. Until then, read on for our key scientific insights from the EADV 2021 Congress. ■



EADV 2021 REVIEWED →

# Portable Photodynamic Therapy Device Brings Possibility for Home Treatment of Basal Cell Carcinoma

**S**IGNIFICANT reduction in pain and efficacy levels comparable to a hospital stay are in the profile of a prototype photodynamic therapy (PDT) device for treating basal cell carcinoma (BCC). PDT is supported by multiple studies efficacious in its ability to destroy cancerous cells, but drawbacks have always been the pain experienced during treatment and lengthy hospital stay. A novel home device offers an attractive alternative for affected patients.

Current practice consists of two sessions in a hospital environment, 1-2 hours apart, every second week. The researchers commented on how impractical this schedule is for patients. Ana Gabriela Salvio, lead researcher in the investigation from the São Carlos Institute of Physics (IFSC), Brazil, emphasised the demand for a portable device in a country like Brazil: "Many patients need to travel more than 300 km to receive specialised dermatological treatment." She believes that "the global pandemic accelerated the need to develop this at-home treatment element, which has the potential to impact the treatment of BCC internationally."

Fifteen patients participated in this pilot study at the Amaral Carvalho Hospital, São Paulo, Brazil, and the IFSC. The first PDT session was performed in hospital, applying a 20% methyl aminolevulinate cream to the BCC lesion, illuminated for 20 minutes with a commercial red light-emitting diode device. Immediately after this, a light layer of cream was applied and the new portable irradiation device fixed to the skin.

This device is only the size of a coin and allowed patients to be sent home with instructions to turn on illumination after 1.5 hours and then off after 2 hours. Pain on a scale of severity from 1-10 was assessed every 3 minutes in hospital and self-reported every 20 minutes during home treatment, with median values compared between the treatment branches. Histological analysis revealed that at 30 days post-PDT clearance was 86.67%, similar to standard treatment, and pain was significantly lower in the treatment performed at home. These results suggest a more comfortable treatment with less pain is possible.

Obvious limitations exist in the small study size, apparent in this pilot study, but these will be addressed by the approved clinical trial with over 200 participants that will take place. The portable irradiation device under scrutiny in this pilot study is in the process of being patented in anticipation of the upcoming trial, which will certainly be followed closely by the oncology specialty. Salvio summarised the opportunities for this avenue of treatment: "Patients reporting much lower levels of pain from the at-home treatment is really encouraging, especially as it doesn't come at the cost of efficacy ... Our study results could have a hugely positive impact on the treatment of basal cell carcinoma in Brazil and the rest of the world."

This information was taken from a press release, dated 1<sup>st</sup> October 2021, part of the 30<sup>th</sup> annual EADV Congress. ■



# Skin Cancer Detection Apps Failing to Identify Life-Threatening Cancers

LIFE-THREATENING skin cancers are being missed by a direct-to-consumer machine-learning model. New research presented at the 30<sup>th</sup> EADV Congress has identified that the model incorrectly identified rare and aggressive cancers as low risk.

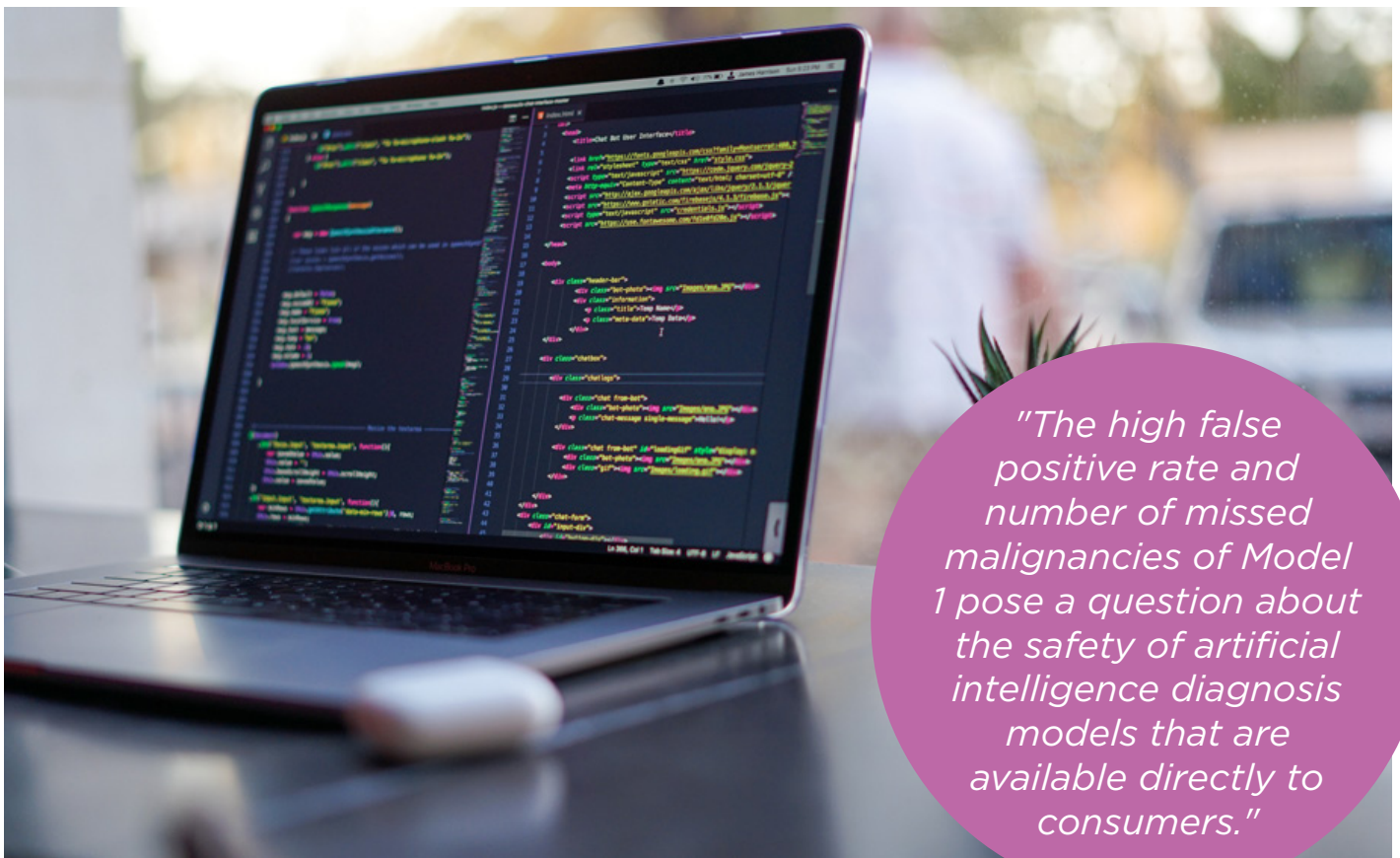Researchers in London created a dataset of 116 images of a variety of skin conditions, including some images of two rare and particularly aggressive forms of cancer, Merkel cell carcinoma and amelanotic melanoma. The images were then assessed by a machine-learning models. Model 1 was a certified medical device, sold directly to consumers through an app store and advertised as being able to diagnose 95% of skin cancers.

Results of the investigation demonstrated that Model 1 incorrectly identified 17.9% of Merkel cell carcinomas and 22.9% of amelanotic melanomas as low risk. Conversely, 62.2% of benign lesions were classified as high risk. Model 1's sensitivity

was 79.4% and its specificity was 37.7%. The high false positive rate and number of missed malignancies of Model 1 pose a question about the safety of artificial intelligence diagnosis models that are available directly to consumers.

Technology such as Model 1, which is available without the transparency of accurate performance metrics for rare but potentially life-threatening skin cancers, poses both an ethical and a practical question about how these products are certified, marketed, and eventually utilised by the public.

"The number of skin cancer detection apps available for consumer use is growing, but as demonstrated in this research, there must be more transparency around the safety and efficacy of these apps," stated Marie-Aleth Richard, EADV Board Member and Professor at the University Hospital of La Timone, Marseille, France. "Failure to be transparent could put lives at risk." ■



*"The high false positive rate and number of missed malignancies of Model 1 pose a question about the safety of artificial intelligence diagnosis models that are available directly to consumers."*



# Difference in Chronic Spontaneous Urticaria Presentation Between Children and Adults


**P**RACTICE-CHANGING research presented at the EADV Congress 2021 has articulated the differences in the presentation of chronic spontaneous urticaria (CSU) between children and adults. Urticaria is characterised by a raised itchy rash (commonly known as hives) and sometimes presents with angioedema. In CSU, there is no specific cause or trigger but hives are present for most days of the week for a period of 6 weeks or longer.

Findings of the recent research contradict the previously held belief that children were more likely to experience acute urticaria rather than chronic urticaria, and suggests that CSU is less severe in children than adults, with lower rates of angioedema and thyroid autoimmunity.

Researchers conducted a retrospective analysis of 755 patients with CSU, 171 children versus 580 adults. Data was compared to determine distinct characteristics between paediatric and adult patients with CSU. The data revealed a shorter disease duration, lower occurrence of angioedema (21.8% versus 59.8% [ $p < 0.001$ ]), and reduced incidence of thyroid autoimmunity (8.9% versus 25.4% [ $p < 0.001$ ]) in the paediatric group compared with the adult group. Furthermore, paediatric patients were found to respond more positively to antihistamines than adult patients did.

Results of the retrospective analysis further demonstrated that resistance to antihistamines was associated with anti-thyroid peroxidase positivity and the presence of angioedema and eosinopenia in the paediatric group whilst in the adult group the only identified association was eosinopenia.

“Our research is focused on identifying these differences [in CSU medical origins and co-existing diseases] to help inform future treatment of CSU and to provide more information on the effects of CSU on children, something which has previously been neglected in this field of research,” stated Professor Emek Kocaturk, Koc University Hospital, Istanbul, Turkey. ■



*“Findings of the recent research contradict the previously held belief that children were more likely to experience acute urticaria rather than chronic urticaria.”*

## Biologic Treatments and COVID-19 Impact on Patients with Psoriasis

**D**ATA presented at the EADV's 30<sup>th</sup> Congress explores the safety analysis of biologics by reviewing real-world data on vaccine hesitancy and exploring the impact of the COVID-19 pandemic on patients with psoriasis. The opinions towards the COVID-19 biologic-treated patients with psoriasis and/or psoriatic arthritis were studied by researchers in Spain. The data was collated from social media in order to reduce the limits of conventional hospital surveys that could be affected by the presence of a healthcare professional.

Between January and March, 10,922 social media posts from patients in the USA, UK, France, Spain, and Germany were identified and further reduced to 624 posts, which were analysed to provide insight. According to the results, hesitation towards the COVID-19 vaccine was due to concerns of safety, the worsening of underlying conditions, the lack of clinical trial data, possible side effects, and the effects on patients with autoimmune conditions. Additionally, the patients did not have information on the interaction of the COVID-19 vaccine with biologic therapy and its effect on patients who are immunocompromised. These results demonstrated the importance of education in order to tackle vaccine hesitancy.

According to research biological treatments for psoriasis are frequently linked to higher risk of

infections. Another real-world study carried out by researchers from the Netherlands, including 714 patients with psoriasis with up to 1,325 treatment episodes from the BioCAPTURE registry, sought to understand if there were any associations between biological therapies and increased risk of respiratory tract infections (RTI) and serious infections, including COVID-19. There were 2,224 RTIs and 63 serious infections. However, only 1.3% RTIs were considered serious. Furthermore, there was no association for risk of serious infection and a distinctive risk of RTI between the biologic treatments for psoriasis etanercept, infliximab, ustekinumab, secukinumab, ixekizumab, and guselkumab.

"Our analysis reveals no differences in risk of respiratory tract infections between biologics, including the newer IL-17 and IL-23 inhibitors, in a prospective psoriasis patients' cohort. In addition, our preliminary results suggest that biological treatments do not impact psoriasis patients' susceptibility to COVID-19 infections, although this needs to be further investigated," says Lara van der Schoot of the Department of Dermatology, Radboud University Medical Center, Nijmegen, the Netherlands, and lead author of the study. "These findings provide key clinical value and will help to guide patient decisions with regard to psoriasis treatment options and choice." ■





## Novel Study Shows the Prevalence of Skin Disease in Europe

*"Fascinating and valuable insights show that out of 21,401 participants in the general population, 47.9% reported to have at least one skin condition. "*

**S**KIN conditions can severely impact the quality of life and mental health of individuals, with aggravating symptoms including itchiness, redness, and dry skin. Dermatological conditions include acne, psoriasis, eczema, and many more. The prevalence of these conditions is common, but exactly how common are they? A novel survey, Burden of Skin Disease in Europe, conducted by the EADV aimed to find out. The objectives and the outcomes of the study were shared during the 30<sup>th</sup> annual EADV Congress.

Interestingly, before this study took place, there was very little information about the prevalence of skin conditions in Europe across the general population. Additionally, there was no reliable data on the impact of skin diseases on the quality of life of patients. This new study aimed to change this, and their key objective was to find out the prevalence of dermatological conditions across Europe, as well as find out how accessible dermatologists are to the general population and understand the reasons why an individual might visit a dermatologist.

The study involved 44,689 participants over the age of 18, across 27 countries in Europe, including the UK, Switzerland, and Norway. Fascinating and valuable insights show that out of 21,401 participants in the general population, 47.9% reported to have at least one skin condition. Further to this, out of those affected, individuals reported to have a median of two skin conditions, with fungal skin infection being the most common and affecting 9.07% of participants. The survey also highlighted other common conditions that affected 1 in 20 people, this includes eczema, alopecia, and acne.

The EADV Board Member leading the survey, Marie-Aleth Richard, Professor at the University Hospital of La Timone, Marseille, France, shared her final thoughts: "The fact that one in two people across Europe live with skin disease on a daily basis makes the skin the most affected organ in the body and as an organisation we are therefore committed to making skin disease a public health priority." ■

## Newly Discovered Link Between Immune System and Genital Warts

**G**ENITAL warts, also known as condyloma acuminata, is the most common sexually transmitted disease in the world. The condition presents itself as soft growths around the anus or genitals and is caused by the human papillomavirus (HPV). Over 80% of men and women who are sexually active are predicted to develop at least one HPV infection by 45 years old. An incredible breakthrough in HPV research was shared at the 30<sup>th</sup> EADV Congress that shows that there is a link between the immune system, specifically the human leukocyte antigen (HLA) system, and genital warts.

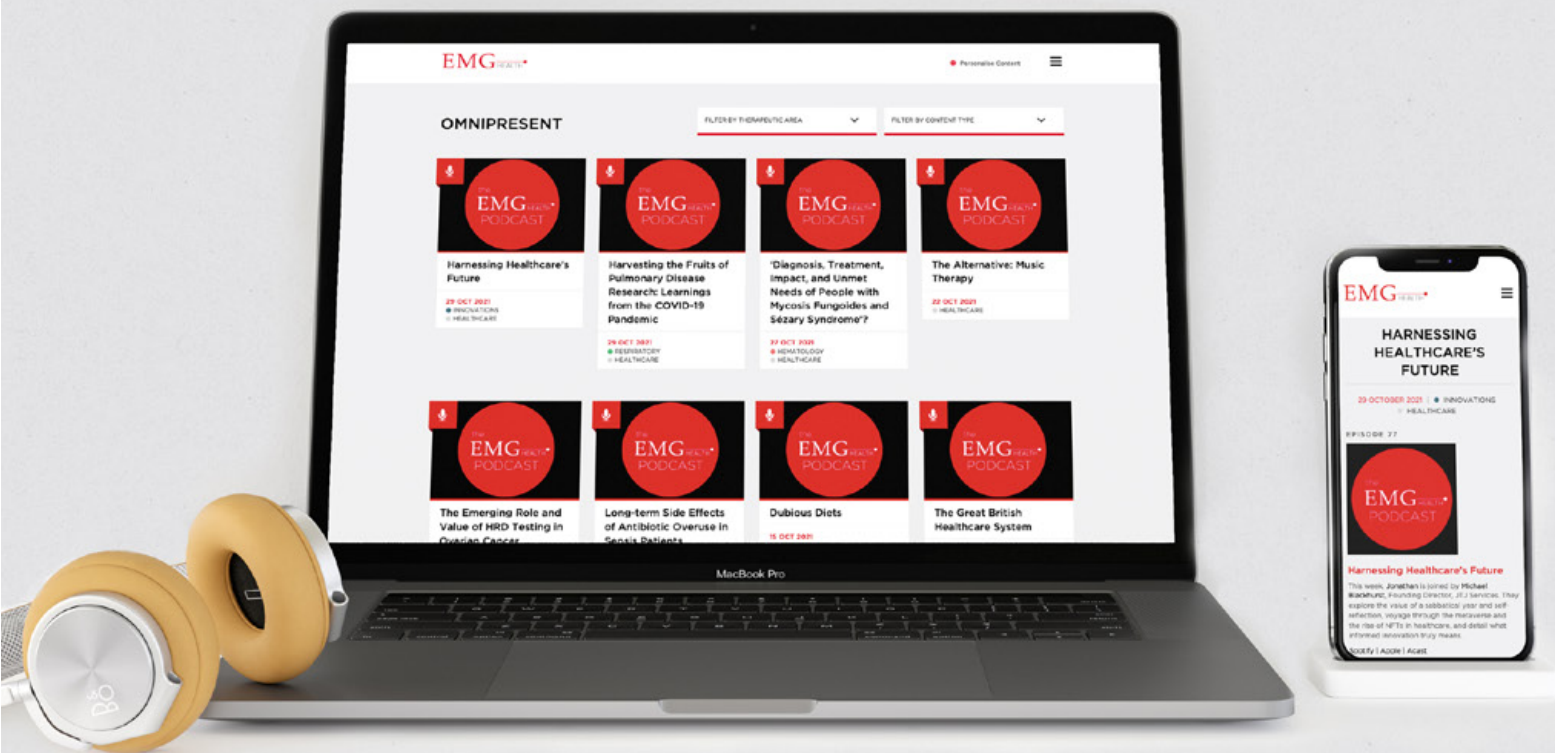
The study involved a large cohort of 65,791 participants who donated their blood. Out of this group, 4,199 participants had genital wart cases, the remaining participants were the control group. The genetic information of these individuals was assessed, particularly the HLA types and the link between genital warts.

Results from this unique study showed that there were 12 protective gene variations and 7 risk alleles in the cohort of patients. Participants who had risk alleles were less able to recognise the HPV virus and consequently were more likely to develop genital warts. On the other hand, those with protective alleles had a better immune response and were, therefore, able to recognise HPV effectively and were less likely to present with genital warts.

From these insightful findings, it can be determined that there is certainly a link between the HLA system and the development of genital warts. However, further research is needed to discover whether protective alleles can recognise specific HPV proteins. Mariano Suppa, EADV Board Member and Associate Professor at Université Libre de Bruxelles, Brussels, Belgium, shared her concluding remarks: “The promising results presented in this study are an exciting breakthrough, which could lead to potential avenues for future mRNA vaccinations against genital warts.” ■



*“The promising results presented in this study are an exciting breakthrough, which could lead to potential avenues for future mRNA vaccinations against genital warts.”*



# EMG-Health Podcasts

The EMG-Health Podcast aims to provoke conversations around the latest trends and innovations in healthcare, provide engaging and educational content for healthcare professionals, and hosts conversations with physician entrepreneur, Jonathan Sackier.

[Listen today](#)

[WWW.EMG-HEALTH.COM](http://WWW.EMG-HEALTH.COM)

EMG<sub>HEALTH</sub>

# Celebrating Outstanding Science at the European Academy of Dermatology and Venereology's 30<sup>th</sup> Anniversary Congress



## Authors:

Asli Bilgiç,<sup>1</sup> Ivan Bogdanov,<sup>2</sup> Paola Pasquali,<sup>3</sup> Mariano Suppa,<sup>4</sup> Marie-Aleth Richard,<sup>5</sup> Dedee F Murrell<sup>6,7</sup>

1. Department of Dermatology and Venereology, Akdeniz University, Faculty of Medicine, Antalya, Turkey
  2. Department of Dermatology and Venereology, Acibadem Cityclinic Tokuda Hospital, Sofia, Bulgaria
  3. Dermatology Department, Pius Hospital de Valls, Tarragona, Spain
  4. Department of Dermatology, Hôpital Erasme, Université Libre de Bruxelles, Brussels, Belgium
  5. Department of Dermatology, University Hospital of La Timone, Marseille, France
  6. Department of Dermatology, St George Hospital, Sydney, Australia
  7. Faculty of Medicine, University of New South Wales, Sydney, Australia
- \*Correspondence to [d.murrell@unsw.edu.au](mailto:d.murrell@unsw.edu.au)

## Citation:

EMJ Dermatol. 2021;9[1]:24-28.

THE ANNIVERSARY edition of the European Academy of Dermatology and Venereology's (EADV) 30<sup>th</sup> Congress was held between 29<sup>th</sup> September and 2<sup>nd</sup> October 2021. As COVID-19 remains a barrier to global travel, the EADV's 30<sup>th</sup> Anniversary Congress was staged virtually, providing access to the latest research, breakthroughs, and scientific advances to dermato-venereology professionals.

The ever first EADV Congress took place in Florence, Italy, in 1989 when the EADV was just 2 years old. It was hosted by the Academy's first ever President, Emiliano Panconesi. At that time, the EADV welcomed a small number of delegates, which grew to over 1,000 in just 2 years. The 29<sup>th</sup> EADV Virtual Congress in 2020 was the first to be organised in an all-virtual format.

Celebrating three decades of outstanding science, the 4-day scientific programme of the EADV's 30<sup>th</sup> Anniversary Congress, was fully packed with plenary lectures by renowned scientists; late breaking news sessions, with analysis of the latest published data; clinical updates; case discussions relevant for daily practice; and the latest trends in dermato-venereology, which were delivered by over 550 leading experts in 160 simu-live sessions

and 11 keynote lectures from thought leaders. The congress attracted over 9,000 participants from 120 countries.

The EADV is one of the most prominent and influential academies in the field of dermato-venereology. As a non-profit organisation with nearly 7,000 members across 116 different countries, the EADV provides a valuable service for every type of dermato-venereologist professional. It has re-established its activities as virtual meetings and webinars, online tools and innovative e-learning offerings, and enhanced its online communication by putting access to digital learning at the centre of its education strategy as a response to the COVID-19 pandemic.

## ADVOCACY

The EADV is also taking a leading role in promoting dermatology and venereology in European Union (EU) health policy to support the specialty to deliver better patient care. The EADV has identified two high priorities on the EU policy agenda for proactive advocacy: the new Europe's Beating Cancer Plan and Horizon Europe initiatives.

The first focus is on Europe's Beating Cancer Plan, which is mainly addressing priorities in skin cancer prevention and early detection. For this purpose, there have been a series of Policy Roundtables to create a patient centred approach to shape policies that support public awareness of skin cancer risk factors and help with prevention.

## Europe's Beating Cancer Plan

The EADV welcomes Europe's Beating Cancer Plan, which includes four main pillars: prevention, early detection, diagnosis and treatment, and survivorship. All are highly relevant for patients with skin cancer such as melanoma and non-melanoma skin cancers. Furthermore, the EADV also supports the efforts to prevent human papillomavirus (HPV)-induced cancers such as the HPV vaccination programme.

### SKIN CANCERS

Skin cancer is one of the most common cancers in the EU. In 2020, over 106,000 EU citizens were diagnosed with different forms of skin cancer, and more than 20,000 Europeans die from it annually. The cost of care for patients with skin cancer in European countries is estimated at 2.7 billion EUR annually and, because of this cost, the disease is also a considerable economic burden to healthcare systems. Thus, skin cancer was one of the important focuses of the EADV 30<sup>th</sup> Congress.

Harald Kittler, Medical University of Vienna, Austria, discussed what is 'atypical' when speaking about pigmented skin lesions. The term 'atypical' is used to indicate the relationship of a nevus to melanoma by indicating a greater risk of becoming melanoma. He suggested that a lesion should not be called 'atypical' as some think it has a higher risk of transformation; however, some 'typical' looking lesions can transform into melanomas. The suggested action is to follow the three-rule advice if you are uncertain: correlate (the dermoscopic image with the clinical one); compare (the dermoscopic images of all the pigmented lesions); and control (do a follow-up).

Furthermore, Rainer Hofman-Wellenhof, Medical University of Graz, Austria, spoke on the dermoscopic indicators for early melanomas: an atypical network, regression of more than 50%,

irregular hyperpigmented areas, angulated lines, and prominent skin markings.

Philipp Tschandl, Medical University of Vienna, Austria, presented an in-depth update on the use of artificial intelligence (AI) in dermatology. He gave insights into the use of AI in diagnosing, covering with no images; with clinical images; with dermoscopic images; in follow-up of images; in full-body photography; and finally in histology specimens. Limitations of AI models when it comes to precise and accurate detection were discussed.

The advantages and disadvantages of teleradiology were discussed by Peter Soyer, The University of Queensland, Australia, and founder of the International Society of Teledermatology (ISTD). He explained how the pandemic has impacted cancer diagnoses in the field of dermatology and other clinical fields. In Australia, there have been 145,000 less mammograms undertaken for screening breast cancer and up to 38% less early diagnoses of this disease. He further emphasised that healthcare professionals must rethink their ways of working in regard to their specialty, as there is now a new era, where every day work is getting closer to technological advances.

Despite concerns, the number of skin cancer detection apps available for consumer use is growing. Lloyd Steele et al. from Queen Mary University of London, UK, and the Blizzard Institute shared the results from their study, which assessed the performance metrics of two published machine-learning models for Merkel cell carcinoma and amelanotic melanoma. Both have reported an expert-level performance and one is already being sold directly to the public.<sup>1</sup> They further suggested that the current approval of models to the public, without any reported performance metrics for rare but potentially life-threatening skin cancers, is ethically questionable, while the question of sufficient accuracy for deployment remains an unanswered one. Thus, there must be more transparency around the safety and efficacy of these apps. These machine-learning models have potentially negative consequences at both a personal and societal level and could put lives at risk.

## SQUAMOUS CELL CARCINOMA

Squamous cell carcinoma (SCC) is one of the most common skin cancers and belongs to non-melanoma skin cancers group. Surgery remains the best option for treatment if complete removal is feasible, with acceptable morbidity. Ricardo Vieira, Dermatologist from Coimbra University Hospital, Portugal, discussed surgery in advanced SCC. The advanced SCC can be defined as a large tumour, invading tissues beyond subcutis, with poor differentiation, perineural spread, and located on chronic inflammatory conditions such as burn scars and chronic ulcers. Surgical margins should be at least 10 mm and microscopically controlled surgery should be performed when feasible and available. Flap repairs are not recommended if a tumour-free margin cannot be assured, and a delayed reconstruction is recommended in those cases. Microscopically controlled surgery has a better clearance of the tumour, and it is the best approach to removing tumours with perineural invasion; however, the fact that the frozen sections are difficult to interpret still have to be taken into account, and the procedure is limited to tumours with no extension to deep structures.

## MELANOMA

Eduardo Nagore, Instituto Valenciano de Oncología, Valencia, Spain, discussed Mohs surgery and its areas of usage. He emphasised that Mohs surgery has been proved to be an excellent choice for the treatment of lentigo maligna (LM) and LM melanoma. However, it is uncertain if all head and neck LM/LM melanoma are candidates for this surgical technique, or only those with specific characteristics such as lesions with ill-defined borders or tumours with a severe sun-damage background. The use of Mohs surgery is promising in some of the acral lentiginous melanomas such as nail unit melanomas, which are difficult to operate due to their specific anatomical characteristics. However, its use remains with doubtful usefulness in lesions located on the soles. For malignant melanomas located on the trunk and the extremities, there is no proven benefit from the use of micrographic surgery.

In regard to optimising Mohs surgery procedures, Cristian Navarrete-Dechent, Pontificia Universidad Católica de Chile, Chile, further discussed imaging techniques. As tumours that are candidates for Mohs surgery are usually associated with subclinical extensions, the most commonly used imaging techniques are wide-field images (e.g., CT and MRI), which are not the best tools for microscopic and subclinical diseases. He suggested that the combination of reflectance confocal microscopy and optical coherence tomography imaging may be excellent tools for a real-time, non-invasive, comprehensive 3D sampling *in vivo* and improve the diagnostic accuracy and margin assessment of basal cell carcinoma and LM prior to Mohs surgery.

## HUMAN PAPILLOMAVIRUS INFECTION

HPV is the most widespread and common sexually transmitted disease worldwide, with more than 80% of sexually active women and men expected to acquire at least one HPV infection by the age of 45 years. They manifest as genital warts (condyloma acuminata), which are soft fleshy growths that usually develop around the genitals or anus. HPV is also pre-cancerous for various cancers including cervical cancer, penile cancer, anal cancer, and in some cases of oral and throat cancer as well as others.

Researchers from Denmark (Pernille Lindsø Andersen et al., Næstved Hospital) have uncovered a link between genital warts and the human leukocyte antigen system, which is part of the genetic region that holds genes essential for normal functioning of immune response, helping to distinguish between 'foreign items' called antigens (which cause the body to make an immune response). Their findings suggest that genetic alterations in the human leukocyte antigen system influence the risk of genital warts. They identified 12 protective gene variations (odds ratios: 0.4–0.8), in the preliminary cohort and seven risk alleles (odds ratio: 1.1–1.3) in the present cohort. Individuals with risk alleles were less successful at recognising the HPV virus and, therefore, more likely to present with genital warts. Conversely, participants with protective alleles had better immune responses and were more effective at recognising HPV.



## VACCINES

Steve Pascolo, University of Zurich, Switzerland, trained as an immunologist at the Pasteur Institute, Paris, France, presented the past (initial preclinical and clinical studies of vaccines based on synthetic mRNA, characteristics), the present (synthetic mRNA vaccines against COVID-19), and the future of mRNA vaccines (e.g., design of anticancer vaccines). He also went well beyond their use as vaccines discussing the great potential of synthetic mRNA in medicine. Synthetic mRNA vaccines have proven, as a result of the COVID-19 pandemic, to be fast and easy to produce as well as safe and efficient. This format is now expected to be largely exploited to create new vaccines (against infectious agents as well as against cancer), and also to replace previously existing vaccines that presented challenges in production, storage, efficacy, and side effects.

## BIOLOGICS, INFECTIONS, AND VACCINES

Biologics are increasingly used for psoriasis. They are often thought to be associated with an increased risk of infections. However, different risks were reported in previous studies. COVID-19 has resulted in attention for risk of serious infections (SI) and respiratory tract infections (RTI) in this population. Lara van der Schoot et al., Radboud University Medical Center, Nijmegen, the Netherlands, showed the results of their study,<sup>2</sup> which evaluated the differential effect of biological therapies on risk of SI and RTI, including severe acute respiratory coronavirus 2 infections among patients with psoriasis who were treated with currently available biologics in a real-world setting. The study included 714 patients with 1,325 treatment episodes. Adjusted analyses showed no differential risk of SI or RTI between adalimumab, etanercept, infliximab, ustekinumab, secukinumab, ixekizumab, and guselkumab in a daily practice cohort of patients with psoriasis.

## THE BURDEN OF SKIN DISEASE

Little is known about the prevalence of skin diseases in the general population across Europe. Moreover, there is a lack of solid, objective, and homogeneous data at the European level on

the impact skin diseases have on quality-of-life, including stigmatisation, or on the perception of and access to dermatologists.

The EADV has, therefore, commissioned an adult population-based survey. The Burden of Skin Disease in Europe evaluated the prevalence of dermatologic or venereological problems across Europe and documented the reasons for consulting a dermatologist, impact of skin disease on patients, public perception of skin diseases, skin disease care pathways, prescribed treatment, and confidence in dermatologists. Marie-Aleth Richard, University Hospital of La Timone, Marseille, and EADV Board Member, led the survey, and shared preliminary results of the study, which is the largest ever undertaken of its kind in Europe. Data has now been collected from 44,689 adults from 27 European countries, as well as the UK and Switzerland. Preliminary findings show that among 21,401 members of the general population, 47.9% of people 18 years of age or older self-reported at least one skin condition. The most common skin condition among those surveyed is fungal skin infection, affecting almost one in 10 people (9.07%). Other common conditions, each affecting more than one in 20 people, were atopic dermatitis (eczema; 5.34%), alopecia (5.22%), and acne (5.49%). Furthermore, skin symptoms or unpleasant skin sensations, including tightness and itchiness, as a specific consultation requests were reported by 20% of people aged 18 years or older. The study findings after full-data analysis can act as a guiding light to have a firm understanding of the burden of skin diseases on patients and the healthcare systems that further guide the health policies.

Although the congress might have ended, content remains accessible to registered delegates to watch on demand. The scientific content remains available 3 months after the congress, and EADV members have access to the content of previous congress and symposiums.

Healthcare professionals are all waiting to meet personally in the future as personal interactions are an essential part of scientific discussions. However, moving beyond the COVID-19 pandemic era, the EADV plans to retain, enhance, and build upon many of the positive innovations that helped the organisation to adapt their offerings

for healthcare professionals and patients during that time. Virtual activities will continue to be an important component of future EADV scientific events, allowing for broader attendance and a

greater diffusion of knowledge to help members both optimise patient care and deliver the advances made in clinical research in the many different fields.

## References

1. Steele L et al. Do AI models recognise rare, aggressive skin cancers? An assessment of a direct-to-consumer application in the diagnosis of Merkel cell carcinoma and amelanotic melanoma. *J Eur Acad Dermatol Venereol.* 2021;DOI:10.1111/jdv.17517.
2. Van Der Schoot L et al. Risk of respiratory tract infections and serious infections in psoriasis patients treated with biologics: results from the BioCAPTURE registry. Available at: <https://s3.eu-central-1.amazonaws.com/cst.eadv/eadv2021/abstracts/24432.html.pdf>. Last accessed: 21 October 2021.

FOR REPRINT QUERIES PLEASE CONTACT: [INFO@EMJREVIEWS.COM](mailto:INFO@EMJREVIEWS.COM)

# Emerging Drugs in Dermatology

**Janet Nzisa**

Editorial Assistant

Citation: EMJ Dermatol. 2021;9[1]:29-33.



The ANNUAL European Academy of Dermatology and Venereology (EADV) Virtual Congress 2021 featured the latest updates on emerging drugs in dermatology. Presentations covered a wide range of topics such as immunotherapy versus targeted therapy in melanoma, targeting cytokine pathways in psoriasis, emerging biologics, and the promise of personalised medicine in dermatology.

## IMMUNOTHERAPY VERSUS TARGETED THERAPY IN MELANOMA

Melanoma is a prominent type of skin cancer and treatment varies depending on the mutation and malignancy of the disease. The overall survival (OS) rate of metastatic melanoma is 35-50%. Pablo Fernandez-Peñas, Westmead Hospital, Sydney Medical School, Australia, opened the session by stating the discussion was based on *BRAF*-mutated melanoma. Fernandez-Peñas attested that targeted therapies are not beneficial for *BRAF* wild-type melanoma. The two approaches in treatments currently used in metastatic melanoma are adjuvant and neoadjuvant treatment. According to recent data on non-resectable melanoma, the advanced stage of metastatic melanoma, immunotherapies supposedly have a long-term survival benefit. The data presented by Fernandez-Peñas on ipilimumab and nivolumab displayed a 5-year OS rate of 52%. He compared these data to targeted therapy using dabrafenib and trametinib, which showed an OS rate of 34% in 5 years. A meta regression analysis comparing both targeted therapies and immunotherapy drugs demonstrated that a combination of ipilimumab

and nivolumab has a statistically significant greater OS rate compared to dabrafenib and trametinib. Additionally, results of an ongoing meta-analysis carried out on five randomised clinical trials showed that a combination of targeted and immunotherapy, known as triple therapy, could be effective in the treatment of metastatic melanoma, but could cause increased toxicity.

In conclusion, Fernandez-Peñas confirmed that immunotherapy as a first-line melanoma treatment had a superior long-term outcome. However, targeted therapies had rapid symptom control and higher chance of short-term response. Similar results have been observed in Stage III/IV melanoma with adjuvant therapy; however, there have been limitations in the current research, and further data need to be analysed to confirm these results. There are more novel targeted and immunotherapies in the horizon in Phase I and II stages of research. Other newer therapies for melanoma include viral vectors (e.g., T-VEC), T-cell therapies (e.g., CAR-T cells), and intratumoural therapies (e.g., TLR9).



## TARGETING CYTOKINE PATHWAYS IN PSORIASIS

Kamran Ghoreschi, Department of Dermatology, Venereology, and Allergology Charité Universitätsmedizin Berlin, Germany, began the session by stating that the immunology and genetic associations of psoriasis are well-understood. He presented emerging data and drugs for psoriasis that focused on IL-17 and IL-23 inhibitors. Bimekizumab was approved in 2021

and is an anti-IL17A, anti-IL-17F, and anti-IL17AF monoclonal antibody. Ghoreschi confirmed that bimekizumab had been tested against other established anti-psoriatic drugs such as secukinumab, adalimumab, and ustekinumab. The results show that bimekizumab efficacy is superior to these drugs, with greater clearance of skin compared to secukinumab and ustekinumab. Ghoreschi attested that it may be useful to switch from one IL-17 inhibitor to another, as some patients may lose their primary response after a

## EMERGING BIOLOGICS AND SMALL MOLECULES FOR ATOPIC DERMATITIS

period of exposure to one IL-17 inhibitor. He shared an example on the advisable sequence for IL-17 inhibitors: initial treatment with secukinumab; if a patient loses the primary response after 1-2 years, the healthcare professional should switch to ixekizumab or bimekizumab. Furthermore, there are novel emerging IL-17 inhibitors in the horizon such as netakimab (anti-IL-17A), CJM112 (anti-IL-17A/F), and sonelokimab (anti-IL-17A).

Finally, Ghoreschi shared recently published data on COVID-19 vaccination with anti-psoriatic treatment. The data involved patients currently using targeted biological monotherapy, methotrexate, versus healthy control subjects. Immunogenicity was evaluated before and on Day 28 ( $\pm 2$ ) after the BNT162b2 vaccine to analyse the spike-specific T-cell responses. The results showed neutralising activity against the wild-type severe acute respiratory syndrome coronavirus 2 was significantly lower in patients receiving methotrexate (median 50% inhibitory dilution [ $ID_{50}$ ]: 129) compared to the controls ( $ID_{50}$ : 317 [interquartile range: 213-487];  $p=0.0032$ ); however, it was preserved in patients receiving targeted biological monotherapy ( $ID_{50}$ : 269 [interquartile range: 141-418]). Cellular immune responses were induced in all groups and were not attenuated in patients receiving targeted biological monotherapy or methotrexate compared to the controls.

Atopic dermatitis (AD) is a common, chronic inflammatory disease. Richard Langley, Division of Clinical Dermatology and Cutaneous Science, Dalhousie University, Nova Scotia, Canada, began the presentation with a case study of a patient with wide-spread dermatitis. According to Langley, the patient would flare up and use steroids as treatment and, once the flares cleared up, he would stop the treatment and the flare would appear again; it was a vicious cycle. Langley stated that there was an unmet need for acute and long-term control in AD. The understanding of pathophysiology of dermatitis is evolving and therefore there is potential for fulfilling this unmet need. The two groups of emerging systemic therapies and biologics discussed by Langley were cytokine antagonists dupilumab (IL-4 and IL-13) and small molecules/JAK inhibitors (abrocitinib, baricitinib, and upadacitinib). There are ongoing Phase III trials with dupilumab for adult patients with moderate-severe AD. However, side effects have been observed such as nasopharyngitis, upper respiratory tract infections, and conjunctivitis.

Langley emphasised that JAK inhibitors by nature cannot be selective for a particular JAK; instead, they show preferential activity for certain





JAKs over others, although at sufficiently high concentrations they would likely inhibit all the JAKs. Abrocitinib shows higher selectivity for JAK 1 and 2; both baricitinib and upadacitinib have a higher selectivity for JAK 1. Results of a study for treatment with baricitinib 2 mg show a 75% reduction in Eczema Area and Severity Index (EASI-75) in patients' response at Week 16, 32, and 52 of 40%, 51%, and 49%, respectively. The safety profile of baricitinib was reassuring, with low rates of serious infections. Another study presented by Langley on the efficacy of abrocitinib (200 mg) plus a topical therapy among adolescents with moderate AD showed a faster response than dupilumab. Langley confirmed that the utilisation of this drug may be influenced by the desire for quicker responses and greater clearance of AD; however, tolerability issues should be considered. Langley emphasised the importance of the novel data and stated that the current results have been promising. However, the present data are short-term and long-term data would be beneficial in determining a treatment paradigm for acute AD.

## THE PROMISE OF PERSONALISED MEDICINE

Nicholas Reynolds, Dermatology and Director of Diagnostics, Newcastle University, UK, and Royal Victoria Infirmary, Newcastle upon Tyne,

UK, started his session by attesting that the efficacy of therapeutic agents is variable and largely unpredictable at times, with both primary and secondary failure. However, in cancer the genetic basis of the disorder has led to well-defined stratified medicine that has been adopted into clinical practise. According to Reynolds, this is harder in complex inflammatory disorders to progress well-defined biological treatments, although there have been some recent advancements. Using biomarker profile analysis, researchers can predict responders, non-responders, and patients who may develop adverse effects following a treatment. A 2016 psoriasis recommendation from the World Health Organization (WHO) stated that all patients should have access to comprehensive, individually adapted treatment; additionally, research on new treatments should focus on options that can be available globally. The Psoriasis Stratification to Optimise Relevant Therapy (PSORT) consortium are currently attempting to stratify biological therapies for patients with moderate-severe psoriasis. Reynolds emphasised the concept of 'P4 medicine', meaning predictive, preventative, personalised, and participatory medicine, which is widely used in clinical practice and would be highly beneficial to dermatology. In conclusion, future application of personalised medicine could provide more positive outcomes to patients in dermatology.



# cimzia<sup>®</sup>

(certolizumab pegol)

HER Life  
HER Way

CIMZIA<sup>®</sup> is indicated for the treatment of moderate to severe plaque psoriasis in adults who are candidates for systemic therapy.





# The Benefits of Achieving Complete Control in Patients with Chronic Spontaneous Urticaria

This congress report is based on six poster presentations that took place between 29<sup>th</sup> September and 2<sup>nd</sup> October 2021, as part of the 30<sup>th</sup> European Academy of Dermatology and Venereology (EADV) Annual Congress in Vienna, Austria

**Presenters:** Pedro A. Laires,<sup>1</sup> Jonathan A. Bernstein,<sup>2</sup> Ana Giménez-Arnau,<sup>3</sup> Marcus Maurer<sup>4</sup>

1. Novartis Pharma AG, Basel, Switzerland
2. University of Cincinnati College of Medicine and Bernstein Clinical Research Center, Cincinnati, Ohio, USA
3. Dermatology Department, Hospital del Mar, IMIM, Universitat Autònoma, Barcelona, Spain
4. Dermatological Allergology, Allergie-Centrum-Charité, Department of Dermatology and Allergy, Charité – Universitätsmedizin, Berlin, Germany

**Disclosure:** Laires is an employee of Novartis Pharma AG, Basel, Switzerland. Bernstein reports grants and personal fees from Novartis, Astra Zeneca, Allakos, Genentech, Sanofi Regeneron, Celldex, and Amgen outside the submitted work. Giménez-Arnau reports roles as a medical advisor for Uriach Pharma, Sanofi and Genentech, Novartis, FAES, GSK, AMGEN, and Thermo Fisher; has research grants supported by Uriach Pharma, Novartis, and Instituto Carlos III- FEDER; and also participates in educational activities for Uriach Pharma, Novartis, Genentech, Menarini, LEO- PHARMA, GSK, MSD, Almirall, AVENE, and Sanofi. Maurer is or recently was a speaker and/or advisor for and/or has received research funding from Amgen, Allakos, Aralez, AstraZeneca, Celldex, FAES, Genentech, GInnovation, Kyowa Kirin, Leo Pharma, Menarini, Novartis, Moxie, MSD, Roche, Sanofi, Third Harmonic, UCB, and Uriach.

**Acknowledgements:** Medical writing assistance was provided by Jennifer Taylor, London, UK.

**Support:** The publication of this article was funded by Novartis. The views and opinions expressed are those of the authors and not necessarily those of Novartis.

**Citation:** EMJ Dermatol. 2021;9[1]:35-41.

## Meeting Summary

The latest international guidelines on urticaria were published in September as a joint initiative from the European Academy of Allergology and Clinical Immunology (EAACI), the Global Allergy and Asthma European Network (GA<sup>2</sup>LEN), the European Dermatology Forum (EDF; EuroGuiDerm), and the Asia Pacific Association of Allergy, Asthma and Clinical Immunology (APAAACI).<sup>1</sup> The guidelines state that the goal of treatment is to treat the disease until it is gone and as efficiently and safely as possible aiming for a continuous weekly Urticaria Activity Score (UAS7) of 0, complete control, and a normalisation of quality of life. It is recommended that in addition to healing the disease and reducing disease activity, the therapeutic approach to chronic urticaria (CU) should involve using patient-reported outcome measures (PROMs), such as the Urticaria Activity Score (UAS), UAS7, the angioedema activity score (AAS), the chronic spontaneous urticaria quality of life questionnaire (CU-Q2oL), the angioedema quality of life questionnaire (AE-QoL), the urticaria control test (UCT), and the angioedema control test (AECT).

Complete urticaria control is required for the least impact on quality of life, sleep, activity, and work. This was demonstrated in three posters presented at the European Academy of Dermatology and Venereology (EADV) 2021 Congress in Vienna, Austria. An analysis of real-world data from the “A Worldwide Antihistamine-Refractory chronic urticaria patient Evaluation” (AWARE) study demonstrated that patients with chronic spontaneous urticaria (CSU) achieving UAS7=0 had significantly lower mean Dermatology Life Quality Index (DLQI) and CU-Q2oL scores compared with patients in other disease activity bands, including the well-controlled state (UAS7=1–6). A further analysis of the AWARE study data showed that patients achieving UAS7=0 had significantly lower mean CU-Q2oL sleep domain scores compared with patients in other UAS7 disease activity bands. Patients achieving complete control (UAS7=0) even had significantly lower CU-Q2oL sleep domain scores compared with well-controlled (UAS7=1–6) patients. Real life data from the AWARE study have shown that a large proportion of patients do not reach complete control and new treatment options are needed. An analysis of pooled data from a Phase IIb ligelizumab study found that complete control was also associated with less interference with activity and work.<sup>2</sup> Comparing patients with UAS7=0 (urticaria free) to those with UAS7=1–6 (well-controlled), there was a 178-times higher likelihood of having a Weekly Activity Interference Score (AIS7)=0 and a three-times higher likelihood of having an Overall Work Impairment Score=0, confirming the findings from AWARE.

Further analysis of the AWARE study suggested the advantages of early and sustained high-efficacy treatment on the quality of life of patients with CSU. Mean DLQI scores at baseline and Year 1 in the early omalizumab treatment group were 12.3 and 2.9, respectively, compared with 11.6 and 4.1 in the late group, and 8.4 and 4.5 in the no omalizumab group. Furthermore, early and sustained use of omalizumab was significantly associated with achieving a DLQI score of 0–1 at 1 year of follow-up in the AWARE study, after adjustment for other relevant factors.

To assess the holistic effect of treatment in patients with CSU, composite scores were created combining symptoms with quality of life. A composite score of Weekly Hives Severity Score (HSS7), Weekly Itch Severity Score (ISS7), and Weekly Angioedema Activity Score (AAS7) was used to examine complete control in the Phase IIb ligelizumab study. When compared to omalizumab, patients in the ligelizumab arms had a 15.9–19.4% higher chance of achieving CSU completely controlled status. When compared to placebo, patients on ligelizumab had a 36.2–39.7% higher chance of achieving CSU completely controlled status.

CSU disease activity can fluctuate and because UAS7 is a weekly score it may not adequately record information on flare-ups. A novel rolling UAS7 (rUAS7) was used to define flare-ups in an exploratory analysis of the Phase IIb ligelizumab study. During the treatment period, the proportion of patients who did not experience flare-ups was 50.0%, 58.8%, 47.0%, and 27.9% for ligelizumab 72 and 240 mg, omalizumab 300 mg, and placebo, respectively.

---

## Introduction

Disease control or activity should be assessed in trials and in clinical practice. The guidelines state that “treatment should follow the basic principles of treating as much as needed and as little as possible taking into consideration that the activity of the disease may vary. This implies stepping up or stepping down in the treatment algorithm according to the course of disease following the principle assess, adjust, act, and reassess.” In this context, UCT <12 defines uncontrolled disease and requires a step-up in treatment. Patients with UCT=12–15 have well-

controlled disease and the action is to continue therapy and try to optimise. Those with UCT=16 have completely controlled disease and a step-down (i.e., reducing dose or extending intervals) is indicated based on individual factors.

Three posters presented at EADV 2021 showed that in patients with CSU, complete control was correlated with better health-related quality of life (HRQoL),<sup>3</sup> better sleep quality,<sup>4</sup> and less interference with activity and work.<sup>5</sup> The advantages of early and high-efficacy treatment on quality of life were also outlined.<sup>6</sup> A more holistic assessment of treatment effect using

a composite score combining symptoms and quality of life showed that more patients achieve complete control with ligelizumab 240 or 72 mg compared to omalizumab 300 mg.<sup>7</sup> Finally, a novel exploratory analysis examined the stability of complete response to anti-IgE treatments, once achieved.<sup>8</sup>

## Benefits of Complete Control on Quality of Life, Sleep, Activity, and Work<sup>3,4,5</sup>

Pedro A. Laires, Jonathan A. Bernstein

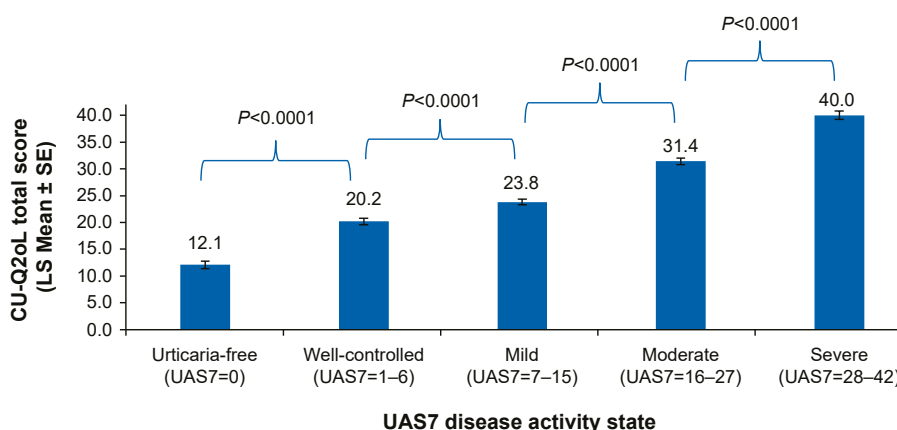
Three posters presented at EADV 2021 suggested that in patients with CSU, complete control was correlated with better HRQoL,<sup>3</sup> better sleep quality,<sup>4</sup> and less interference with activity and work.<sup>5</sup> All three studies showed that compared with complete control, those with even one disease activity band higher (i.e., well-controlled) experienced a significantly greater burden of their condition on PROMs.

An analysis of real-world data from the AWARE study demonstrated that patients achieving UAS7=0 had significantly ( $p<0.0001$ ) lower mean DLQI and CU-Q2oL scores compared with patients in other disease activity bands, indicating better HRQoL in those with complete symptom

control. **Figure 1** shows the CU-Q2oL scores by UAS7 categories. The Pearson correlation coefficient between the DLQI and UAS7 score was 0.63 ( $p<0.0001$ ) and between the CU-Q2oL and UAS7 score was 0.57 ( $p<0.0001$ ), indicating a significant positive correlation between symptom control and HRQoL.

**Figure 2** shows the correlation between the CU-Q2oL sleep domain and UAS7 bands. Patients achieving UAS7=0 had significantly ( $p<0.0001$ ) lower mean CU-Q2oL sleep domain scores compared with patients in other UAS7 disease activity bands, indicating improved quality of sleep in patients with complete symptom control. The Pearson correlation coefficient between the CU-Q2oL sleep domain and UAS7 score was 0.45 ( $p<0.0001$ ), indicating a significant positive correlation between symptoms and sleep. The analysis also demonstrated that the CU-Q2oL sleep domain score correlated with DLQI status. Patients achieving DLQI=0-1 had significantly ( $p<0.0001$ ) lower mean CU-Q2oL sleep domain scores compared with patients with higher DLQI scores.

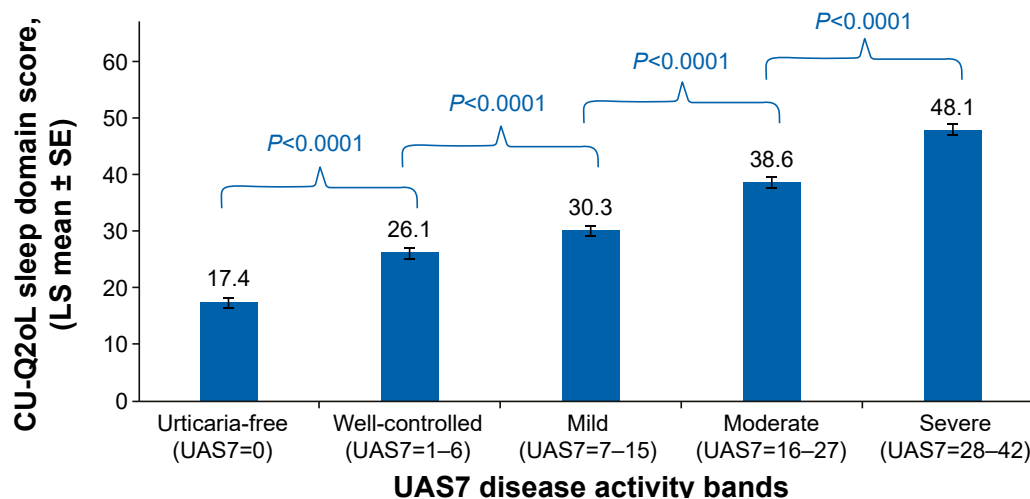
An analysis of pooled data from the Phase IIb ligelizumab study<sup>9</sup> found that in patients with UAS7=0, 91.1% reached DLQI=0-1 simultaneously. When patients with UAS7=0 were compared to those with UAS7=1-6, there was a five-times higher (odds ratio [OR]: 5.37; 95% confidence interval [CI]: 3.2-9.1;  $p<0.0001$ ) likelihood of



**Figure 1: CU-Q2oL total score by UAS7 disease states.**

For this analysis, data from patients across all timepoints up to Year 1 were considered.

CU-Q2oL: Chronic Urticaria Quality of Life questionnaire; LS: least squares; SE: standard error; UAS7: weekly Urticaria Activity Score.



**Figure 2: CU-Q2oL sleep domain scores by UAS7 bands from baseline up to Year 1.**

For this analysis, data from patients across all timepoints up to Year 1 were considered.

CU-Q2oL: Chronic Urticaria Quality of Life questionnaire; LS: least squares; SE: standard error; UAS7: weekly Urticaria Activity Score.

having DLQI=0-1. For SIS7, in patients with UAS7=0, 99.7% reached SIS7=0 simultaneously. Comparing patients with UAS7=0 to those with UAS7=1-6, there was a 137-times higher (OR: 136.77; 95% CI: 37.2-502.8;  $p<0.0001$ ) likelihood of having SIS7=0. Regarding AIS7, in patients with UAS7=0, 99.7% simultaneously reached AIS7=0. Comparing patients with UAS7=0 to those with UAS7=1-6, there was a 178-times higher (OR: 178.11; 95% CI: 29.2-1,085.8;  $p<0.0001$ ) likelihood of having AIS7=0. Finally, 85.3% of patients with UAS7=0 reached an Overall Work Impairment Score=0. Comparing patients with UAS7=0 to those with UAS7=1-6, there was a three-times (OR: 3.04; 95% CI: 1.8-5.1;  $p<0.0001$ ) higher likelihood of having Overall Work Impairment Score=0.

in CSU patients undergoing early and sustained omalizumab treatment.

Early and late treatment was defined as switch to omalizumab at 3 and 6-9 months from baseline, respectively, and continued treatment up to 1-year follow-up. Mean DLQI scores at baseline and Year 1 were assessed in patients with early, late, and no omalizumab treatment (no switch to omalizumab during the study).

Early and sustained use of omalizumab was significantly associated with achieving DLQI=0-1, with an OR of 2.4 (95% CI: 1.5-3.8;  $p<0.001$ ). Despite a positive trend, no significant association was seen with late treatment (OR: 1.5; 95% CI: 0.8-2.6;  $p=0.174$ ) or overall omalizumab treatment for achieving DLQI=0-1 (OR: 1.6; 95% CI: 0.8-3.2;  $p=0.160$ ).

## Benefits of Early Treatment on Quality of Life<sup>6</sup>

Pedro A. Laires

Previous studies have demonstrated the effectiveness and safety of omalizumab in CSU,<sup>10-12</sup> but real-world evidence describing the role of early treatment is limited. This analysis of the real-world AWARE study investigated HRQoL

In summary, the results indicate that early and sustained treatment with omalizumab in a real-world setting is associated with improved quality of life in patients with CSU. The authors said the findings highlight the importance of early access and use of high-efficacy treatments in the management of CSU, whenever clinically required, to attain the best possible outcomes for patients.

## A Composite Score Combining Symptoms with Quality of Life to Evaluate Complete Control of Urticaria with Ligelizumab<sup>7</sup>

Ana Giménez-Arnau

Assessing the holistic effect of treatment in patients with CSU requires evaluating different patient-reported outcomes (PROs) such as the HSS7, ISS7, AAS7, and DLQI. While these measures correlate, patients may not always exhibit the same magnitude of response for each PRO and there may be lags between responses. In addition, not all patients experience angioedema, which can severely impact quality of life as well. This study therefore examined complete urticaria control using composite scores of different PROs. Patients were considered to have CSU completely controlled if they recorded concurrent HSS7=0, ISS7=0, and AAS7=0, and to be CSU-free if they also recorded DLQI=0-1.

Table 1 shows the proportion of patients in each of the four treatment arms who achieved complete responses in the PROs and who were completely controlled or CSU-free according to the composite scores. The authors stated that the composite outcome evaluation provided a

more holistic approach to the treatment response and clearly differentiated outcomes across treatment arms.

The investigators estimated the probability of achieving CSU completely controlled and CSU-free status by treatment at Week 12. When compared to omalizumab, patients in the ligelizumab arms had a 15.9-19.4% higher chance of achieving CSU completely controlled status, and 15.7-18.2% higher chance of achieving CSU-free status according to the composite scores. When compared to placebo, patients on ligelizumab had a 36.2-39.7% higher chance of achieving CSU completely controlled status, and 32.0-34.5% higher chance of achieving a CSU-free status.

To summarise, in the core Phase IIb and extension studies, ligelizumab was more likely to achieve and sustain complete control concurrently on all PROs compared with omalizumab or placebo in patients with CSU. The authors concluded that using a composite score of validated PROs for CSU could be useful in clinical studies for differentiating response to treatments.

**Table 1: The percentage of patients who achieved complete response in the HSS7, ISS7, AAS7, and DLQI 0-1 at Week 12.**

	Ligelizumab 72 mg (N=84)	Ligelizumab 240 mg (N=85)	Omalizumab 300 mg (N=85)	Placebo (N=43)
<b>ISS7=0</b>	47.6	42.4	29.4	4.7
<b>HSS7=0</b>	51.2	42.4	25.9	0
<b>AAS7=0</b>	87.5	84.6	75.0	61.0
<b>DLQI 0-1</b>	61.0	54.9	44.7	33.3
<b>CSU completely controlled</b>	44.1	40.0	23.5	0
<b>CSU-free</b>	38.1	35.3	18.8	0

Data were analysed using non-responder imputation. CSU completely controlled: free from signs and symptoms of urticaria with concurrent HSS7=0, ISS7=0, and AAS7=0; CSU-free: CSU completely controlled with concurrent DLQI=0-1.

AAS7: Weekly Angioedema Activity Score; CSU: Chronic Spontaneous Urticaria; DLQI: Dermatology Life Quality Index; HSS7: Weekly Hives Severity Score; ISS7: Weekly Itch Severity Score.

# Ligelizumab Shows Good Stability of Response in Patients with Chronic Spontaneous Urticaria: A Novel Exploratory Analysis of Urticaria Flare-ups<sup>8</sup>

Marcus Maurer

CSU can present with intermittent exacerbations of disease activity (flare-ups) even in patients undergoing treatment. The UAS7 is used to assess the effect of treatment but lacks the granularity of daily assessment of urticaria activity, while daily UAS does not provide a stable overview of the trends in disease activity.

The current exploratory analysis used a novel rUAS7 to provide a stable assessment of disease activity while maintaining granularity. The study defined and measured flare-ups using a trend of continuous increase in  $rUAS7 \geq 10$  and explored the effect of ligelizumab treatment on flare-ups in patients with CSU.

The study included patients in the ligelizumab 72 mg and 240 mg, omalizumab 300 mg, and placebo treatment arms of the Phase IIb ligelizumab study. The rUAS7 was calculated as the sum of UAS for a set of 7 consecutive days starting on a given day. It was calculated for every possible set of 7 consecutive days during the study. A flare-up was defined as a temporary continuous increase of  $rUAS7 \geq 10$  (based on minimum important difference for  $UAS7^{13,14}$ ) from the lowest rUAS7 achieved before the flare. The day when such a difference was  $< 10$  points from the previous minimum was considered to be the end of the flare-up. The number of days, including the first day, spent

with a flare-up was calculated as the duration of the flare-up.

The number of flare-ups and time to first flare-up, as well as the proportion of flare-up free days, were evaluated for patients in each treatment arm during the 20-week treatment period and the first 12 weeks of the treatment-free follow-up period.

Regarding the number of flare-ups during the treatment period, the proportion of patients who did not experience flare-ups was 50.0%, 58.8%, 47.0%, and 27.9% for ligelizumab 72 and 240 mg, omalizumab, and placebo, respectively. The time to achieve a median  $rUAS7=0$  (urticaria free) with ligelizumab 72 mg, 240 mg, and omalizumab was 48, 71, and 101 days (the placebo arm did not reach the median value for  $rUAS7=0$ ). Regarding the estimated time to first flare-up in 25% of patients, this was 36 and 47 days for ligelizumab 72 and 240 mg, respectively, 37 days for omalizumab, and 31 days for placebo.

In summary, treatment with ligelizumab showed good control of multiple flare-ups and disease stability. The authors concluded that assessment of flare-ups could improve CSU management in clinical practice.

## Conclusion

Clinical trials and real-world data demonstrate the benefits and importance of achieving complete control in patients with CSU on quality of life, sleep quality, and ability to work, and illustrate the advantages of early treatment. Novel assessments may be used in future to better reflect the burden of disease, and new treatment options promise to improve patient wellbeing.

## References

1. Zuberbier T et al. The international EAACI/GA<sup>2</sup>LEN/EuroGuiDerm/APAAACI guideline for the definition, classification, diagnosis and management of urticaria. *Allergy*. 2021; DOI:10.1111/all.15090.
2. Novartis Pharmaceuticals. Dose-finding study of QGE031 as add-on therapy to evaluate efficiency and safety in patients with CSU. NCT02477332. <https://clinicaltrials.gov/ct2/show/NCT02477332>
3. Laires PA et al. Complete control of wheals and itch in CSU significantly correlates with better patients' quality of life: analysis from a worldwide real-world database (AWARE Study). P1569. EADV Congress, 29 September-2 October, 2021.
4. Laires PA et al. Complete control of wheals and itch in CSU significantly correlates with better sleep quality: analysis from a worldwide real-world database (AWARE Study). P1570. EADV Congress, 29 September-2 October, 2021.
5. Bernstein JA. Complete symptom control in patients with chronic spontaneous urticaria is associated with an improvement in health-related quality of life: data from the

- Phase 2b ligelizumab study. P1577. EADV Congress, 29 September-2 October, 2021.
6. Laires PA et al. Early and sustained treatment with omalizumab significantly improves quality of life in patients with chronic spontaneous urticaria: analysis from a worldwide real-world database (AWARE Study). P1571. EADV Congress, 29 September-2 October, 2021.
  7. Giménez-Arnau A. A composite score combining symptoms with QoL to evaluate complete control of urticaria with ligelizumab. P1574. EADV Congress, 29 September-2 October, 2021.
  8. Maurer M. Ligelizumab shows good stability of response in patients with chronic spontaneous urticaria: a novel exploratory analysis of urticaria flare-ups. P1576. EADV Congress, 29 September-2 October, 2021.
  9. Maurer M et al. Ligelizumab for chronic spontaneous urticaria. *N Engl J Med.* 2019;381(14):1321-32.
  10. Staubach P et al. Effect of omalizumab on angioedema in H1-antihistamine-resistant chronic spontaneous urticaria patients: results from X-ACT, a randomized controlled trial. *Allergy.* 2016;71(8):1135-44.
  11. Kaplan A et al. Omalizumab in patients with symptomatic chronic idiopathic/spontaneous urticaria despite standard combination therapy. *J Allergy Clin Immunol.* 2013;132(1):101-9.
  12. Maurer M et al. Omalizumab for the treatment of chronic idiopathic or spontaneous urticaria. *N Engl J Med.* 2013;368(10):924-35.
  13. Mathias SD et al. Evaluating the minimally important difference of the urticaria activity score and other measures of disease activity in patients with chronic idiopathic urticaria. *Ann Allergy Asthma Immunol.* 2012;108(1):20-4.
  14. Hawro T et al. The urticaria activity score-validity, reliability, and responsiveness. *J Allergy Clin Immunol Pract.* 2018;6(4):1185-90.

FOR REPRINT QUERIES PLEASE CONTACT: [INFO@EMJREVIEWS.COM](mailto:INFO@EMJREVIEWS.COM)

# Tailored Injection Techniques in the Mid- and Lower Face Using a Multilayering Approach

These symposia took place on 16<sup>th</sup> and 17<sup>th</sup> September 2021, as part of the Aesthetic and Anti-aging Medicine World Congress (AMWC) held in Monaco

<b>Speakers:</b>	Patrick Trevidic, <sup>1</sup> Lee Walker, <sup>2</sup> Benji Dhillon, <sup>3</sup> Ayad Harb, <sup>4</sup> Kieren Bong, <sup>5</sup> Raul Cetto, <sup>6</sup> Rémi Foissac, <sup>7</sup> Sabrina Shah-Desai <sup>8</sup>
	<ol style="list-style-type: none"><li>1. Expert 2 Expert, Paris, France</li><li>2. BCity Clinics, Liverpool, UK</li><li>3. Define Clinic, Beaconsfield, UK</li><li>4. Dr Ayad Harb Clinic, Bicester, UK</li><li>5. Essence Medical, Glasgow, UK</li><li>6. Clinic 1.6, London, UK</li><li>7. Polyclinique Saint George, Nice, France</li><li>8. Perfect Eyes Ltd., London, UK</li></ol>
<b>Disclosure:</b>	All speakers have served as consultants for Teoxane.
<b>Acknowledgements:</b>	Medical Writing assistance was provided by Pauline Maffert, Clinical & Medical Affairs Department, Teoxane, Geneva, Switzerland.
<b>Support:</b>	The symposium and publication of this article were funded by Teoxane.
<b>Citation:</b>	EMJ Dermatol. 2021;9[1]:42-50.

## Meeting Summary

Recent years have witnessed significant advances in the understanding of facial anatomy. Extensive studies have uncovered the arrangement of soft-tissue layers underlying the skin and their mobility during expression.<sup>1,2</sup> Meanwhile, increasing awareness of the facial vascular network has laid the foundation for lower risk cosmetic procedures.<sup>3-5</sup>

In this context, facial aesthetic surgery tends to lose ground to less invasive procedures that, in the right hands, may provide similar benefits through less traumatic, relatively painless treatments and minimal social downtime. Hyaluronic acid (HA) fillers have thus gained popularity and evolved from their 'wrinkle filling' role to expand to facial contouring, volume augmentation, and profiloplasty.<sup>6-8</sup> Despite their well-established efficacy and safety profile, achieving natural-looking results in these indications requires specific products and appropriate techniques adapted to patient age, gender, ethnicity, and facial dynamism.<sup>9-12</sup>

The 'anatomy, techniques, products' approach, which stems from these core principles, was presented during two symposia at the Aesthetic and Anti-aging Medicine World Congress (AMWC) 2021, focusing on HA filler treatments in the mid- and lower face.



## Symposium 1: Midface

Sabrina Shah-Desai, Patrick Trevidic, Lee Walker, Benji Dhillon, Ayad Harb, and Kieren Bong

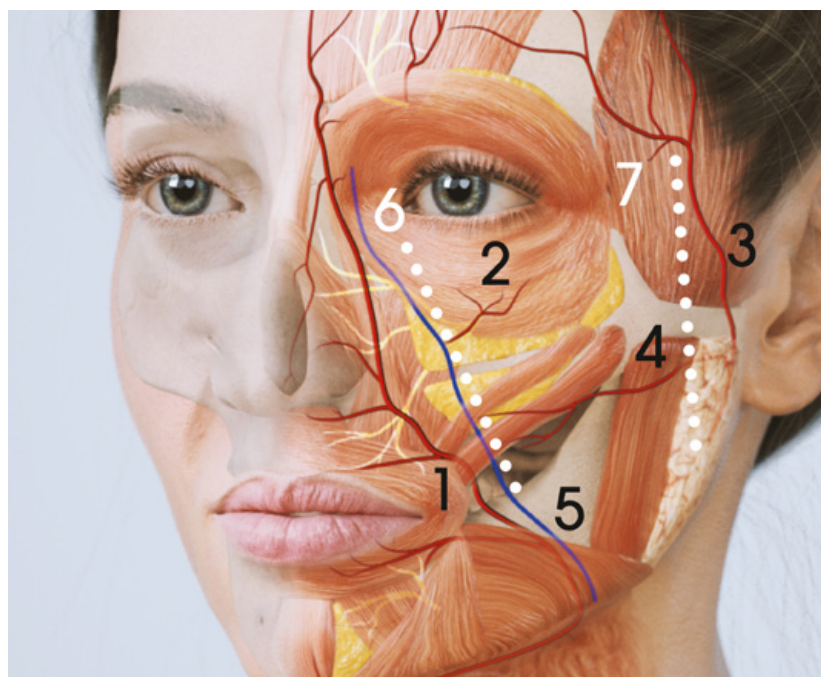
### Anatomy

During the midface symposium, moderated by Sabrina Shah-Desai, Patrick Trevidic emphasised the necessity to understand the 3D vascular network of the face, considering the poor reliability of pre-injection aspiration.<sup>13</sup> He proposed to delimit the injection area lateral to the mid-cheek groove and above the zygomatic line to respectively rule out risks of encountering the facial artery (FA), facial vein, and the transverse FA. As all branches of the infraorbital artery run down and medially in the face after emerging from the infraorbital foramen, staying lateral to the mid-cheek groove should also minimise risk of injury. Furthermore, small capillaries rising from the zygomatico FA and running up superficially are theoretically too small to constitute a potential HA embolus' door (Figure 1).<sup>14-18</sup>

After having detailed the five-layered arrangement of the midface, including the skin, superficial fat, superficial musculoaponeurotic system, deep fat, and bone, a fourth dimension was introduced: facial dynamism.<sup>19</sup> Showing the animation of a “smiling cadaver,” Trevidic illustrated the behaviour of deep versus superficial fat compartments upon muscle contraction. While the former stuck to the bone and remained static during movement, the latter moved along with the underlying muscle and soft tissue envelope.<sup>20</sup>

Of note, as augmenting the midface may also impact the perception of other areas of the face, patient assessment should include an evaluation of adjacent anatomical zones, including the temple, tear trough, and nasolabial fold.<sup>21</sup>

Lee Walker described how ageing causes an overall descent of the soft tissue envelope and how it affects each layer of the midface. In the dermis, the collagenous extracellular matrix is altered and elastin fibres disorganise as a result of intrinsic and extrinsic ageing.<sup>22</sup> Meanwhile, superficial fat compartments undergo selective hypertrophy and lengthening; the underlying superficial musculoaponeurotic system becomes



**Figure 1: Vascular dangers of the midface and proposed safety lines delineating a relatively avascular area.**

1) Facial artery; 2) infraorbital foramen; 3) superficial temporal artery; 4) transverse facial artery; 5) facial vein; 6) mid-cheek safety line; and 7) lateral safety line.

lax; facial muscles lengthen, thereby reducing the amplitude of movement; and all deep fat pads lose volume.<sup>22</sup> Finally, bony remodelling in the face causes the glabellar, pyriform, and maxillary angles to decrease, allowing overlying soft tissues to rotate in an anterior direction.<sup>23</sup> Seeing the face as a landscape, these combined changes culminate in the appearance of hypertrophic hills side-by-side with atrophic valleys.<sup>24</sup> The most dramatic volume changes occur between 30 years and 60 years, with patients losing approximately 11% of their superficial fat and 18% of their deep fat.<sup>25</sup>

To avoid the pitfall of the overfilled midface and the appearance of ‘apple cheeks’ upon smiling, Walker explained the role of the transverse facial septum, which displaces upon smiling, thereby causing an anterior projection of deep midfacial fat compartments.<sup>26</sup> Being aware of this mechanism, injectors are advised to ask their patient to smile repeatedly during the procedure.

## Techniques and Products Tailored to Each Patient

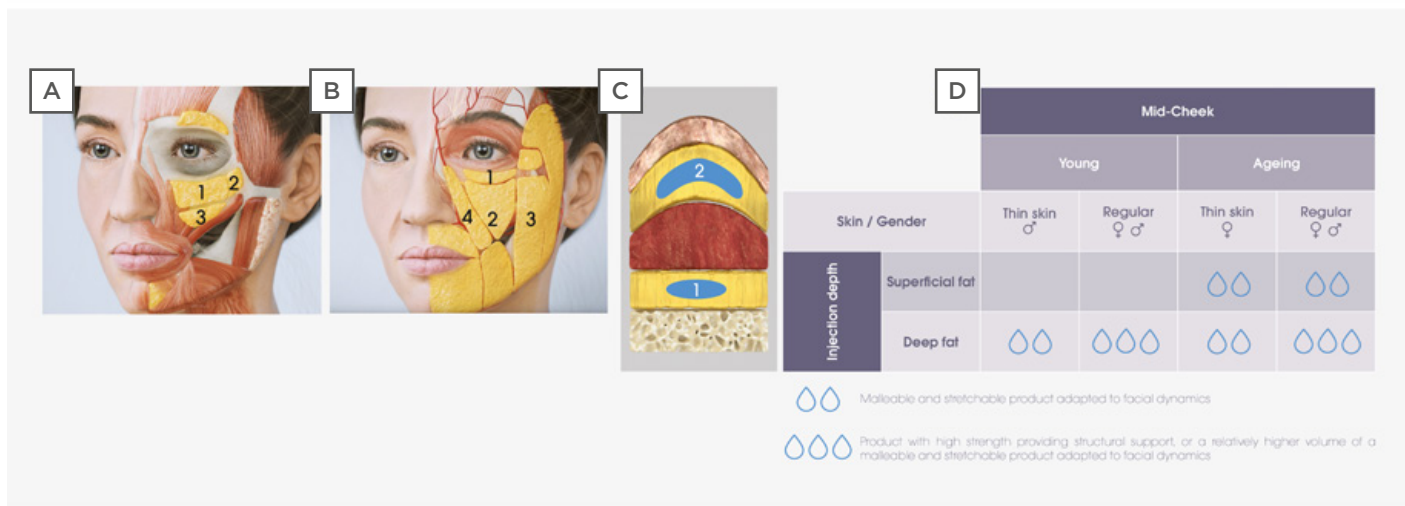
To fully address the ageing process affecting all layers of the midface, a multilayering approach

was recommended, aiming to compensate for deep and/or superficial volume loss depending on patient assessment, using appropriate techniques and products. Limiting the injections to the deep layer would require higher volumes to get the same lifting effect,<sup>27</sup> while injecting high volumes or inadequate products superficially could lead to bumps and irregularities under the skin.<sup>28</sup>

Products injected into each layer should be adequately chosen to mimic the original biomechanical properties and role of the fat, i.e., projection and support in the deep layer, and dynamic volumising in the superficial layer (Figure 2).

Furthermore, to ensure natural-looking outcomes, techniques and products should be fine-tuned to adapt to each patient anatomy. To illustrate this point, Benji Dhillon reviewed the ideals of facial beauty across ethnicity and gender, and anatomical differences influencing treatment plan.

While the male face is typically squarer than the female’s and less full in the anteromedial cheek, female attractiveness lies in the cheeks. It is commonly associated with a heart to oval



**Figure 2: The multilayer anatomy of the midface spanning from bone to skin.**

**A)** The static deep fat compartments: 1) mSOOF; 2) ISOOF; and 3) medial and lateral DMCF. **B)** The mobile superficial fat compartments: 1) IOF compartment; 2) MCF compartment; 3) MiCF compartment; and 4) NLF compartment.

**C)** A multilayer treatment algorithm for filling 1) deep and 2) superficial fat layers of the mid-cheek with hyaluronic acid fillers adapted to specific patient needs, depending on age, gender, and skin type **(D)**.

DMCF: deep medial cheek fat; IOF: infraorbital fat; ISOOF: lateral sub-orbicularis oculi fat; MCF: medial cheek fat; MiCF: middle cheek fat; mSOOF: medial sub-orbicularis oculi fat; NLF: nasolabial fat.

shaped face, with a bizygomatic distance greater than the bigonial distance (versus the equivalent in men), prominent upper facial features, and lateral cheeks smoothly running into full medial cheeks.<sup>29</sup>

Ethnicity brings further complexity to these general notions. White people present narrower faces, with greater vertical height and projection in the upper face and midface, whilst Southeast Asian people have a wider face with shorter vertical height and are flatter in the medial maxilla.<sup>30,31</sup> African-Caribbean people have a greater adiposity and skin thickness, a wider alar base, and ideally present an oval-shaped face.<sup>32</sup> Finally, Middle Eastern women show well defined and full lateral cheeks, and an oval or square shaped face.<sup>33</sup> However, some aesthetic ideals tend to evolve with globalisation, setting new aesthetic goals such as “ethnic optimisation,” “westernisation,” and “ethnic feature blending,” going against traditional beauty concepts.<sup>34</sup>

## Live Demonstrations

Four expert injectors applied a tailored multilayering technique to the midface of patients from different ethnicities and ages, concretely showing how “each patient is unique.”

### Focus on ethnicity: Middle Eastern and Southeast Asian patients

#### *Middle Eastern female patient*

Ayad Harb initiated live injections with a Middle Eastern female patient aged 32 years, concerned by the flatness of her midface giving her a tired look.

Objectively, the patient was perceived as young, without visible signs of deterioration of her volume or skin. She did present, however, with noticeable shadows and deficiencies in her midface and tear trough, and a lack of anterior projection. On the other hand, she had sufficient projection and contour in her lateral cheek. Therefore, the treatment aimed to enhance the anterior projection of her midface, fill her medial cheek, and further camouflage her tear trough, if still prominent after her midface treatment.

A 25 G cannula technique was used for injecting both the deep and superficial fat of the midface from a single-entry point on the zygoma.

Starting with the deep fat compartments, a strong projecting filler (TEOSYAL® Ultra Deep [HA<sub>UD</sub>]) was injected very slowly in small boluses in the medial sub-orbicularis oculi fat (mSOOF) and deep medial cheek fat (DMCF; 0.3 mL per compartment). The lateral SOOF (ISOOF) was left out in this patient already as she was showing good lateral projection.

In the superficial fat, another volumising but more dynamic filler (TEOSYAL RHA® 4 [RHA 4]) was selected to enhance the patient’s natural contour. Asking her to smile to see her cheeks animated helped to identify the areas to be filled. The infraorbital fat (prone to oedema and water retention) and the nasolabial fat (which hypertrophies with aging)<sup>35</sup> were excluded from the treatment zone. The filler was placed evenly across her medial and middle superficial fat, injecting 0.3 mL per side.

#### *Southeast Asian female patient*

Dhillon performed the second live injection on a 37-year-old female patient presenting a complex blend of ethnicities, being half European, a quarter Taiwanese, and a quarter Korean.

She presented a heart to oval shaped face with an adequate ratio between bizygomatic and bigonial distances. She did show some degree of volume loss in the midface and pyriform fossa, though very limited considering her age and ethnicity. Upon smiling, her cheek filled up beautifully showing she was full in her medial superficial fat. Her youth and good skin quality were suitable indications for using a strong product in her deep fat compartments. In her case, treatment goals were thus to enhance the projection of her anterior medial cheek, and to improve the fullness of her subcutaneous submalar area.

Small boluses (0.1-0.2 mL) of HA<sub>UD</sub> were placed deep onto the periosteum in the mSOOF and DMCF, accessing the area with a 25 G cannula introduced from the zygoma. In this young patient with limited volume loss, no superficial injections were needed in the medial cheek.

However, superficial injections were performed with a cannula using a slightly lower entry point, targeting the area just below the zygomatic arch to correct its slight hollowness with little threads of RHA 4 (0.7 mL per side).

Finally, moving to the boundaries of the midface area, a small bolus (0.1 mL) of HA<sub>UD</sub> was injected deep onto the periosteum in the pyriform fossa, giving a little more reflection to this area.

## Focus on age

### *Younger female patient*

Kieren Bong treated a 32-year-old female with another specific background, as she was a professional athlete with very low body fat. She showed a mild lengthening of the lid-cheek junction, a slight infraorbital hollowness, and lacked some anterior projection and fullness.

Deep injections of HA<sub>UD</sub> were performed using a cannula technique from an entry point on the extension of the tear trough, slightly higher than the mid-cheek groove, located using the length of the cannula (50 mm). A first bolus was placed in the upper mSOOF, aiming to shorten the vertical height of the lower lid. To provide mild frontal and slight lateral projection to her midface, two other boluses were injected in the mSOOF and ISOOF, paying attention to avoid the malar mound. An overall volume of 0.6 mL of HA<sub>UD</sub> per side was needed.

A small amount of TEOSYAL® PureSense REDENSITY 2 was then injected in her tear trough to soften her infraorbital hollow with this specifically designed filler.<sup>36,37</sup> The product was placed deep onto the bone, slightly above the orbicularis retaining ligament (ORL), and then massaged into place.

Lastly, superficial injections of RHA 4 were done from a second entry point, approximately 1 cm lateral to the lateral canthus, injecting 0.5 mL of product in linear threads.

### *Older female patient*

Midface live demonstrations ended with a 49-year-old patient with more visible signs of ageing, volume loss, and skin laxity. She was thin, with low body fat and a more skeletonised appearance.

The ORL and zygomatico-cutaneous ligament (ZCL) were easily marked on her face. The ORL (superiorly) and ZCL (inferiorly) house the superficial infraorbital fat, which was prominent in this thin patient. This area of poor lymphatic drainage should always be avoided during

a filling procedure to avoid worsening the bulging appearance of the infraorbital fat. The ISOOF lying deep between the ORL and the ZCL, lateral to the orbital line, was excluded from the treatment plan as lateralising this patient's midface could have further deepened her temporal fossa and preauricular area.

Aiming to create a positive vector on the patient's face, deep injections were performed in the mSOOF with RHA 4 (0.2 mL) and in the DMCF with HA<sub>UD</sub> (0.1 mL) using a needle bolus technique. In this thin-skinned patient, RHA 4 was appropriate to provide anterior projection in the mSOOF, which efficiently translates filler volume into surface projection. In the DMCF, where the surface-volume coefficient is lower, the stiffer, more cohesive HA<sub>UD</sub> gel was preferred to get the desired projection with minimal volume.<sup>38</sup>

The second treatment step aimed to fill the medial and middle superficial fat with RHA 4. A 25 G cannula was advanced in the submalar area from a medial entry point. The cannula was considered safer as the superior emerging branch of the transverse FA lies in the subcutaneous plane, approximately a finger under the zygoma.<sup>5</sup>

---

## Symposium 2: Lower Face

Patrick Trevidic, Raul Cetto,  
Benji Dhillon, and Rémi Foissac

### Anatomy

The 'anatomy, techniques, products' approach applied to the lower face was illustrated during four live injections in indications covering the anterior and posterior parts of the lower third of the face.

Key vascular dangers of the lower face were summarised by Trevidic. He drew the path of the FA and facial vein, crossing the inferior border of the mandible anterior to the insertion of the masseter and deep to the platysma, with the main trunk of the FA going up to the nasolabial fold while its submandibular branch gives the mental ascending branch emerging in the chin, approximately 6 mm from the midline, within the submuscular plane (Figure 1).<sup>39-41</sup>

He also showed the three fixed points on the lower face where soft tissues are tightly attached to the bone: the mandibular ligament, parotidomasseteric ligament framing the jowl, and mandibular angle.<sup>42-44</sup> Their presence may become evident during ageing with tissue ptosis, resulting in a disrupted jawline.

The arrangement of soft tissue layers is also quite different between the anterior and posterior lower face. The chin is the most dynamic part, where three paired muscles can be found on each side of the mouth: the depressor anguli oris, depressor labii inferioris, and mentalis. In this highly dynamic area, there is a traditional five-layered arrangement just like in the midface. By contrast, lateral to the mandibular ligament lies the static part of the lower face, i.e., the jawline and the gonial angle, where the masseter is directly attached to the bone without intermediate fat.<sup>2,45</sup>

## Techniques and Products Tailored to Each Patient

### Age and gender specificities

Desirable aesthetic features in the lower face include a projected chin and a defined line from the gonial angle to the chin, contributing to a youthful look.<sup>7</sup> However, there are gender specificities to be considered before establishing a treatment plan. Males typically have a squarer face than females, with a sharper jawline and a more pronounced jaw angle, whereas females present a more oval facial shape. The chin is also larger in males, whereas in females it is rounder and more subtle.<sup>7</sup>

#### *Younger female patient*

In the first live demonstration, a 43-year-old female patient was treated with the aim of improving her chin projection and redefining her mandibular line.

Chin projection was obtained by placing 0.6 mL of HA<sub>UD</sub> in the midline of her chin, going deep, straight onto the periosteum using a needle, the bevel facing the bone.

Afterwards, RHA 4 was injected in the paramedian area using a fan-technique, introducing a cannula in the superficial plane from an entry point located at the bottom of the marionette line.

Four to five linear threads were placed along the mandible to recreate the anterior jawline, and superiorly to improve the marionette line and corner of the mouth. The posterior part of the jawline was addressed using a superficial cannula technique from an entry point posterior to the jowl, advancing in direction of the mandibular angle. One syringe (1.2 mL) of RHA 4 was needed to improve one side of the face. All superficial injections were followed by post-injection moulding to smooth the product into place.

#### *Younger male patient*

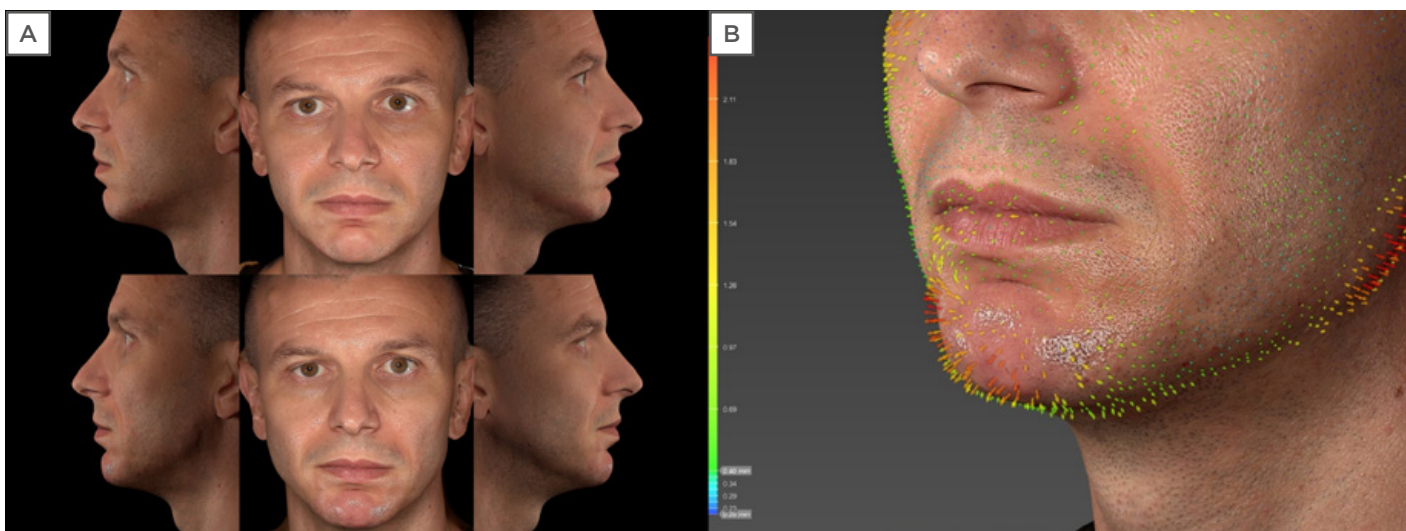
Gender differences required an adaptation of product and volumes in Raul Cetto's 38-year-old male patient.

Anatomical specificities were first regarded from an anterior perspective. In a male face, the width of the chin ideally corresponds to the width of the mouth instead of the intercanthal distance in females, and the bigonial distance should be close to the bizygomatic width. From a sagittal perspective, the chin tends to project further in males than in females. A squarer face is considered attractive, and angles are typically sharper. The mandibular line should be straight and uninterrupted, and often needs to be elongated to accentuate masculine traits in a male's face. Asking the patient to slide his teeth forward helps to visualise how far it can be improved.<sup>7,45</sup>

The first treatment step aimed to improve chin projection. To respect the width of the male chin, HA<sub>UD</sub> was injected in two supraperiosteal boluses (0.2-0.3 mL each) on both sides of the midline, instead of one central bolus. The superficial layer of the chin was then filled with RHA 4 using a cannula entered at the position of the mandibular ligament, delivering half a syringe on each side of the chin.

The main goal of the jawline treatment was to increase the bigonial width by placing a deep bolus of HA<sub>UD</sub> (0.3 mL) against the bone at the mandibular angle. Finally, using a cannula advanced from the mandibular angle, superficial injections of RHA 4 were completed to elongate the posterior jawline.

Before and after photographs can be seen in [Figure 3](#).



**Figure 3: Photographs of Cetto's 38-year-old male patient taken with the VECTRA® H2 3D imaging system (Canfield Scientific, Parsippany, New Jersey, USA).**

**A)** Before (upper) and after (lower) photographs of the patient. **B)** Visualisation of volume changes after treatment. The orange and red arrows indicate areas of volume augmentation.

### **Older female patient**

Dhillon's 49 year-old patient had strong masseters, giving her a square face and a large bigonial width. This was considered in the treatment plan to avoid masculinising her. Her gonial angle seemed to match with female standards (120–130°), hence did not require much reconstruction.<sup>46</sup> However, she presented mild jowling and lacked definition in her posterior jawline.

The jowl was demarcated as a 'no go' area, to concentrate treatment efforts on areas posterior and anterior to it. Entering from the jowl, a cannula was advanced in the subcutaneous plane in direction of the gonial angle to perform a fanning technique, depositing linear threads of RHA 4 while retracting the cannula above and below the mandibular border, to blend the mandibular line into the jowl. The same approach was used in the anterior part of the jawline, entering in the opposite direction. A total of 1.7 mL of RHA 4 per side provided the desired mandibular line and angle definition.

The chin was treated from a single-entry point in the midline. In the paramedian area, 0.6–0.7 mL of TEOSYAL RHA® 2 was fanned superficially in

each side, opting for this spreadable and highly stretchable gel to limit risks of irregularities in this thin-skinned patient. To further enhance chin projection, a 0.2 mL bolus of RHA 4 was deposited supraperiosteally in the midline.

The whole treatment required an overall 4 mL of filler, resulting in a straighter jawline, greater definition, and light reflection.

### **Chin retrogenia**

The last treatment session aimed to illustrate the treatment of congenital chin retrogenia in a 28-year-old female patient. Rémi Foissac used the Gonzales-Ulloa line to show the effect of chin retrusion on his patient's profile, particularly on her nose, which seemed abnormally large.

To project her chin, a whole syringe HA<sub>UD</sub> was injected in deep boluses onto the periosteum of the midline and paramedian zones, using a cannula introduced from the midline. The subcutaneous plane was filled using a fanning technique, with a cannula entered from the lateral chin, delivering half a syringe of RHA 4 on each side of the chin.

## Conclusion

The perception of a human face and, therefore, of a personality, is strongly impacted by the appearance of the midface and lower face. Age, gender, and ethnicity influence both the anatomy and the aesthetic ideals associated to

these areas. HA fillers may be used to provide a more harmonious or youthful look but should be selected and injected with thorough consideration to each patient's anatomy and background, keeping in mind the fourth dimension of the face, i.e., dynamic expression.

## References

1. Wilson AJ et al. Current applications of facial volumization with fillers. *Plast Reconstr Surg.* 2016;137(5):872e-89e.
2. Cotofana S, Lachman N. Anatomy of the facial fat compartments and their relevance in aesthetic surgery. *J Dtsch Dermatol Ges.* 2019;17(4):399-413.
3. Scheuer JFI et al. Anatomy of the facial danger zones: maximizing safety during soft-tissue filler injections. *Plast Reconstr Surg.* 2017;139(1):50e-8e.
4. Lee HJ et al. The facial artery: a comprehensive anatomical review. *Clin Anat.* 2018;31(1):99-108.
5. von Arx T et al. The face - a vascular perspective. A literature review. *Swiss Dent J.* 2018;128(5):382-92.
6. American Society of Plastic Surgeons (ASPS). National plastic surgery statistics. 2020. Available at: <https://www.plasticsurgery.org/documents/News/Statistics/2020/plastic-surgery-statistics-report-2020.pdf>. Last accessed: 19 October 2021.
7. Braz A, de Paula Eduardo CC. Reshaping the lower face using injectable fillers. *Indian J Plast Surg.* 2020;53(2):207-18.
8. Sykes JM, Fitzgerald R. Choosing the best procedure to augment the chin: is anything better than an implant? *Facial Plast Surg.* 2016;32(5):507-12.
9. Li D et al. A randomized, controlled, multicenter study of Juvéderm Voluma for enhancement of malar volume in Chinese subjects. *Plast Reconstr Surg.* 2017;139(6):1250e-9e.
10. Hong G et al., "Filler procedures based on the facial area," Hong G et al. (eds.), *The Art and Science of Filler Injection: Based on Clinical Anatomy and the Pinch Technique* (2020), Singapore: Springer Singapore, pp.103-75.
11. Brissett AE, Naylor MC. The aging African-American face. *Facial Plast Surg.* 2010;26(2):154-63.
12. Vashi NA et al. Aging differences in ethnic skin. *J Clin Aesthet Dermatol.* 2016;9(1):31-8.
13. Van Loghem JA et al. Sensitivity of aspiration as a safety test before injection of soft tissue fillers. *J Cosmet Dermatol.* 2018;17(1):39-46.
14. Kim HS et al. Topographic anatomy of the infraorbital artery and its clinical implications for nasolabial fold augmentation. *Plast Reconstr Surg.* 2018;142(3):273e-80e.
15. Bozиков K et al. Arterial anatomy of the lateral orbital and cheek region and arterial supply to the "perizygomatic perforator arteries" flap. *Surg Radiol Anat.* 2008;30(1):17-22.
16. Hong SJ et al. Variant facial artery anatomy revisited: conventional angiography performed in 284 cases. *Medicine (Baltimore).* 2020;99(28):e21048.
17. Yang HJ et al. Topographical anatomy of the transverse facial artery. *Clinical Anatomy.* 2010;23(2):168-78.
18. Koziej M et al. The transverse facial artery anatomy: implications for plastic surgery procedures. *PLoS One.* 2019;14(2):e0211974.
19. Rohrich RJ, Pessa JE. The fat compartments of the face: anatomy and clinical implications for cosmetic surgery. *Plast Reconstr Surg.* 2007;119(7):2219-27.
20. Schelke L et al. The mobility of the superficial and deep midfacial fat compartments: an ultrasound-based investigation. *J Cosmet Dermatol.* 2021;DOI:10.1111/jocd.14374.
21. DeLorenzi C et al. *Anatomy & Filler Complications* (2017), E2E.
22. Kapoor KM et al. Treating aging changes of facial anatomical layers with hyaluronic acid fillers. *Clin Cosmet Investig Dermatol.* 2021;14:1105-18.
23. Shaw Jr RB, Kahn DM. Aging of the midface bony elements: a three-dimensional computed tomographic study. *Plast Reconstr Surg.* 2007;119(2):675-81.
24. Donofrio LM. Fat distribution: a morphologic study of the aging face. *Dermatol Surg.* 2000;26(12):1107-12.
25. Boehm LM et al. Facial aging: a quantitative analysis of midface volume changes over 11 years. *Plast Reconstr Surg.* 2021;147(2):319-27.
26. Cotofana S et al. Anatomy behind the facial overfilled syndrome: the transverse facial septum. *Dermatol Surg.* 2020;46(8):e16-22.
27. Philipp-Dormston WG et al. Global approaches to the prevention and management of delayed-onset adverse reactions with hyaluronic acid-based fillers. *Plast Reconstr Surg Glob Open.* 2020;8(4):e2730.
28. Shalmon D et al. Management patterns of delayed inflammatory reactions to hyaluronic acid dermal fillers: an online survey in Israel. *Clin Cosmet Investig Dermatol.* 2020;13:345-9.
29. de Maio M. Ethnic and gender considerations in the use of facial injectables: male patients. *Plast Reconstr Surg.* 2015;136(Suppl 5):40S-3S.
30. Gao Y et al. Comparison of aesthetic facial criteria between Caucasian and East Asian female populations: an esthetic surgeon's perspective. *Asian J Surg.* 2018;41(1):4-11.
31. Liew S et al. Consensus on changing trends, attitudes, and concepts of Asian beauty. *Aesthetic Plast Surg.* 2016;40(2):193-201.
32. Coetzee V et al. African perceptions of female attractiveness. *PLoS One.* 2012;7(10):e48116.
33. Kashmar M et al. Consensus opinions on facial beauty and implications for aesthetic treatment in middle eastern women. *Plast Reconstr Surg Glob Open.* 2019;7(4):e2220.
34. Amin A. Multi-ethnicity and the idea of Europe. *Theory, Culture & Society.* 2004;21(2):1-24.
35. Cevik Cenkeri H et al. Aging changes of the superficial fat compartments of the midface over time: a magnetic resonance imaging study. *Dermatol Surg.* 2020;46(12):1600-5.
36. Berguiga M, Galatoire O. Tear trough rejuvenation: a safety evaluation of the treatment by a semi-cross-linked hyaluronic acid filler. *Orbit.* 2017;36(1):22-6.
37. Diwan Z et al. A prospective study on safety, complications and satisfaction analysis for tear trough rejuvenation using hyaluronic acid dermal fillers. *Plast Reconstr Surg Glob Open.* 2020;8(4):e2753.
38. Cotofana S et al. The surface-volume

- coefficient of the superficial and deep facial fat compartments: a cadaveric three-dimensional volumetric analysis. *Plast Reconstr Surg.* 2019;143(6):1605-13.
39. Cotofana S, Lachman N. Arteries of the face and their relevance for minimally invasive facial procedures: an anatomical review. *Plast Reconstr Surg.* 2019;143(2):416-26.
40. Walker L, Cetto R, Facial Ageing and Injection Anatomy: An Evidence Based Compendium (2021), Tyne and Wear: UK Book Publishing.
41. Tansatit T et al. Implication of location of the ascending mental artery at the chin injection point. *Plast Reconstr Surg.* 2020;145(1):51e-7e.
42. Huettner F et al. The relationship of the marginal mandibular nerve to the mandibular osseocutaneous ligament and lesser ligaments of the lower face. *Aesthet Surg J.* 2015;35(2):111-20.
43. Lamb JP et al., "The perioral area, the chin, and the jowl," Lamb JP, Curek CC (eds.) *Facial Volumization: An Anatomic Approach* (2018), Stuttgart: Thieme, pp.37-58.
44. Mendelson BC et al. Surgical anatomy of the lower face: the premaseter space, the jowl, and the labiomandibular fold. *Aesthetic Plast Surg.* 2008;32(2):185-95.
45. Vazirnia A et al. Nonsurgical jawline rejuvenation using injectable fillers. *J Cosmet Dermatol.* 2020;19(8):1940-7.
46. Bertossi D et al. Nonsurgical redefinition of the chin and jawline of younger adults with a hyaluronic acid filler: results evaluated with a grid system approach. *Aesthet Surg J.* 2020;41(9):1068-76.

FOR REPRINT QUERIES PLEASE CONTACT: [INFO@EMJREVIEWS.COM](mailto:INFO@EMJREVIEWS.COM)



# Abstract Reviews

Sharing late-breaking advancements and key developments from abstracts presented by key experts in the field of dermatology at the European Academy of Dermatology and Venereology (EADV) Congress 2021.

## Androgenetic Alopecia: Predictive Factor for COVID-19 Severity

**Authors:** Maria Rotaru,<sup>1,2</sup> \*Gabriela Iancu,<sup>1,2</sup> Ramona Farhat<sup>1</sup>

1. Dermatovenerology Clinic, Emergency Hospital of Sibiu County, Romania

2. Dermatology Department, Faculty of Medicine, Lucian Blaga University of Sibiu, Romania

\*Correspondence to [gabriela.iancu@ulbsibiu.ro](mailto:gabriela.iancu@ulbsibiu.ro)

**Disclosure:** The authors have declared no conflicts of interest.

**Keywords:** Androgen receptor, androgenetic alopecia (AGA), COVID-19, transmembrane protease serine 2 (TMPRSS2).

**Citation:** EMJ Dermatol. 2021;9[1]:51-52. Abstract Review No. AR1.

### BACKGROUND

Since December 2019, the new severe acute respiratory syndrome coronavirus-2 (SARS-

CoV-2) from Wuhan, China, has been the aetiological agent of COVID-19 disease, an infectious disease that has evolved into a global pandemic.<sup>1</sup> Androgenetic alopecia (AGA), the most common type of alopecia,<sup>2</sup> is an androgen-dependent condition, the main androgen responsible for the follicular pathology being dihydrotestosterone.<sup>3</sup>

### MATERIALS AND METHODS

The authors reviewed nine articles studying the high rates of AGA in patients hospitalised with severe forms of COVID-19 that have been published in the last year. The multifaceted nature of this disease has been an incentive for many medical specialties to try to uncover its mechanisms, and dermatology is playing a part in this journey. The authors summarised the information they gathered on the topic and obtained the following results.

### RESULTS

Recent studies suggest that males with AGA have a disproportionate risk relative to females

of developing severe, symptomatic forms of COVID-19 through an androgen-mediated vulnerability to SARS-CoV-2.<sup>4-6</sup> Sensitivity to androgen hormones is determined by genetic variants of the androgen receptor (AR). X-linked genetic polymorphisms that have been associated with androgenetic alopecia, benign prostatic hyperplasia, prostate cancer,<sup>7</sup> and polycystic ovary syndrome<sup>8</sup> may be responsible for an increase in host susceptibility, with AR being the only known promoter of transmembrane protease serine 2 (TMPRSS2). TMPRSS2 is an enzyme involved in SARS-CoV-2 infectivity by initiating the virus' spike protein, a key step in viral replication and cell-virus fusion.<sup>5</sup> In addition to theoretical molecular and epidemiological mechanisms, several studies have reported high rates of androgenetic alopecia in patients hospitalised with severe forms of COVID-19.<sup>2,4-6,9,10</sup>

## CONCLUSION

The mechanism of regulation of TMPRSS2 by androgen hormones may explain the increased susceptibility of males to COVID-19. This pathophysiological process can also motivate the less symptomatic forms of children, given their reduced AR expression.<sup>5</sup> The investigation of the potential association between androgens and the severity of COVID-19 disease is justified in view of evaluating androgen suppression therapy as a potential treatment for COVID-19 infection. ■

## Histopathological Findings in COVID-19 Necrotic Lesions

**Authors:** \*Antonella Tammaro,<sup>1</sup> Ganiyat Adenike Ralitsa Adebajo,<sup>1</sup> Camilla Chello,<sup>1</sup> Francesca Romana Parisella,<sup>2</sup> Daniele Colombo,<sup>3</sup> Alessandra Scarabello,<sup>4</sup> Gabriella De Marco,<sup>1</sup> Franca Del Nonno<sup>3</sup>

1. NESMOS Dermatology Department, Sapienza University of Rome, Italy
2. Department of Medicine, The University of Queensland, Brisbane, Australia

## References

1. Goren A et al. A preliminary observation: male pattern hair loss among hospitalized COVID-19 patients in Spain – a potential clue to the role of androgens in COVID-19 severity. *J Cosmet Dermatol.* 2020;19(7):1545-7.
2. Lee J et al. Male balding is a major risk factor for severe COVID-19. *J Am Acad Dermatol.* 2020;83(5):e353-4.
3. McCoy J et al. Androgen receptor genetic variant predicts COVID-19 disease severity: a prospective longitudinal study of hospitalized COVID-19 male patients. *J Eur Acad Dermatol Venereol.* 2021;35:e15-7.
4. Mjaess GT et al. COVID-19 and the male susceptibility: the role of ACE2, TMPRSS2 and the androgen receptor. *Prog Urol.* 2020;30(10):484-7.
5. Moravvej H et al. Androgenetic alopecia and COVID-19: a review of the hypothetical role of androgens. *Dermatol Ther.* 2021;34(4):e15004.
6. Wambier CG et al. Androgenetic alopecia present in the majority of patients hospitalized with COVID-19: the "Gabrin sign." *J Am Acad Dermatol.* 2020;83(2): 680-2.
7. Thatiparthi A et al. A response to "Male balding is a major risk factor for severe COVID-19." *J Am Acad Dermatol.* 2021;84(2):e87-8.
8. Sajid MI et al. SARS-CoV-2 & androgenic alopecia: exploring links! *Int J Dermatol.* 2021;60(5):e195-7.
9. Wambier CG, Goren A. Severe acute respiratory syndrome coronavirus 2 (SARS-CoV-2) infection is likely to be androgen mediated. *J Am Acad Dermatol.* 2020;83(1):308-9.
10. Wambier CG et al. Androgenetic alopecia in COVID-19: compared to age-matched epidemiologic studies and hospital outcomes with or without the Gabrin sign. *J Am Acad Dermatol.* 2020;83(6):e453-4.

3. Pathology Unit, National Institute of Infectious Diseases Lazzaro Spallanzani, Rome, Italy
  4. Dermatology Unit, National Institute of Infectious Diseases Lazzaro Spallanzani, Rome, Italy
- \*Correspondence to [tammaroantonella@gmail.com](mailto:tammaroantonella@gmail.com)

**Disclosure:** The authors have declared no conflicts of interest.

**Acknowledgements:** The patient in this case has given informed consent to publication of their images and case details.

**Keywords:** COVID-19, histopathology, necrotic lesion, severe acute respiratory syndrome coronavirus 2 (SARS-CoV-2), skin.

**Citation:** *EMJ Dermatol.* 2021;9[1]:52-54. Abstract Review No. AR2.

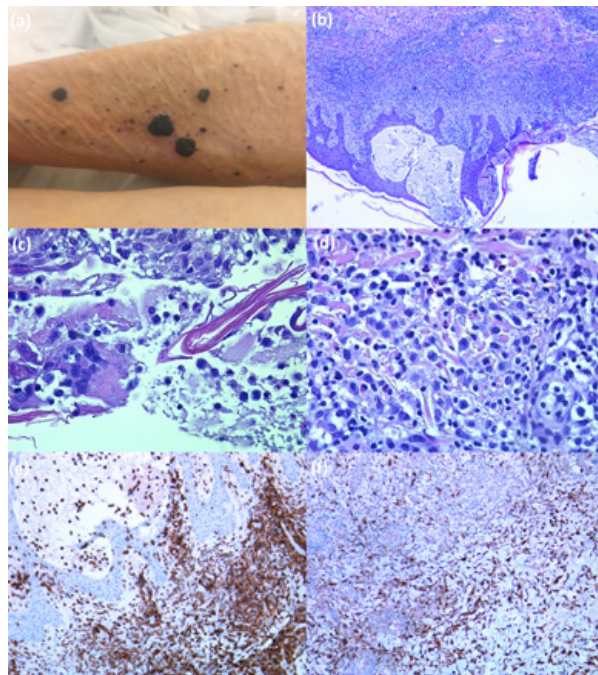
## BACKGROUND

One year after the identification of the novel severe acute respiratory syndrome 2 (SARS-CoV-2) infection in Wuhan, China, and the outbreak of the virus worldwide, the pandemic state persists, and the management of COVID-19 remains burdensome, with the number of people infected daily increasing progressively in most countries and the death rate being alarmingly elevated.<sup>1</sup> Since the elevated rate of infectivity of the virus, the authorisation of histological examination has been a harsh process, with high-risk of contagiousness even in qualified medical personnel.<sup>2</sup> However, thanks to the recently published histological reports, more about the pathogenic mechanism underlying

viral-derived tissue damage has been understood. In this report, the authors describe a patient hospitalised for COVID-19 who developed necrotic acral lesions that were biopsied.

## CASE REPORT

An 83-year-old female came to the emergency department because of acute respiratory distress, which required oxygen therapy. An oronasal swab was performed to identify SARS-CoV-2 RNA and the test resulted positive. Due to her rapidly deteriorating clinical condition, the patient was admitted to the infectious disease ward. Five days after her inpatient stay, she developed vesicular lesions on the lower



**Figure 1: Gross and microscopy appearance of the necrotic lesions of a patient with COVID-19.**

**A)** Multiple necrotic lesions on the lower limb of the patient. There are four main lesions and numerous other lesions with smaller diameters. **B)** Histological examination showing an intraepidermal vesicle and dense inflammatory infiltrate within the dermis (H&E 10x). **C)** Histology of the necrotic lesions. The lumen of the blister contains histiocytes and multinucleated giant cells (H&E 40x). **D)** Histology of the necrotic lesions. Many eosinophils associated with lymphocytes and histiocytes in the superficial dermis (H&E 40x). **E)** Numerous dermal and intraepidermal inflammatory cells are T lymphocytes as demonstrated with anti-CD3 rabbit monoclonal primary antibody 2GV6 (100x immunohistochemistry with haematoxylin counterstain using Ventana Ultraview DAB detection Kit in a Ventana BenchMark Ultra Processor® [Ventana Medical Systems, Tuscon, Arizona, USA]). **F)** Histology of the necrotic lesions. The lymphocytes are mixed with numerous macrophages as demonstrated with anti-CD68 (KP-1) antibody (100x immunohistochemistry with haematoxylin counterstain using Ventana Ultraview DAB detection Kit in a Ventana BenchMark Ultra Processor®).

CD: cluster of differentiation; H&E: haematoxylin and eosin staining.

limbs, which quickly became necrotic (Figure 1). A skin biopsy was performed, and the histopathology report evidenced a dermal-epidermal inflammatory infiltrate made of lymphocytes, histiocytes, neutrophils, and eosinophils, which displayed either an interstitial and periannexial distribution or a perivascular one with endothelial swelling and detachment.

The epidermis demonstrated spongiosis, erosion, and vesicles with mild keratinocyte acantholysis, and inflammatory cells (lymphocytes, histiocytes, and multinucleate giant cells [Figure 1]).

The inflammatory infiltrate was composed mainly by T cells (CD3+, CD4+, and CD8+), histiocytes (CD68+), with rare B cells (CD20+) and activated blasts (CD30+) (10–20%). Moreover, many mitotic figures were evident (Ki67). No natural killer cells were detected (CD56+) and no Epstein-Barr virus-LMP1 viral protein was present. In addition, myeloperoxidase, CD34, and Mart1 were negative. This morphologic report led to the identification of the lesions as SARS-CoV-2-related papulovesicular eruptions.

## DISCUSSION AND CONCLUSIONS

Mounting scientific evidence has emerged regarding the manifestations of SARS-CoV-2 infection on the skin. Regarding histological reports, while several cases of cutaneous manifestations have been described, relatively few cases were subjected to biopsy because of the numerous limitations imposed in medical centres. Current data reports different histological pictures related to specific clinical aspects.<sup>3</sup>

The maculopapular lesions show lymphocytic exocytosis, with thrombosed vessels filled with neutrophils and eosinophils; conversely, dermatitis is characterised by infiltrated perivascular lymphocyte, focal elements of suprabasal acantholysis, dyskeratotic cells, and swollen vessels with mixed lymphocyte infiltration in the dermis.<sup>3</sup> Vesicular

(varicella-like) eruptions show dyskeratotic cells with acantholysis, intraepidermal vesicles, and suspected viral inclusions within multinucleate cells.<sup>3</sup>

Compellingly, a retrospective analysis carried out on 23 patients with COVID-19 and with cutaneous manifestations showed that, at histopathological level, microvascular and endothelial damage were evident. Infiltrating perivascular lymphocytes, thrombosis, and swollen vessels were present and C5b deposits were predominant.<sup>4</sup> Of note, the activation of the complement system and coagulation cascade had already been identified as responsible for vascular clinical manifestations such as thrombosis and necrosis. However, in the authors' case, the presence of abundant infiltrating lymphocyte, dilated vessels, and epidermal vesicles filled with inflammatory infiltrators without obvious elements of thrombosis may suggest a combination of direct viral and immune mediated damage.

Further studies are needed to better understand the skin involvement in COVID-19, in terms of clinical characteristics, evolution, and correlation with the severity of the disease, and the pathological mechanism responsible for cutaneous damage. From the data published so far, it can be assumed that the visible skin lesions are the result of a combination of the direct action of the virus and the immune signalling cascade induced by it. ■

### References

1. Baud D et al. Real estimates of mortality following COVID-19 infection. *Lancet Infect Dis.* 2020;20(7):773.
2. Brook OR et al. Feasibility and safety of ultrasound-guided minimally invasive autopsy in COVID-19 patients. *Abdom Radiol.* 2021;46(3):1263-71. [Epub ahead of print].
3. Kaya G et al. Clinical and histopathological features and potential pathological mechanisms of skin lesions in COVID-19: review of the literature. *Dermatopathology (Basel).* 2020;7(1):3-16.
4. Magro CM et al. Severe COVID-19: A multifaceted viral vasculopathy syndrome. *Ann Diagn Pathol.* 2020;50:151645. [Epub ahead of print].

# Sexually Transmitted Infections in Northern Greece During the COVID-19 Pandemic

**Authors:** \*Theodoros Sidiropoulos,<sup>1</sup> Iordana Toumpa,<sup>1</sup> Despoina Noukari,<sup>1</sup> Maria Goula,<sup>1</sup> Aimilios Lallas,<sup>2</sup> Zoe Apalla<sup>3</sup>

1. State Dermatology Department, Hospital of Skin and Venereal Diseases, Thessaloniki, Greece
2. First Dermatology Department, School of Medicine, Faculty of Health Sciences, Aristotle University of Thessaloniki, Greece
3. Second Dermatology Department, School of Medicine, Faculty of Health Sciences, Aristotle University of Thessaloniki, Greece

\*Correspondence to [tsidiropoulos@hotmail.com](mailto:tsidiropoulos@hotmail.com)

**Disclosure:** The authors have declared no conflicts of interest.

**Keywords:** COVID-19 pandemic, gonorrhoea, sexually transmitted infections, syphilis.

**Citation:** EMJ Dermatol. 2021;9[1]:55-56. Abstract Review No. AR3.

## BACKGROUND

During the COVID-19 outbreak, many countries imposed restrictive measures that resulted in unprecedented modifications in healthcare services.<sup>1</sup> In several countries, including Greece, most of the public hospitals were practically transformed into COVID-19 units. In addition, public and health authorities repeatedly advised the population to avoid visiting hospitals during the pandemic outbreak. Moreover, social and sexual behaviour dramatically altered as a result of the strict social distancing measures.

Sexually transmitted diseases (STDs), though generally deemed as a major social health problem, rarely end up as an urgent life-threatening condition.<sup>2</sup> Therefore, it is not surprising that the findings of studies from several countries reported a reduced number of STDs diagnosed in 2020 as compared with previous years.<sup>3</sup>

## MATERIALS AND METHODS

The authors reviewed records of the STDs clinic of the State Hospital of Skin and Venereal Diseases, Thessaloniki, Greece, to identify newly diagnosed cases of gonorrhoea and syphilis from 1<sup>st</sup> March–30<sup>th</sup> October, 2020 and compared it with the respective numbers of the same period in 2019.

## RESULTS

The total number of new diagnoses of syphilis and gonorrhoea in 2020 was 91, whereas in 2019 it was 108. The number of newly diagnosed cases of syphilis in 2020 was 72, slightly lower than the 85 cases of 2019 ( $p=0.943$ ). Similarly, 19 patients were diagnosed in 2020 with gonorrhoea, fewer than the 23 diagnosed in 2019 ( $p=0.943$ ). Regarding sexual preference, the percentage of heterosexual individuals was significantly lower in 2020, while the percentage of homosexual individuals was higher. The ratio of native Greek patients to foreign patients was comparable in 2020 and 2019. Results are summarised in [Table 1](#).

## DISCUSSION

A reduction in newly diagnosed STDs was reported in several other countries during the COVID-19 outbreak. The most remarkable reduction was recorded in Madrid, Spain, where researchers reported a reduction of new syphilis and gonorrhoea cases in the first 26 weeks of 2020 by 73.2% and 81.4%, respectively, as compared with the same period of 2019.<sup>4</sup> In Switzerland, syphilis diagnoses were reduced by 84.8% and gonorrhoea diagnoses reduced by 16.5% in 2020, as compared with 2019.<sup>5</sup> In China, new syphilis diagnoses in 2020 were reduced by 8.2% as compared with 2019.<sup>6</sup>

A direct comparison of these percentages in the authors' hospital is significantly limited by the heterogeneity of used data in terms of collection and reporting. In Greece, the authors' hospital maintained, uninterruptedly, its function throughout the year and was never involved in hospitalising patients with COVID-19. Therefore, the impact of restricted access on the number of newly diagnosed STDs should, reasonably, be less

**Table 1: Results.**

	2020	2019	p
<b>Referral centre</b>			
Thessaloniki (Hospital for Venereal and Skin Diseases)	91 (21.5%)	108 (20.7%)	NA
<b>Sex</b>			
Male	81 (89%)	92 (85.2%)	0.425
Female	10 (11%)	16 (14.8%)	
<b>Sexual Preference</b>			
Heterosexual	25 (27.5%)	49 (45.4%)	0.034
Homosexual	51 (56%)	45 (47.1%)	
Bisexual	15 (16.5%)	14 (13%)	
<b>Nationality</b>			
Greek	76 (83.5%)	92 (85.2%)	0.746
Other	15 (16.5%)	16 (14.8%)	
<b>Syphilis</b>			
Primary	43 (59.7%)	59 (69.4%)	0.205
Latent	29 (40.3%)	26 (30.6%)	
<b>Gonorrhoea</b>	19	23	0.943

NA: not applicable.

evident. Despite of the different magnitude of the reported trends, data from all countries converge to the conclusion that considerably fewer STDs were diagnosed in 2020 as compared with 2019.

The reduced number of newly diagnosed STDs could be attributed to various reasons. Limited access or unwillingness of patients to visit a hospital in the fear of COVID-19 transmission is a potential explanation. Social distancing and fear of physical contact that might enhance transmission as well as banned entertainment activities that facilitate casual sex further contribute to the reduction in STDs.

Considering potential long-term consequences of undiagnosed STDs and the significant impact they might have on social health, the authors results, along with those from other countries, highlight the need of uninterrupted testing and treatment of STDs during a pandemic course. ■

### References

1. World Health Organization (WHO). Maintaining essential health services: operational guidance for the COVID-19 context. 2019. Available at: [https://www.who.int/publications/i/item/WHO-2019-nCoV-essential\\_health\\_services-2020.2](https://www.who.int/publications/i/item/WHO-2019-nCoV-essential_health_services-2020.2). Last accessed: 18 October 2021.
2. World Health Organization (WHO). Report on global sexually transmitted infection surveillance 2018. 2018. Available at: <http://apps.who.int/iris/bitstream/handle/10665/277258/9789241565691-eng.pdf?ua=1>. Last accessed: 18 October 2021.
3. Latini A et al. Is COVID-19 affecting the epidemiology of STIs? The experience of syphilis in Rome. *Sex Transm Infect.* 2021;97(1):78. [Epub ahead of print].
4. de Miguel Buckley R et al. Social distancing to combat COVID-19 led to a marked decrease in food-borne infections and sexually transmitted diseases in Spain. *J Travel Med.* 2020;27(8):taaa134.
5. Steffen R et al. Travel restrictions and lockdown during the COVID-19 pandemic-impact on notified infectious diseases in Switzerland. *J Travel Med.* 2020;27(8):taaa180.
6. Chia CC et al. Diagnoses of syphilis and HIV infection during the COVID-19 pandemic in Taiwan. *Sex Transm Infect.* 2021;97(4):319. [Epub ahead of print].

# Treatment of Facial Cutaneous Leishmaniasis with Photodynamic Therapy

**Authors:** \*Francesc Alamon-Reig,<sup>1</sup> Ignasi Martí-Martí,<sup>1</sup> Constanza Riquelme-Mc Loughling,<sup>1</sup> Adriana Garcia,<sup>2</sup> Cristina Carrera,<sup>1</sup> Paula Aguilera-Peiró<sup>1</sup>

1. Department of Dermatology, Hospital Clínic de Barcelona, University of Barcelona, Spain

2. Department of Pathology, Hospital Clínic de Barcelona, University of Barcelona, Spain

\*Correspondence to [alamon@clinic.cat](mailto:alamon@clinic.cat)

**Disclosure:** The authors have declared no conflicts of interest.

**Keywords:** Cutaneous leishmaniasis (CL), daylight-activated photodynamic therapy, leishmania, photodynamic therapy, reflectance confocal microscopy (RCM).

**Citation:** EMJ Dermatol. 2021;9[1]:57-59. Abstract Review No. AR4.

## BACKGROUND

Leishmaniasis is a widespread protozoan zoonosis transmitted by sandflies that can cause a wide range of clinical manifestations. Cutaneous leishmaniasis (CL) is the most common form, usually presenting as a small papule on an exposed skin area that enlarges and finally ulcerates. Therapies for CL are limited, and the systemic treatments available are hampered by toxicity and parasite resistance. As an alternative, photodynamic therapy (PDT) has been reported to be a safe and effective treatment for CL.<sup>1,2</sup>

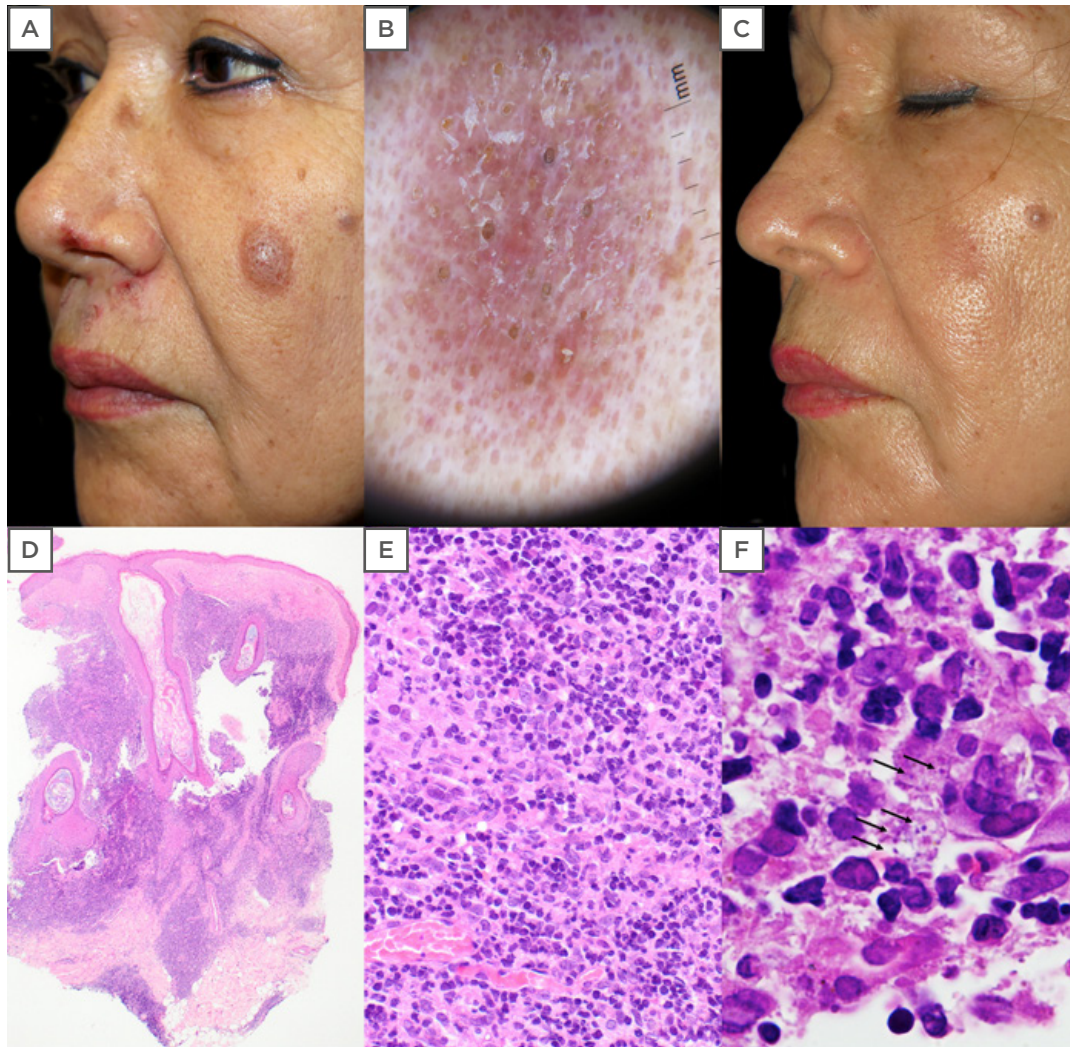
## CASE REPORT

A female in her 60s presented with a solitary violaceous papule on her left cheek that had progressively enlarged over the previous 4 months (Figure 1A). Travel history was significant for a trip to Peru, in urban areas, 1 year prior to the current chief complaint. Dermoscopy examination

showed comedo-like openings and few focused telangiectasias (Figure 1B). Reflectance confocal microscopy (RCM) revealed dilated follicular openings in the epidermis, marked adnexal structures, and prominent horizontal vessels in the superficial dermis. Histological examination showed non-necrotizing granulomas and intracytoplasmic structures compatible with amastigotes, confirming the diagnosis of CL (Figure 1D-F). The patient was treated with three courses of photodynamic therapy. A CO<sub>2</sub> fractional laser was used as a drug delivery technique.<sup>3</sup> After the third session, the lesion showed complete clinical response with excellent cosmetic results (Figure 1C). To confirm treatment response, RCM was performed demonstrating a regular honeycomb pattern, an unremarkable dermoepidermal junction, and normal dermal features 2 months later. The patient has not presented a relapse of the lesion during follow-up.

## DISCUSSION

Although CL is usually a self-limited infection, treatment is advised to avoid ulceration, scarring, or disease progression. CL may constitute a therapeutic challenge, since evidence for an optimal treatment is ambiguous.<sup>4</sup> Systemic drugs have potential adverse effects, and the risks and benefits of the available therapies should be discussed with every patient. In recent years, PDT has been introduced as a safe and effective alternative therapy for CL, with only mild side effects and excellent cosmetic outcomes.<sup>1,5</sup> It has been reported as a successful treatment for CL in at least 75 cases, some with complex CL due to facial involvement. PDT protocols for treating CL have not yet been standardised. In most reported cases, topical 5-aminolevulinic acid or methyl aminolevulinate were applied as photosensitisers, followed by incubation and red-light irradiation, with 3–8 weekly sessions. Despite the limitation of in-depth evaluation, RCM can help to rule out common tumours of the face as it can show findings more suggestive of CL such as dilated linear and comma-shaped vessels, follicular plugging, and the presence of multinucleated giant cells in the superficial dermis.<sup>6</sup> RCM, along with dermoscopy, could be a useful, non-invasive tool, not only to provide an *in vivo* diagnosis, but also to monitor



**Figure 1:** **A)** Initial clinical presentation showing a violaceous plaque on the left cheek. The patient also presented with multiple grouped erosions with superficial crusts on her upper lip and surrounding her left nasal meatus consistent with a *Herpes Simplex* recurrence; **B)** dermoscopy revealed superficial scales, orange comedo-like openings and white interfollicular structures over an erythematous background (DL100, 3Gen, California); **C)** clinical resolution after three sessions of photodynamic therapy, leaving a residual hypopigmented superficial scar; **D)** lesional biopsy specimen. Histological findings of flattened epidermis, with marked dilation of the follicular infundibulum and a mixed dermal inflammatory infiltrate with sparing of the papillary region (H-E, x2); **E)** inflammatory infiltrate consisting primarily of lymphocytes, plasma cells, and histiocytes in the dermis (H-E, x40); **F)** scattered intracytoplasmic structures (arrows), consistent with leishmania amastigotes (H-E, x100).

H-E: haematoxylin and eosin stain.

healing, avoiding unnecessary biopsies or additional PDT sessions.

## CONCLUSION

PDT is an effective and well-tolerated therapeutic option for the treatment of simple CL. The use of fractional CO<sub>2</sub> lasers as a drug-delivery method could improve the results and shorten the number of PDT sessions needed. Further studies are needed to evaluate its use in cosmetically

relevant regions and establish the optimal PDT protocol for treating CL. RCM is a promising complementary tool in the diagnosis and follow-up of patients with CL. ■

## References

1. Asilian A, Davami M. Comparison between the efficacy of photodynamic therapy and topical paromomycin in the treatment of Old World cutaneous leishmaniasis: a placebo-controlled, randomized clinical trial. *Clin Exp Dermatol.* 2006;31(5):634-7.



- Aronson N et al. Diagnosis and Treatment of Leishmaniasis: Clinical Practice Guidelines by the Infectious Diseases Society of America (IDSA) and the American Society of Tropical Medicine and Hygiene (ASTMH). *Clin Infect Dis*. 2016;63(12):1539-57.
- Choi JH et al. Comparative analysis of the effects of CO<sub>2</sub> fractional laser and sonophoresis on human skin penetration with 5-aminolevulinic acid. *Lasers Med Sci*. 2017;32(8):1895-900.
- Palumbo E. Current treatment for cutaneous leishmaniasis: a review. *Am J Ther*. 2009;16(2):178-82.
- Slape DR-M et al. Leishmania tropica successfully treated with photodynamic therapy. *Australas J Dermatol*. 2019;60(1):e64-e65.
- Alarcon I et al. *In vivo* confocal microscopy features of cutaneous leishmaniasis. *Dermatology*. 2014;228(2):121-4.

## Defining ‘Freedom from Disease’ in Plaque Psoriasis: Preliminary Outputs Using Delphi Methodology, Involving Nurses, Physicians, and People with Psoriasis

**Authors:** Anthony Bewley,<sup>1</sup> \*Elfie Deprez<sup>2</sup>

- Consultant Dermatologist, Barts Health NHS Trust and Queen Mary University of London, UK
- Nurse and PhD student, Ghent University Hospital, Belgium

\*Correspondence to [Elfie.Deprez@uzgent.be](mailto:Elfie.Deprez@uzgent.be)

**Disclosure:** This study was sponsored by Janssen. Deprez received consulting fees from Janssen. Bewley received ad hoc honoraria or travel grants from AbbVie, Ammirall, Eli Lilly, Galderma, Janssen, LEO Pharma, Novartis, Sanofi, and UCB.

**Acknowledgements:** The authors would like to thank all other members of the Delphi consensus panel: Ilse van Ee, Alexander Egeberg, Matthias Augustin, Curdin Conrad, Valeria Corazza, Ludovica Donati, Jo Lambert, Rozalina Lăpădatu, Anette Meyer, Carle Paul, Rebecca Penzer-Hick, Karen Stephen, and Jim van der Zon.

**Support:** Medical writing and editorial support were provided by Cello Health Communications (Europe), sponsored by Janssen.

**Keywords:** Delphi consensus, health-related quality of life, psoriasis.

**Citation:** *EMJ Dermatol*. 2021;9[1]:59-60. Abstract Review No. AR5.

### BACKGROUND

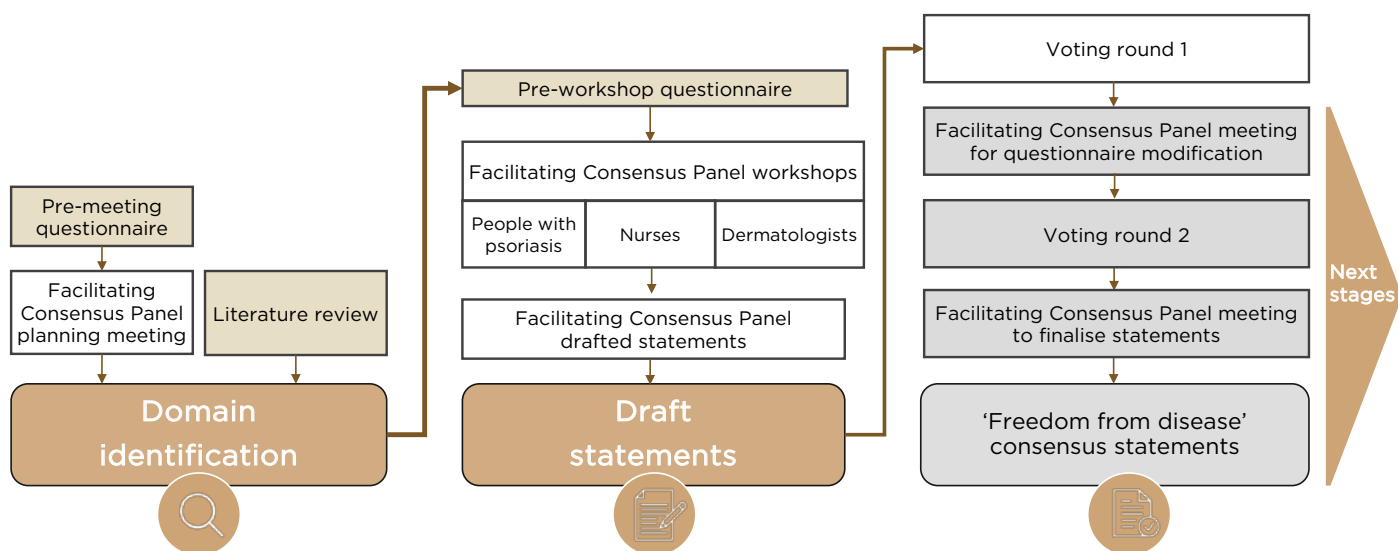
Psoriasis is a chronic disease associated with high disease burden, and its impact on well-being and health-related quality of life is often underestimated.<sup>1,2</sup> On top of well-known skin symptoms, psoriasis can also affect mental health, daily social activities, and work. Most outcome measures used in psoriasis focus primarily on skin symptoms. Although scales such as the Dermatology Life Quality Index (DLQI) may capture some aspects of psoriasis-related impact on health-related quality of life, they do not capture the full experience of people living with psoriasis, and individuals with psoriasis may have different criteria for judging their treatment success. With the advent of highly effective psoriasis medications, there has been a growing interest in the complete clearance of skin symptoms but less attention to what complete ‘freedom from disease’ means for people with psoriasis.

### METHODS

The ongoing study discussed in this abstract review aims to build a unified consensus on the definition of ‘freedom from disease’ supported by both people with psoriasis and their healthcare providers. This will be achieved using a modified Delphi consensus method involving a consensus panel comprising six people with psoriasis, three nurses, and six dermatologists from different European countries (Figure 1).

### RESULTS

The panel performed a literature review and held a planning meeting to identify the main



**Figure 1: Modified Delphi approach to build consensus on the definition of 'freedom from disease' for people with psoriasis.**

domains involved in freedom from disease, which were established to be 'management of clinical symptoms', 'psychosocial elements', 'quality of life and well-being', 'treatment', and 'healthcare team support'. Following identification of the main domains, subsequent workshops were held to draft lists of statements representing aspects of each domain. These statements were put forward to a voting group comprising 166 respondents (of which 129 were people with psoriasis) who rated each statement according to its importance to them. Aspects of freedom from disease rated as high-priority in this first voting round included being clear of lesions on visible locations and intimate areas, the possibility to live a normal life, quality of life being independent from psoriasis, a desire to have access to and understanding of effective treatments, and a good relationship with healthcare providers.

In the next stage of the consensus process, the panel will assess the results from the initial voting round, revise the statements, and put the

revised statements forward to the voting group for a second round of voting. The results from this final voting round will form the basis for the consensus statement.

## CONCLUSION

This Delphi consensus gives people with psoriasis an equal share of voice at every stage of the process, in line with recommendations for people-centred care from the World Health Organization. Once completed, this Delphi process will provide a broad consensus on the meaning of 'freedom from disease', a potential new treatment target supported by both people with psoriasis and their healthcare providers. ■

## References

1. Bhosle MJ et al. Quality of life in patients with psoriasis. *Health Qual Life Outcomes*. 2006;4:35.
2. Moon HS et al. Psoriasis and psycho-dermatology. *Dermatol Ther (Heidelb)*. 2013;3(2):117-30.

# Diagnostic and Management Challenges of Erosive Pustular Dermatitis of the Scalp: A Retrospective Study in a Greek Population

**Authors:** \*Styliani Siskou,<sup>1,2</sup> Aimilios Lallas,<sup>3,4</sup> Konstantinos Theodoropoulos,<sup>5</sup> Dimitrios Sgouros,<sup>5</sup> Myrto Trakatelli,<sup>1</sup> Aikaterini Patsatsi,<sup>1</sup> Anastasia Trigoni,<sup>1</sup> Magdalini Manoli,<sup>3,4</sup> Chrissyoula Papageorgiou,<sup>1,3</sup> Konstantinos Liopyris,<sup>6</sup> Alexandros Katoulis,<sup>5</sup> Alexandros Stratigos,<sup>6</sup> Dimitrios Ioannides,<sup>4</sup> Elizabeth Lazaridou,<sup>1</sup> Zoe Apalla<sup>1,3</sup>

1. Second Dermatology Department, School of Medicine, Faculty of Health Sciences, Aristotle University of Thessaloniki, Greece
2. Department of Epidemiology and Population Health, London School of Hygiene and Tropical Medicine, UK
3. Dermomedica, Dermatology Unit, Thessaloniki, Greece
4. First Dermatology Department, School of Medicine, Faculty of Health Sciences, Aristotle University of Thessaloniki, Greece
5. Second Dermatology Department, Kapodistrian University of Athens, Attikon Hospital, Greece
6. First Dermatology Department, Kapodistrian University of Athens, Andreas Syggros Hospital, Greece

\*Correspondence to [drsiskou@gmail.com](mailto:drsiskou@gmail.com)

**Disclosure:** The authors have declared no conflicts of interest.

**Acknowledgements:** Siskou and Lallas contributed equally to the preparation of this manuscript; Lazaridou and Apalla contributed equally in their role as senior authors.

**Keywords:** Diagnosis, erosive pustular dermatitis of the scalp (EPDS), non-melanoma skin cancer, risk factors, topical treatment.

**Citation:** EMJ Dermatol. 2021;9[1]:61-63. Abstract Review No. AR6.

## BACKGROUND

Erosive pustular dermatitis of the scalp (EPDS) is an inflammatory disorder of unknown aetiology, characterised by erosions, pustules, and crusts on a bed of atrophic skin.<sup>1-7</sup> Risk factors include elderly age, actinic damage, androgenetic alopecia, and preceding trauma.<sup>1-7</sup> It has long been considered a rare disease but recent reports suggest that it may be more frequent than previously thought.

## MATERIALS AND METHODS

The authors conducted a retrospective, observational, multicentre study. They reviewed records of patients with clinically and histologically confirmed EPDS for baseline characteristics, time to diagnosis, treatments received, and outcomes. Treatment options included potent topical steroids (TS) under occlusion, topical calcineurin inhibitors (TCi) usually under occlusion, and systemic retinoids. A cycle of TS was defined as daily application for 2 weeks, followed by gradual de-escalation for a further 2 weeks. Follow-up visits were scheduled every 4 weeks. Outcomes were recorded as complete response (complete clinical resolution), partial response (30% or higher reduction of the affected area), progressive disease (20% or higher increase of the affected area), and stable disease. Deterioration and recurrence were defined as at least 20% loss of previous partial response and complete response, respectively. The statistical package STATA version 14.2 (StataCorp, College Station, Texas, USA) was used for data analysis. Twenty-four patients (22 males, two females) were included in the study. The majority were photodamaged (n=20/24 [83.3%]). The most commonly affected site was the vertex (n=19/24 [79.2%]). Twenty-two individuals (91.7%) had a positive non-melanoma skin cancer history, with actinic keratoses (AK) being the most frequently observed type (n=18/24 [75.0%]). Most patients had been treated with cryotherapy (n=17/24 [70.8%]) and imiquimod (n=14/24 [58.3%]).

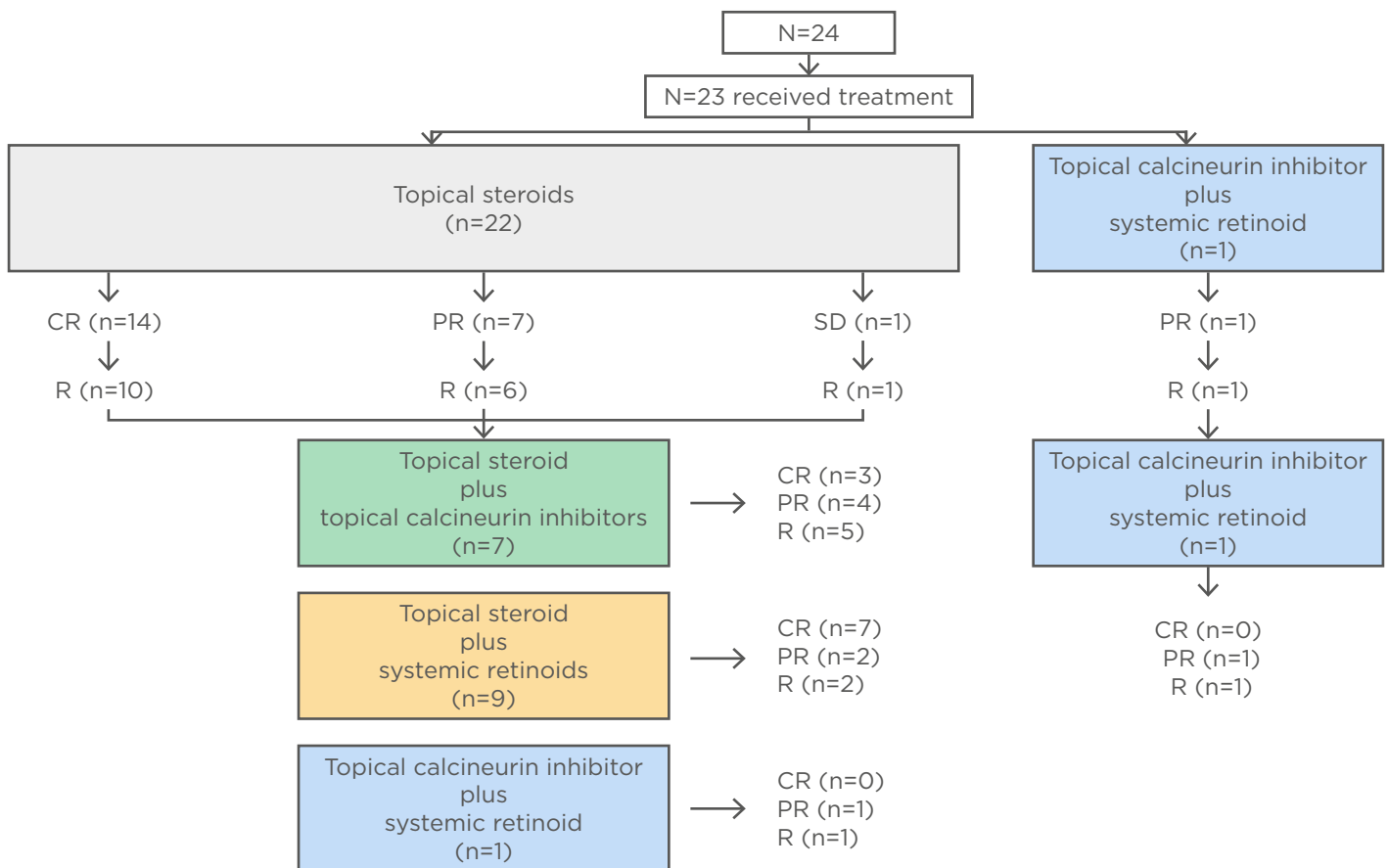
## RESULTS AND DISCUSSION

At first follow-up visit, from 22 patients treated with TS, 14 (63.6%) showed complete response, seven (31.8%) partial response, and one (4.6%) stable disease. After treatment cessation, the majority (78.3%) experienced a recurrence or deterioration at a median time of 8 weeks (interquartile range: 4-12 weeks; range: 2-16 weeks). Recurrence or deterioration was managed with either a TS cycle combined with 25 mg of acitretin daily (acitretin was continued after TS withdrawal as maintenance treatment); a TS cycle followed by TCi as maintenance treatment; or TCi in combination with 25 mg of acitretin, both in continuous application. New recurrences were observed in two out of nine patients (22.2%) that received acitretin, and in five out of seven patients (71.4%) that received TCi as maintenance treatment (Figure 1).

The authors' descriptive analysis of baseline characteristics of patients with EPDS

conform with most recent publications.<sup>4,6,7,8</sup> EPDS is diagnostically challenging due to a clinical overlap with other entities, including non-melanoma skin cancer, fungal/bacterial infections, bullous dermatoses, and folliculitis decalvans.<sup>4,5,9,10</sup> Considering that it often develops in the background of field cancerisation, presence of actinic damage in the skin specimen may act as a misleading feature for the pathologist too, who may ultimately report the lesion as actinically damaged skin. The latter may result in further topical/destructive therapies that maintain the vicious circle of inflammation-impaired healing.

The management of EPDS is also challenging. Despite its responsiveness to TS,<sup>3,4,6,10</sup> recurrence after treatment cessation is the rule.<sup>3,4,6,10</sup> Prolonged use of TS cannot be considered since the latter promotes skin atrophy, which plays a key role in EPDS pathogenesis. Epidermis-preserving strategies, such as systemic retinoids or TCi, are desirable.



**Figure 1: Erosive pustular dermatosis of the scalp treatment flowchart.**

CR: complete response; PR: partial response; R: recurrence/deterioration; SD: stable disease.

## CONCLUSION

According to the authors' results, systemic retinoids appear to be a superior form of maintenance treatment compared with TCI. Study limitations derive from its design, and the small sample size may create confounding and bias. ■

### References

1. Tomasini C, Michelerio A. Erosive pustular dermatosis of the scalp: a neutrophilic folliculitis within the spectrum of neutrophilic dermatoses. *J Am Acad Dermatol*. 2019;81(2):527-33.
2. Wilk M et al. Erosive pustular dermatosis of the scalp: reappraisal of an underrecognized entity. *J Dtsch Dermatol Ges*. 2018;16(1):15-9.
3. Lee KH et al. Treatment of erosive pustular dermatosis: a systematic review of the literature. *Int J Dermatol*. 2020;59(7):770-86.
4. Starace M et al. Erosive pustular dermatosis of the scalp: clinical, trichoscopic, and histopathologic features of 20 cases. *J Am Acad Dermatol*. 2017;76(6):1109-14.
5. Yeh R et al. Erosive pustular dermatosis of the scalp - an Australian perspective: insights to aid clinical practice. *Australas J Dermatol*. 2019;60(4):e272-8.
6. Junejo MH et al. Therapeutic options for erosive pustular dermatosis of the scalp: a systematic review. *Br J Dermatol*. 2021;184(1):25-33.
7. Starace M et al. Erosive pustular dermatosis of the scalp: a multicentre study. *J Eur Acad Dermatology Venereol*. 2020;34(6):1348-54.
8. Corradin MT et al. Erosive pustular dermatosis of the scalp induced by imiquimod. *Case Rep Dermatol Med*. 2012;2012:828749.
9. Piccolo V et al. Erosive pustular dermatosis of the scalp: why do we miss it? *Dermatology*. 2019;235(5):390-5.
10. Starace M et al. Erosive pustular dermatosis of the scalp: challenges and solutions. *Clin Cosmet Investig Dermatol*. 2019;12:691-8.

## Nemolizumab Rapidly Relieves Itch and Sleep Disturbances in Patients with Prurigo Nodularis

**Authors:** \*Sonja Ständer,<sup>1</sup> Gil Yosipovitch,<sup>2</sup> Jean-Philippe Lacour,<sup>3</sup> Franz J. Legat,<sup>4</sup> Carle Paul,<sup>5</sup> Adam Reich,<sup>6</sup> Kamel Chaouche,<sup>7</sup> Faiz Ahmad,<sup>8</sup> Christophe Piketty<sup>7</sup>

1. Department of Dermatology and Center for Chronic Pruritus (KCP), University Hospital Münster, Germany
2. Itch Center, Dr Phillip Frost Department of Dermatology and Cutaneous Surgery, University of Miami Hospital, Miami, Florida, USA
3. Department of Dermatology, University Hospital of Nice, France
4. Department of Dermatology and Venereology, Medical University of Graz, Austria
5. Department of Dermatology, University of Toulouse, France
6. Department of Dermatology, Medical University of Lodz, Poland
7. Galderma R&D, Entre-deux-Villes, Switzerland
8. Galderma R&D, Fort Worth, Texas, USA

\*Correspondence to [sonja.staender@ukmuenster.de](mailto:sonja.staender@ukmuenster.de)

**Disclosure:** Ständer has served as a member of an advisory board and/or received consulting fees from Almirall, Bayer, Beiersdorf, Bellus, Bionorica, Cara Therapeutics, Celgene, Clexio, DS Biopharma, Galderma, Menlo Therapeutics, Novartis, Perrigo, and Trevi Therapeutics; and has served as an investigator for Dermasence, Galderma, Kiniksa, Menlo Therapeutics, Novartis, Sanofi, Trevi Therapeutics, and Vanda Therapeutics. Yosipovitch has served as an advisory board member, investigator, and/or received consulting fees from Galderma, Pfizer, Sanofi Regeneron, Novartis, Eli Lilly, Kiniksa, Vellus, and Celldex. Lacour has received grants/research support as an investigator from AbbVie, BMS, Boehringer-Ingelheim, Celgene, Dermira, Galderma, Janssen, Eli Lilly and Company, Merck, Novartis, Regeneron Pharmaceuticals Inc, and Roche; honoraria, advisory board, or consulting fees from AbbVie, BMS, Celgene, Galderma, Eli Lilly and Company, Novartis, and Sanofi; funding for medical writing from Galderma; and has received consulting fees from Eli Lilly and Sanofi. Legat is/was an investigator for DS Biopharma, Eli Lilly, Galderma, Pfizer, Menlo Therapeutics, Trevi Therapeutics; a consultant for Galderma; and a member of advisory boards and/or has received speaker honoraria/travel fees from AbbVie, Almirall, Celgene, Eli Lilly, Janssen, Leo Pharma, Menlo Therapeutics, Novartis, Pfizer, Trevi Therapeutics, and Vifor Fresenius Medical Care Renal Pharma. Paul has received grants and has been a consultant for Almirall, Amgen, AbbVie, Bristol Myers Squibb, Boehringer, Celgene, Eli Lilly, Janssen,

Leo Pharma, Merck, Mylan, Novartis, Pfizer, Pierre Fabre, Sanofi, and UCB Pharma; and has been an investigator for Eli Lilly, Leo Pharma, Pierre Fabre, Regeneron, and Sanofi. Reich has served as an investigator for AbbVie, Drug Delivery Solutions Ltd, Genentech, Janssen-Cilag, Kymab Ltd, Leo Pharma, Menlo Therapeutics, MetrioPharmAG, Merck Sharp and Dohme, Novartis, Pfizer, and Trevi therapeutics; and has received consulting fees and/or honoraria from AbbVie, Bioderma, Celgene, Chema-Elektronet, Eli Lilly, Galderma, Jansse-Cilag, Leo Pharma, Medac, Menlo Therapeutics, Novartis, Pierre Fabre, Sandoz, and Trevi Therapeutics. Chaouche, Ahmad, and Piketty are employees of Galderma.

**Acknowledgements:** The authors would like to thank the Nemolizumab Study Team and all investigators in Europe who participated in this clinical trial. The study was funded by Galderma.

**Keywords:** IL-31 receptor A inhibitor, nemolizumab, neuroimmune modulator, pruritus.

**Citation:** EMJ Dermatol. 2021;9[1]:63-64. Abstract Review No. AR7.

## BACKGROUND AND AIMS

Patients with prurigo nodularis (PN) have intensely itchy nodular skin lesions resulting in a markedly impaired quality of life and frequent sleep deprivation. Nemolizumab is an IL-31A-receptor inhibitor that modulates the neuroimmune response to IL-31. Phase II trial data showed that nemolizumab significantly improves PN skin lesions and reduces itch compared to placebo with a favorable safety profile. A secondary analysis was conducted to determine the onset of significant reductions in pruritus and sleep disturbance.

## MATERIALS AND METHODS

Nemolizumab was studied in a 12-week Phase II randomised, double-blind, placebo-controlled trial of PN. Patients had moderate-to-severe PN with lesions on upper limbs and  $\geq 20$  nodules on the body and severe pruritus (peak pruritus numerical rating scale [PP-NRS]  $\geq 7$  over the previous week, scale 0–10). Nemolizumab 0.5mg/kg was administered subcutaneously at baseline, Week 4, and Week 8, and safety assessments were performed through to Week 18. In this

secondary analysis, time to onset of significant reduction was assessed for pruritus and sleep disturbance (NRS). Changes in scratching time during sleep (ratio of scratch duration versus sleep duration in minutes per hour) as captured by actigraphy data were also assessed.

## RESULTS

A total of 70 patients were randomised (nemolizumab  $n=34$ ; placebo  $n=36$ ) with a baseline PP-NRS of 8.4 in both groups. The groups were comparable in baseline itch, but there were more patients with severe disease (IGA 4) in the nemolizumab group ( $n=18$  [53%] versus  $n=14$  [39%] in placebo group). Baseline sleep disturbance NRS (SD-NRS) was 7.4 and 6.8 in the nemolizumab and placebo group, respectively.

By Day 2, reduction of itch in patients treated with nemolizumab was significantly greater than in patients receiving placebo (PP-NRS -19.5% versus -5.8%, respectively;  $p=0.014$ ). A significant difference between nemolizumab and placebo in the response criteria for itch (PP-NRS  $\geq 4$ ) was achieved at Day 3 (23.5% versus 0.0%;  $p<0.001$ ). A significant difference in SD-NRS was reported by Day 4 (-19.8% versus -4.3% with placebo;  $p=0.012$ ).

Sleep continued improving through Week 4 (last data capture), when there was a 56.0% reduction in sleep disturbance NRS compared with -22.9% in the placebo group ( $\Delta 33.1$ ;  $p<0.001$ ).

Actigraphy data showed significant differences in scratch/sleep duration for nemolizumab versus placebo, respectively, at Week 1 (-32.15 versus +28.15 min/hour;  $\Delta -60.3$ ;  $p=0.001$ ), Week 2 (-41.23 versus +35.92 min/hour;  $\Delta -77.2$ ;  $p<0.001$ ), and Week 4 (-42.32 versus +0.68 min/hour;  $\Delta -43.0$ ;  $p=0.049$ ).

## CONCLUSION

Nemolizumab has a very rapid onset of action in patients with moderate-to-severe PN demonstrating a significant itch reduction as early as Day 2 and a significant improvement in sleep as early as Day 4. ■

# Chronic Urticaria: Clinical Characteristics, Epidemiology, and Impact on the Quality of Life of Patients

**Authors:** \*Miriam Saad, Kahena Jaber, Faten Rabhi, Mohamed Abderraouf Dhaoui

Dermatology Department, Military Hospital of Tunis, Tunisia

\*Correspondence to [saadmiriam92@gmail.com](mailto:saadmiriam92@gmail.com)

**Disclosure:** The authors have declared no conflicts of interest.

**Keywords:** Angioedema, pruritus, quality of life, urticaria, wheals.

**Citation:** EMJ Dermatol. 2021;9[1]:65-66. Abstract Review No. AR8.

## BACKGROUND AND AIMS

Chronic urticaria (CU) is a common skin condition defined as an urticaria lasting for more than 6 weeks. It is divided into chronic spontaneous urticaria (CSU) and inducible urticaria (IU).<sup>1</sup> The aim of this study was to assess the epidemiological and clinical features of CU, as well as its impact on the quality of life of patients.

## MATERIALS AND METHODS

This was a monocentric, descriptive, retrospective study spanning 28 months from January to April 2021. Patients with different forms of CU, seen in the outpatient Department of Dermatology at the Military Hospital of Tunis, Tunisia, were included regardless of their age and sex.

## RESULTS

Among 60 patients, 63% had CSU and 35% had IU, while the remaining patients (2%) had both CSU and IU. The prevalence of CU was equal in both sexes (male-to-female sex ratio: 1.06). The mean age was 29.7 years (range: 2–82 years), with 55% of cases occurring in patients aged between 21 years and 40 years. Among patients with IU, the

most common types of urticaria were cholinergic urticaria (43%), followed by dermatographism (24%), and cold urticaria (19%). Eighteen (30%) patients had other allergic diseases and 13% had family history of urticaria. An autoimmune disease was found in 7% of patients. All of them had Hashimoto's disease. Generalised eruptions of wheals were more common in patients with CSU (76%), whereas localised eruptions were preponderant in IU (63%). Nine patients (15%) presented an oedema of eyelids or lips. Two patients (3%) have been hospitalised due to urticaria. Second-generation antihistamines were prescribed as a first-line treatment in 59 patients, one individual was prescribed corticosteroids. Wheals completely disappeared in 43% of cases. The treatment reduced the symptoms in 27% of patients, whereas it had no effect in 28% of them. Pruritus was the most bothersome symptom in 90% of patients, causing disruption of daily living and sleep, followed by skin lesions (7%). CU was the cause of sick leave in 20% of patients.

## DISCUSSION AND CONCLUSIONS

Most of the results were consistent with similar studies; however, the sex codominance was rarely reported. In line with the literature, CSU was more frequent in this study than IU (70–82% in the literature).<sup>2</sup> CU is a challenging condition as the treatment is not always successful, especially in CSU. Almost all the patients received second-generation antihistamines as a first-line treatment. The majority of patients in different studies were treated with second-generation antihistamines, with up to 40% of remission reported by Jankowska-Konsuret et al.<sup>2,3</sup> The lack of some drugs, such as omalizumab, in the authors' country did not allow them to compare the effectiveness of the different treatments. In all the previous studies, as in this one, the most bothersome symptom was pruritus, accounting for 16.3% of absenteeism in a study in Poland.<sup>2</sup> ■

## References

1. Zuberbier T et al. The EAACI/GA2LEN/EDF/WAO Guideline for the definition, classification, diagnosis, and management of urticaria: the 2013 revision and update. *Allergy*. 2014;69(7):868-87.
2. Jankowska-Konsur A et al. Clinical characteristics and epidemiology of chronic urticaria: a nationwide, multicentre study on 1091 patients. *Postepy Dermatol Alergol*. 2019;36(2):184-91.

3. Rimoldi M et al. State of the art of chronic spontaneous urticaria in Italy: a multicentre survey to evaluate physicians' and patients' perspectives. *BMJ Open*. 2016;6(10):e012378.

## Blueberry Muffin Baby Secondary to a Ganglioneuroblastoma: A Case Report

**Authors:** Trinidad Montero-Vilchez,<sup>1</sup> Isabel Navarro-Pelayo,<sup>1</sup> Andrea Rodriguez-Tejero,<sup>1</sup> Laura Serrano-lopez,<sup>2</sup> \*Salvador Arias-Santiago,<sup>1</sup> Jesus Tercedor-Sanchez<sup>1</sup>

1. Dermatology Department, Virgen de las Nieves University Hospital, Granada, Spain

2. Paediatrics Department, Virgen de las Nieves University Hospital, Granada, Spain

\*Correspondence to [salvadorarias@hotmail.es](mailto:salvadorarias@hotmail.es)

**Disclosure:** The authors have declared no conflicts of interest.

**Keywords:** Blueberry Muffin Baby (BMB), cutaneous metastases, neuroblastoma.

**Citation:** *EMJ Dermatol*. 2021;9[1]:66-67. Abstract Review No. AR9.

### BACKGROUND

Blueberry muffin baby (BMB) is a rare neonatal syndrome characterised by the presence of multiple purpuric skin nodules.<sup>1</sup> It can be due to dermal erythropoiesis and neoplastic diseases.<sup>2</sup> Ganglioneuroblastoma is a tumour of peripheral neuroblastic tissue that occurs predominantly in the paediatric age group, but it is rare in the newborn period.<sup>3</sup> One of the clinical manifestations of ganglioneuroblastoma is a BMB.<sup>4</sup> Herein, the authors report the case of a newborn presenting with blueberry muffin syndrome that led to the diagnosis of a ganglioneuroblastoma.

### CASE STUDY

A full-term male newborn, following a vaginal delivery, presented, within a few hours of life, with bluish skin nodules all over his body. The birth weight was 3.9 kg and the Apgar scores were 9 at 1 and 5 minutes. Respiratory and cardiovascular functions were normal. The physical examination revealed multiple, randomly distributed bluish cutaneous nodules of 0.5–1.0 cm, predominantly on the abdomen, back, and lower limbs. The differential diagnosis between cause of BMB was made. Laboratory tests only revealed a slight anaemia, without coagulation or platelets disorders. The abdominal ultrasound revealed multiple solid nodules in the fat of the perihepatic, hepatorenal, and splenorenal space compatible with peritoneal lesions. A biopsy specimen of a skin nodule on the leg revealed ganglion cells in a papillaroid pattern, with fibrillary stroma and ganglion cells intermixed with neuroblast. Synaptophysin staining was positive. The least differentiated tumour cells showed salt and pepper blast chromatin nuclei and scant cytoplasm. The urinalysis showed elevated urine catecholamines and metanephrines, and elevated homovanillic acid/creatinine and vanillylmandelic acid/creatinine ratios. The chest CT scan revealed several focal lesions with pleural implantation and pulmonary micronodules. Gammagraphic study with <sup>123</sup>I metaiodobenzylguanidine showed multiple foci of uptake distributed throughout the axial skeleton, and multiple foci of uptake in the liver, lower, and upper limbs, suggestive of metastatic subcutaneous involvement. Considering the clinical manifestations and the additional findings, the newborn was diagnosed with metastatic ganglioneuroblastoma.



## CONCLUSION

In conclusion, the presence of purpuric skin nodules in a newborn can be the only clinical manifestation of a ganglioneuroblastoma.<sup>5</sup> It is important to take a skin biopsy from these lesions. A multidisciplinary approach of the BMB can lead to early diagnosis and effective treatment of these patients. ■

## References

1. Freitag S, Boccara O. What to look out for in a newborn with multiple papulonodular skin lesions at birth. *Dermatopathology (Basel)*. 2021;8(3):390-417.
2. Gauchan E et al. Ganglioneuroblastoma in a newborn with multiple metastases a case report. *J Med Case Rep*. 2017;11(1):239.
3. Mehta V et al. Blueberry muffin baby: a pictorial differential diagnosis. *Dermatol Online J*. 2008;14(2):8.
4. Fortuny LR et al. Blueberry muffin rash, bilateral cataracts, and thrombocytopenia in a neonate. *Clin Chem*. 2021;67(3):472-5.
5. González-Mondragón A et al. [Cutaneous metastasis as the first manifestation of primary adrenal gland neuroblastoma in a pediatric patient.] *Bol Med Hosp Infant Mex*. 2021;78(5):479-84. (In Spanish).

## Features of the Course of Condyloma Acuminata in Women Against the Background of Herpesvirus Infections

**Authors:** \*Delya F. Porsokhonova,<sup>1</sup> Marianna L. Rosstalnaya,<sup>2</sup> Yulduz A. Alimukhamedova,<sup>3</sup> Sevvara N. Rakhmatullaeva<sup>4</sup>

1. Chief of the Sexual Transmitted Infections (STI) and Reproductive Disorders (RD) Department, Republican Specialized Scientific and Practical Medical Center for Dermatovenereology and Cosmetology, Tashkent, Uzbekistan

2. Junior Researcher of the STI and RD Department, Republican Specialized Scientific and Practical Medical Center for Dermatovenereology and Cosmetology, Tashkent, Uzbekistan

3. Senior Researcher of the Department of Serological and PCR diagnostics of STIs, Republican Specialized Scientific and Practical Medical Center for Dermatovenereology and Cosmetology, Tashkent, Uzbekistan

4. Junior Researcher of the STI and RD Department, Republican Specialized Scientific and Practical Medical Center for Dermatovenereology and Cosmetology, Tashkent, Uzbekistan

\*Correspondence to [delya.porsokhonova@mail.ru](mailto:delya.porsokhonova@mail.ru)

**Disclosure:** The authors have declared no conflicts of interest.

**Keywords:** Condyloma acuminata (CA), herpesvirus infections (HVI), human papillomavirus (HPV).

**Citation:** *EMJ Dermatol*. 2021;9[1]:67-68. Abstract Review No. AR10.

## BACKGROUND AND AIM

Despite the widespread prevalence of the human papillomavirus (HPV) and the variety of clinical variants associated with carrying the virus, issues associated with the manifestation of HPV continue to be studied.<sup>1</sup> Detailing the factors contributing to the transition of HPV to a clinically expressed form is the key to successful prevention of relapse.<sup>2,3</sup> The classic variant of the manifest form of HPV is condyloma acuminata (CA), the course of which depends on a number of provoking factors.<sup>4</sup> The aim of the authors work was to assess the background of herpesvirus infections (HVI) in patients with CA of the genitals.

## MATERIALS AND METHODS

The study is based on the results of examination of 101 woman of fertile age (18–44 years), diagnosed with CA. Microbiological diagnostics of infections of the urogenital tract and ELISA diagnostics of blood serum were the methods used to determine specific antibodies of Class M and G to herpes simplex virus (HSV) Types 1

(HSV-1) and 2 (HSV-2) and cytomegalovirus (CMV). PCR diagnostics of scrapings from the cervical and urethral canal were also carried out for the diagnosis of the above pathogens, and HPV 16/18 and 31/33.

## RESULTS

In the ELISA results of blood serum, a multiple increase in relation to the control of the level of specific antibodies of Class G to HSV-1 was detected in 45 (44.6%) patients, HSV-2 in 38 (37.6%), the association of HSV Types 1 and 2 in 17 (16.8%) women, and CMV in 39 (38.6%) examined patients. Most of the studies were confirmed by PCR testing. Furthermore, PCR diagnostics additionally revealed the presence of HVI in another 22 (21.8%) patients. The presence of herpesvirus pathogens was detected in 53 (52.5%) patients, in connection with which the authors analysed possible CA trigger factors in the subgroup of 48 patients both with and without HVI (47.5%). Analysis of the factors contributing to the appearance of CA showed that factors such as taking antibiotics and the presence of concomitant microflora of the urogenital tract were more common in patients with HVI, while taking hormonal drugs, the presence of CA in a partner, the presence of skin foci of HPV of other localisation, anaemia, and malnutrition more often occurred in patients without HVI. With regard to the clinical picture of CA, some differences were also revealed. Thus, in the group of patients with HVI, a large lesion area and large size of rashes were noted, while in the second observation group, the rashes were smaller, located more sparsely, and had a smaller lesion area. With regard to the characteristics

of inflammatory phenomena, the number of relapses and complications (e.g., bleeding) were more severe in the group of patients with concomitant HVI and the presence of HPV Types 16/18. In contrast, in the group of patients with an absence of HPV oncotypes and low titers of specific antiherpetic antibodies, inflammatory phenomena were expressed scarcely. While complications in the form of bleeding were observed in this group, relapses were rare.

## CONCLUSION

Thus, it can be concluded that herpesvirus infection often accompanies clinical forms of HPV, such as CA. The presence of HVI can increase the likelihood of the presence of oncogenic HPV Types 16/18 and 31/33. Taking antibiotics and hormonal drugs, which have an immunosuppressive effect, can contribute to the manifestation of not only herpesvirus but also papillomavirus infection, which together can increase the viral load and cause clinically more pronounced forms of CA. ■

### References

1. Bosch FX et al. Comprehensive control of human papillomavirus infections and related diseases. *Vaccine*. 2013;Suppl 7(Suppl 7):H1-31.
2. McQuillan G et al. Prevalence of herpes simplex virus Type 1 and Type 2 in persons aged 14-49: United States, 2015-2016. *NCHS Data Brief*. 2018;(304):1-8.
3. Olsen AO et al. Herpes simplex virus and human papillomavirus in a population-based case-control study of cervical intraepithelial neoplasia Grade II-III. *APMIS*. 1998;106(3):417-24.
4. Kail-Goryachkina MV, Belousova TA. Features of clinical manifestations and therapy of human papillomavirus-associated diseases of anogenital localization. *Gynecology*. 2019;21(2):49-54.

# Overlapping DRESS and Stevens-Johnson Syndrome: A Case Report

**Authors:** \*Benahmed Jihane,<sup>1</sup> Kerroum Sara,<sup>1</sup> Znati Kawtar,<sup>2</sup> Meziane Mariam,<sup>1</sup> Benzekri Laila,<sup>2</sup> Senouci Karima<sup>2</sup>

1. Dermatology Department, University Mohamed V Rabat, Morocco
2. Pathology Department, University Mohamed V, Rabat, Morocco

\*Correspondence to jihanebenahmed3@gmail.com

**Disclosure:** The authors have declared no conflicts of interest.

**Keywords:** Drug reaction, overlapping, RegiSCAR, Stevens-Johnson syndrome (SJS).

**Citation:** EMJ Dermatol. 2021;9[1]:69-70. Abstract Review No. AR11.

## BACKGROUND

Drug reaction with eosinophilia and systemic symptoms (DRESS), Stevens-Johnson syndrome (SJS), and Lyell's syndrome are severe drug reactions with different clinical, biological, and histopathological characteristics. In order to classify cases of drug-induced severe cutaneous adverse reactions (SCARs), validation scores have been established by the RegiSCAR group. DRESS and SJS can share some features. An overlap is considered when a patient fulfills the criteria (probable or definite case) for at least two SCARs. The authors report the case of an overlapping DRESS/SJS syndrome.

## CASE REPORT

A 66-year-old female patient, with a history of allergy to penicillin, presented with maculopapular rash on the face and the trunk 2 weeks after the introduction of non-steroidal anti-inflammatory drugs (NSAIDs). On physical examination, the patient had fever, facial oedema

with conjunctivitis, and mucosal erosions. There were no lymph nodes. The patient was admitted to the dermatology department and NSAIDs treatment was stopped at this stage. Complete blood count revealed hypereosinophilia up to 2,500/mm<sup>3</sup>. Biochemical tests showed evidence of liver dysfunction. The laboratory routine revealed the presence of renal failure (glomerular filtration rate: 38 mL/min/1.72 m<sup>2</sup>), serum alanine aminotransferase was 210, aspartate aminotransferase was 180. Serum creatinine was 16 mg/ml. During the hospitalisation, skin detachment was observed on the back and trunk (surface: 15%) with a positive Nikolsky sign. A biopsy was performed, revealing a necrotic epidermis with necrotic keratinocytes, and rare eosinophils, compatible with SJS. Within 4 weeks, clinical symptoms and laboratory findings improved.

## DISCUSSION

Only a few cases of overlapping SCARs have been reported.<sup>1,2,4</sup> The RegiSCAR group established validation scores, using clinical, biological, and histological criteria, in order to classify cases as a definite, probable, possible, or excluded diagnosis of acute generalised exanthematous pustulosis, DRESS, or SJS/toxic epidermal necrolysis. In the authors case, DRESS syndrome was suspected because of the onset of the drug use (2 weeks), the presence of peripheral hypereosinophilia, the organ involvement, the rash extent, and the oedema of the face. However, mucosal involvement, skin detachment as well as histopathological findings would be more suggestive of SJS. The causal drug suspected was NSAIDs. This drug was indeed described as involved in a large proportion of cutaneous drug reactions and more specifically in SCARs.

In the retrospective study of Bouvresse et al., which included 216 cases of SCARs, ambiguities between the SCARs were frequent (21%), but only three cases (2.1%) were considered true overlap, based on the RegiSCAR validation scores.<sup>3</sup> A true overlap is considered when the case of

a patient can be classified as 'probable' or 'definite' for two SCARs. When SCAR is suspected, it is important to use strict diagnostic criteria to present a precise diagnosis. This is crucial because of the differences in terms of treatment, follow-up, and short- or long-term prognoses that characterise the different SCARs. ■

## References

1. González-Ramos J et al. Two cases of overlap severe cutaneous adverse reactions to benznidazole treatment for asymptomatic Chagas disease in a nonendemic country. *Br J Dermatol.* 2016;175(3):604-7.
2. Wolf R et al. Drug Rash with eosinophilia and systemic symptoms versus Stevens-Johnson Syndrome—a case that indicates a stumbling block in the current classification. *Int Arch Allergy Immunol.* 2006;141(3):308-10.
3. Bouvresse S et al: Toxic epidermal necrolysis, DRESS, AGEP: do overlap cases exist? *Orphanet J Rare Dis.* 2012;7:72.
4. Peermohamed S, Haber RM. Acute generalized exanthematous pustulosis simulating toxic epidermal necrolysis: a case report and review of the literature. *Arch Dermatol.* 2011;147(6):697-701.

# Congress Interviews

EMJ spoke to two members of the European Academy of Dermatology and Venereology about their roles in the organisation and the advancements in the field of dermatology.

Featuring: Dedee Murrell and Marie-Aleth Richard



## Dedee Murrell

Professor and Head, Department of Dermatology, St George Hospital, University of New South Wales, Sydney, Australia; Chair of Communications Committee, EADV

### Q1 What initially sparked your interest in the field of dermatology and led you to continue researching in this area?

When I was a medical student at the University of Oxford in England, UK, I enjoyed most clinical specialties but then I encountered dermatology and, for some reason, seeing diseases on the skin was something I enjoyed very much, as well as the complexity of it. I had always been drawn to clinical pictures in medical books of unusual syndromes. I am someone who wants to know why, so being able to conduct research was appealing as well as, initially, daunting. Furthermore, there were two very inspiring female academics at Oxford then, Fenella Wojnarowska and Sue Burge, who were great role models for me.

### Q2 Do you think that there are any misconceptions about your specialty?

Yes, for sure. People think of managing skin diseases as 'dermaholiday'. You sometimes find students or young doctors choosing to rotate in dermatology as they believe it will be a doddle. But then they see how many patients we see and have to diagnose quickly and do a lot of explaining to them about the causes and the various treatments and investigations. If there are patients in hospital to manage as well, after the clinics, they are surprised by how tired they are at the end of a day. Until people see some of the severe drug reactions, blistering diseases, hidradenitis, psoriasis, and eczema, they think it is all about beauty therapy.

**Q3** You presented a session at the European Academy of Dermatology and Venereology (EADV) 2021 Congress titled ‘Spectrum of bullous diseases’. Have you seen much improvement in the treatment of these diseases during your career as a dermatologist?

The treatment of psoriasis has changed the most in my time as a dermatologist. The treatment for patients with blistering disease has only changed in so far as patients with pemphigus can access rituximab infusions as an adjunct to lower doses of steroids rather than massive doses of prednisone, and patients can sometimes access intravenous Ig for relapsing disease. Fortunately, clinical trials of new, safer, and more convenient treatments for these bullous diseases are finally underway.

**Q4** You are currently an international EADV Board Member. Could you talk about the ways in which the EADV use their position to impact both clinicians and patients?

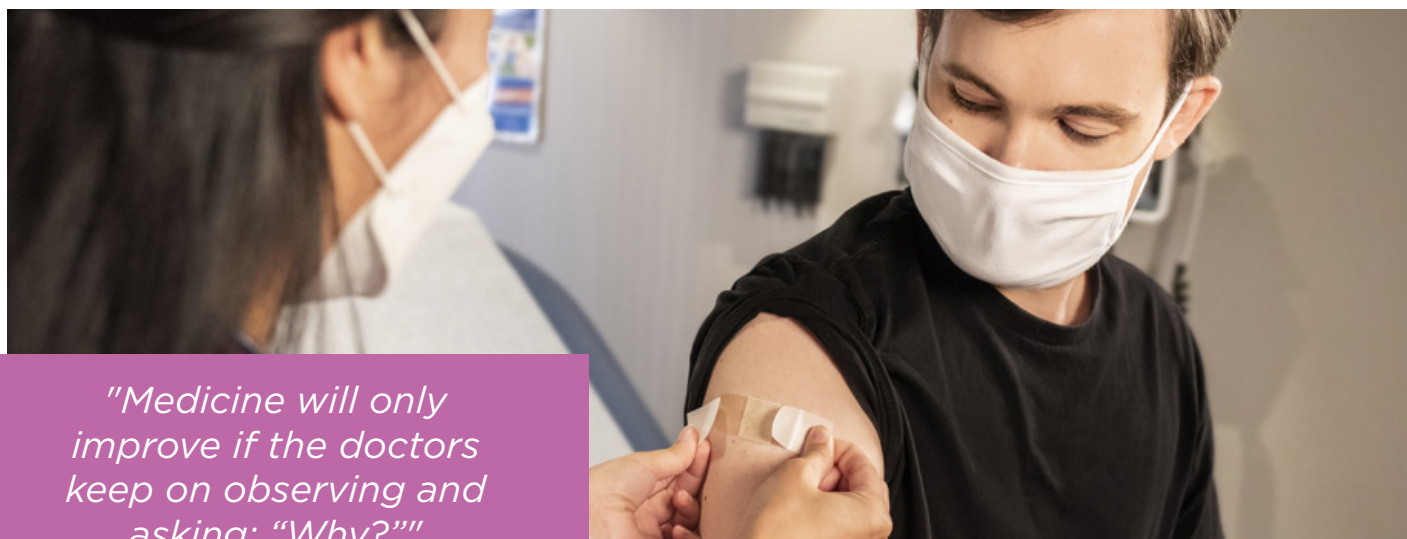I was elected during the EADV board meeting in Paris, 2018, as the first International Board Member and attended my first board meeting in Lugano, Switzerland, the following May. The EADV is very active in advocating for our specialty and our patients at the European Parliament, and with the European Reference Networks (ERNs) and with its EADV Task Forces, which produce and publish the EADV Guidelines such as our EADV Task Force for Autoimmune Blistering Diseases. The recent creation of the

patient village at the EADV Congresses has allowed more cross talk between the support groups and dermatologists and EADV. The late breaking sessions at the EADV are extremely popular for dermatologists to see the latest trial and research results to help our patients.

**Q5** This year’s EADV Congress took a virtual format due to restrictions from the ongoing pandemic. How do you feel COVID-19 has impacted the field of dermatology?

During the pandemic, the EADV was the first major international dermatology congress to run a successful virtual platform and it has changed its in-person education sessions into online lectures. Furthermore, the *Journal of the European Academy of Dermatology and Venereology* is now one of the leading dermatology journals and its free podcasts have a large following.

Patients with inflammatory skin diseases often flare up when they contract COVID-19 or when vaccinated with the COVID-19 vaccines. Hence, skin manifestations in the form of rashes, which were not there before, or exacerbated rashes, are often a sign of contracting COVID-19. Some skin diseases that increase expression of the receptor for the virus’ spike protein (angiotensin-converting enzyme 2) increase susceptibility to COVID-19. In many hospitals, dermatology clinics were closed during the pandemic, and this has meant delays in the diagnosis of cutaneous carcinoma or melanoma. Some dermatologists were, of course, redeployed during the peak of the pandemic to perform other roles in hospitals.



*“Medicine will only improve if the doctors keep on observing and asking: “Why?””*

## **Q6 You are the Co-founder and President of the Australasian Blistering Diseases Foundation (ABDF). What was the mission you set out to achieve when you founded this organisation, and do you feel this has been fulfilled?**

In 2006, I co-founded this charity with my then pre-dermatology research fellow, Linda Martin, who has recently been appointed to an endowed position at my university. The ABDF has grown steadily and provides education for Australian patients with both autoimmune and genetic blistering diseases on how to be diagnosed and on treatments. We have education sessions and provide some research support for smaller projects. We have a website<sup>1</sup> and are on Twitter.<sup>2</sup> The ABDF is also a vehicle through which Australian patients can find out about the new clinical trial opportunities and link to the International Pemphigus & Pemphigoid Foundation (IPPF).<sup>3,4</sup>

## **Q7 Your personal education and professional experience have involved you travelling to numerous destinations, including the UK, New Zealand, and Sri Lanka. Where do you believe you gained the most experience and do you think that travelling was integral for you to make it to where you are today?**

Thank you for this important question. Wherever I have had the opportunity to visit clinics or hospitals in other countries and interact with the dermatologists, it has been very helpful to learn about useful ways of managing patients. The USA was the most influential because I did my formal dermatology residency there, at the University of North Carolina (UNC) at Chapel Hill, USA, where Fenella Wojnarowska had completed her sabbatical with Robert Alan Briggaman. UNC Chapel Hill is an excellent department, with clinician-scientists at the helm, showing you how you can make your own observations and carry out enquiries rather than merely rote learning. Graduates of this programme include Joseph Jorizzo, Steven Feldman, Alan Fleischer, and David Woodley, who have made innovative contributions to dermatology through their own ideas. Medicine will only improve if the doctors keep on observing and asking: "Why?"

I also found it interesting to visit Razi Hospital in Tehran, Iran, a huge hospital run by dermatologists, where there are large sub-specialty clinics and the notes are still written in English, not Farsi. They have published some excellent papers in my area of blistering diseases. Despite the basic facilities in some of the hospitals I taught at in India, Sri Lanka, Malaysia, Vietnam, and the Philippines, as examples, it is the passion of the doctors and nurses that makes the difference to good patient care, not the presence of any fancy new facility.

## **Q8 As an educator, where can we expect to see your focus lie in the coming years?**

The past 18 months has been a quick learning curve for me in terms of becoming proficient in how to deliver online lectures and present at meetings remotely. I expect that for some venues where I cannot attend due to the time factor and cost, that some of these virtual lectures will persist, even though I much prefer delivering talks in person.

I would like to visit more countries where dermatology services and knowledge are lacking to help educate the local clinical staff and see patients with them. The Francophone dermatology meeting, for example, in Tunisia, has already been postponed for 2 years and I am looking forward to presenting again, in French, and visiting facilities in the Maghreb region. I hope to attend all the EADV symposia and congresses in person in the coming years. I haven't been to Ljubljana since flying to Croatia for my honeymoon, so that will be one to put on the calendar for next year.

## **Q9 Are there any innovations on the horizon that you feel are particularly noteworthy in the field of dermatology?**

For western medicine, the information technology revolution in image analysis used for assessing pigmented lesions, using 3D camera systems with digital dermoscopy such as the VECTRA 3D, is a great revolution. The software can compare the whole skin at different time points and provide dermatologists with images of lesions that are new or have changed. This means earlier diagnosis of melanoma.

The other innovation is the discoveries in the labs of increased cytokines or receptors in various skin diseases and the development of biological therapies (monoclonal antibodies or small molecules) to inhibit these. Previously, I was involved in the lab side of this translational medicine. Now, I am involved in designing the clinical studies and conducting them. These treatments are making huge impacts on chronic severe skin diseases and alopecia. ■

#### References

1. Australasian Blistering Diseases Foundation (ABDF). The Australasian Blistering Diseases Foundation. Available at: <https://blisters.org.au/>. Last accessed: 12 October 2021.
2. @blisteringdz. Aus Blist Dz Found'n. Available at: <https://twitter.com/blisteringdz>. Last accessed: 12 October 2021.
3. International Pemphigus & Pemphigoid Foundation (IPPF). International Pemphigus & Pemphigoid Foundation. Available at: <https://www.pemphigus.org/>. Last accessed: 12 October 2021.
4. @healourskin. Healourskin. Available at: <https://twitter.com/healourskin>. Last accessed: 12 October 2021.





## Marie-Aleth Richard

Professor of Dermatology; EADV Board Member; French Member of the Board, Timone Hospitals, Marseille, France

**Q1** You currently hold a position as a Board Member of the European Academy of Dermatology and Venereology (EADV). How much of an impact do you believe the EADV has, both directly on dermatologists and indirectly on patients?

The mission of the EADV is to provide education and training for dermatologists. Now, more energy is being placed on highlighting what dermatologists do and what skin diseases are, which is a good way of helping patients recognise that skin disorders are very important for all of us. Even if they are not life-threatening, most people have had, at least once in their life, a skin condition or skin request for the dermatologist. Advocacy of what the EADV represents across medicine and understanding the needs and expectations of patients are also very important.

**Q2** You previously spoke about the benefits of moving the EADV congress to a virtual format. Should we expect to see future congresses have a virtual format as well as a face-to-face format?

In the future, I believe most international congresses will adopt a hybrid format. Online meetings meant that we could maintain links and share updates even during the COVID-19 pandemic. The virtual element offered a number of advantages. For example, people were able to record sessions and there were no financial barriers to attendance. At the same time, there can be no substitute for face-to-face discussions with colleagues and members of the audience.

**Q3** The theme of the EADV's 30<sup>th</sup> Anniversary Congress 2021 is "celebrating outstanding science." Are there any recent innovations

in the field of dermatology that you think are particularly noteworthy?

I am fascinated by the progress made in inflammatory skin diseases, chronic skin diseases, and in fields that have not been well explored before, such as itch varieties. Advances in paediatric dermatology and dermatology-oncology are also important. We are very lucky as dermatologists because so many breakthroughs occur every month or every year in our speciality.

**Q4** You presented a session on psoriasis at the EADV 2021 Congress. What do you believe are the current gaps in the literature of this disease, and what areas merit greater attention?

We have the drugs and a lot of ways to treat patients. However, I think one of the important things still missing is the unmet needs of patients. We need to discuss more with patients about what they are expecting from us as dermatologists. Secondly, there are still considerable discrepancies between the way we are treating patients from one country to another. The financial support coming from the health system as well as reimbursement varies markedly between countries and should, therefore, be surveyed and discussed. This could help harmonise the care of patients.

**Q5** Psoriasis is a common dermatological disease with no cure. Have you seen much improvement in the development of treatments for its management over the last few years?

The new treatments don't cure but rather control and prevent the disease. The effect of these new drugs can be so long lasting that many



*"We need to discuss more with patients about what they are expecting from us as dermatologists."*

individuals probably feel as if they have been cured. Furthermore, these treatments need only short administration with very long intervals between each administration, and this is something that is very important. The only consideration now is economic.

**Q6** There has been interest from many areas of healthcare towards artificial intelligence. How do you believe the use of artificial intelligence in dermatology would impact patient care?

There are so many ways artificial intelligence could help that it is quite difficult to provide a short answer. In my opinion, managing big data will offer new ways of treating individuals because we can personalise medicine according to the

patients and according to a specific disease. It is also important for skin cancer recognition and for triage of patients.

**Q7** You recently published a paper titled 'Public perception of dermatologists in France'. Do you believe there are any misconceptions about your specialty?

Many people, especially politicians and people from health authorities, view dermatologists as aestheticians, which is not the case. Data from France and across Europe suggests that only 10% of dermatological activity is for aesthetic reasons. In other words, 90% of all our effort is directed toward treating skin disease. We are specialists in the field of skin diseases and this is something that needs to be emphasised. ■

# Interviews

In the following interviews, EMJ spoke to two internationally renowned dermatologists, covering topics such as recent advances in the management of atopic dermatitis, the effects of the COVID-19 pandemic on their field, and the introduction of artificial intelligence into the discipline.

Featuring: Peter Lio and Roxana Daneshjou



## Peter Lio

Clinical Assistant Professor of Dermatology and Pediatrics, Northwestern University Feinberg School of Medicine; Founding Partner, Medical Dermatology Associates (MDA) of Chicago; Founding Director, Chicago Integrative Eczema Center, Chicago, Illinois, USA

**Q1** Following your medical studies at Harvard University, Massachusetts, USA, what led you to specialise and pursue a career in dermatology?

My undergraduate major was in neurobiology, and I honestly thought I would be a neurologist. However, when we had our (very short!) dermatology exposure in medical school, I was captivated. Everyone says that dermatology is very visual, and it is, but it was the language that really made me want to learn more; the descriptors, the precision, the tremendous range of diseases. And then, when I actually did a dermatology rotation, I was over the moon with the incredible therapeutic armamentarium in the field! Topical medications, oral medications, lasers, ultraviolet light, and even cryotherapy. We actually used the cold to treat the skin! It was

intoxicating and unlike any other field I had been exposed to.

**Q2** You are a Clinical Assistant Professor at Northwestern University Feinberg School of Medicine, Illinois, USA. What are some points of emphasis that you incorporate into your teaching?

I have a few areas of focus that I try to emphasise in my teaching:

First, I am a patient advocate. My work with the National Eczema Association has made me very much in tune with the patient experience, and I try very hard to meet the needs of my patients and their families. I try to teach this patient-centric approach whenever I can.

The second is that I am fascinated by integrative approaches in medicine. I'm a bit of an evangelist for this type of thinking, and I try very hard to show that we're not using quackery but are basing what we do on evidence and experience, with the idea that we want and need more research in these areas. It is a little bit of a chicken-and-egg situation: if no one thinks about integrative approaches because there isn't enough research, then it's likely that no one will actually do the required research to move these areas forward! I truly believe that good clinicians need to often think outside of the box, and this is just another way of stating that.

**You are also the founding director of the Chicago Integrative Eczema Center. What was the mission that you set out to achieve when you set up this clinic?**

The main impetus for starting the centre was a paradox: all day long I'd go from room to room and hear the same thing from atopic dermatitis patients: "I feel alone, I have so many questions, I feel unheard." And I realised that if we created a centre where people could come together, we could actually tackle all of these at once! And indeed, that is what we strive to do with education, a support group, and the ability for kids and adults to meet and connect with others like them. Ultimately, I wanted a place that we could have education, clinical excellence, support, and research and I feel very lucky that we've been able to accomplish a great deal.

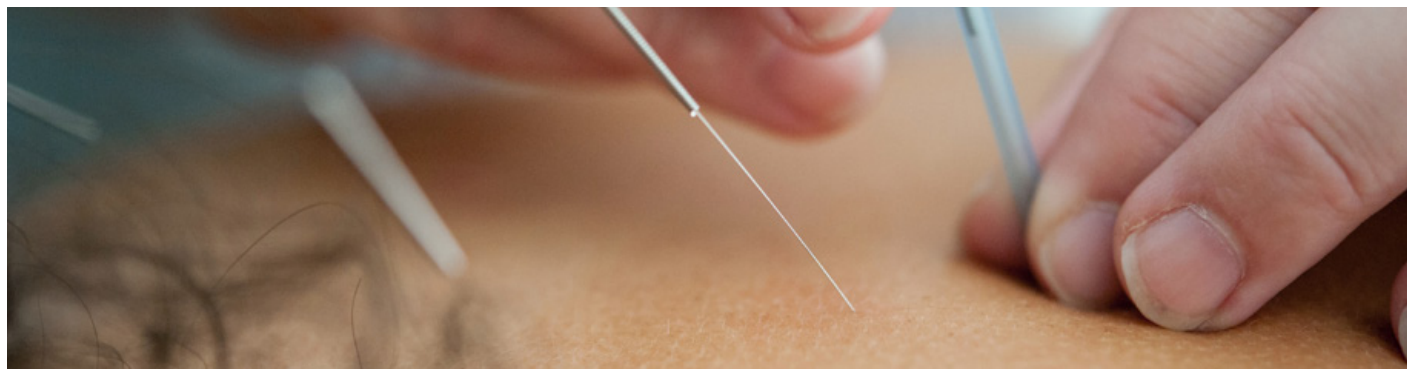*"There have been so many exciting advancements and that is part of why I still am deeply in love with dermatology!"*

**The Chicago Integrative Eczema Center emphasises the importance of education about eczema. Do you think that there are misconceptions about the condition?**

Yes, I think there are many misconceptions and, no doubt, a big part of our work is to help clear these up. Some of the big ones include parents feeling guilty that they did something wrong and that it is their fault. There are heaps of misconceptions around the relationship between food and eczema, no doubt in part because that relationship is extremely complex, and our understanding is rapidly changing. There are many misconceptions around treatments, especially their safety. I am very sober about our therapies: any sword cuts both ways meaning there are always side effects that can occur, but it's really important to understand them, to be on the lookout for their earliest signs and risk factors and get as close to the truth about things as we are able.

**Was there a particular event or person that sparked your interest in alternative medicines?**

I think I have always been interested in the edges or limits of things; that's where a lot of the most interesting things happen! I have, for as long as I can remember, been interested in the paranormal and, when I got to medical school, I couldn't help asking about all of the interesting things outside the cannon of conventional medicine. What about herbs? What about acupuncture? What about therapeutic touch? Do these work? How do they work? Is there any evidence? Typically, these are not covered in medical school, but I quickly found out that there often was some evidence and information about them and that really piqued my interest.



**Q6** You currently have over 150 publications to your name, primarily on the subject of eczema and its treatment. What do you believe are the current gaps in the literature that merit greater attention?

My current areas of interest are thinking about longer term disease modification and control. My goal for patients is to be medication-free, if possible, and I truly think that, for many patients, it can actually happen. I want to better understand how to modify this condition so that we can go from a vicious cycle of flaring to a virtuous cycle of healing. I honestly think, and to some degree have witnessed, that once the skin heals, the microbiome is restored, sleep is improved, and the itch-scratch cycle is broken; some patients really can go into an extended remission. That is when we celebrate!

**Q7** Over the years that you have been practising as a dermatologist, how have you seen the field change in terms of advancements to the treatments used?

There have been so many exciting advancements and that is part of why I still am deeply in love with dermatology! From new lasers, topical medications, and systemic medications to new devices such as the widespread use of dermoscopy, and (finally!) the true rollout of tele dermatology, my practice has continued to change and grow. However, more importantly than these more tangible things, perhaps, is the advancements in understanding: not just disease states and therapies, but better understanding of the patient-doctor relationship, the burden of disease, and a greater awareness of how we can improve.


**Q8** Have you found that the public are generally receptive to new therapies, or do you occasionally experience resistance?

I think that generally people are excited about new therapies, at least conceptually. We now live in a world where the titans of Silicon Valley continue to surprise and delight us with ever-improving gadgets and services that we now

don't know how we could live without. And, to some degree, new treatments can have a similar appeal. However, I will concede that this is not universal and that things like 'me too' drugs (essentially the same or only slightly different than existing therapies), very expensive drugs, and those with many side effects can sort of put a damper on this type of thinking and we have seen pushback against certain therapies that I thought would be embraced and vice-versa.

**Q9** Could you highlight the key findings of your recently published article, titled 'Advances in the Translational Science of Dermatitis'?

I think that perhaps the most important point of the paper is that there is a virtuous cycle of drug development and understanding the pathogenesis of a disease, and that we are finally entering into that cycle with atopic dermatitis after a very long period of drought. The skin barrier, the immune system, the microbiome, and even the nerve endings and mind-body connection: all are starting to yield to scientific inquiry, and we are on the cusp of tremendous advances in atopic dermatitis. ■



*"...we are on the cusp of tremendous advances in atopic dermatitis."*



## Roxana Daneshjou

Clinical Scholar of Dermatology, Stanford University, California, USA

### Q1 Following your medical studies at Stanford University, California, USA, what sparked your interest in the field of dermatology?

I became interested in dermatology after spending time working with dermatologist physician scientists at Stanford. I saw how clinical practice led to new and interesting scientific questions and how scientific breakthroughs led to improvement in clinical practice. As a student, I also saw the kind of lasting relationships that our dermatologists built with their patients, which is something I really value. I feel lucky to have the opportunity to do the same as a practicing dermatologist now.

### Q2 How has the field of dermatology been impacted by the COVID-19 pandemic?

In places where COVID-19 overwhelmed the healthcare system, dermatologists stepped up to help out on the front lines. In outpatient dermatology, we had a sudden increase in telemedicine, since in-person visits were reduced. After vaccinations, in-person visits have

increased, but many patients and physicians also continue to rely on telemedicine. I believe telemedicine will remain an integral part of dermatological practice, and it has the added benefit of increasing access for patients who might not live near a dermatologist.

Clinically, dermatology has encountered and defined new clinical entities during the pandemic, such as the cutaneous manifestations of COVID-19. I have seen these findings in my own practice and am grateful to the leadership of clinician researchers who have helped to describe these findings and their expected course.

### Q3 You have contributed to numerous publications based around the topic of artificial intelligence (AI). How do you believe the use of AI could advance the field of dermatology?

AI and dermatologists working synergistically ('augmented intelligence') has the potential to improve workflows and clinical care. A study by Tschandl et al.<sup>1</sup> found that clinicians paired with AI performed better than either clinicians or AI

*"As a student, I also saw the kind of lasting relationships that our dermatologists built with their patients, which is something I really value."*

alone in classifying benign versus malignant dermoscopic lesions. While this was a narrow task, this study demonstrated how AI might be leveraged in the future, with validated AI applications providing decision support to expert clinicians. Naturally, any decision-support algorithm would have to be thoroughly vetted for unbiased and generalisable behaviour through clinical trials prior to deployment. We could also utilise AI to improve our workflows. For example, we have been developing an algorithm for detecting poor quality telemedicine photos. The algorithm provides real-time patient feedback to reduce the number of blurry or poorly lit photos that get submitted for telemedicine visits.

#### **Q4** Are there any risks associated with the introduction of AI into this discipline?

We must be careful about how we describe algorithm performance in research and in the medicine. For example, many algorithms claiming performance on par or better than a board-certified dermatologist are actually performing a narrow task that does not represent the real-world clinical workflow. Currently, there are no U.S. Food and Drug Association (FDA) approved AI algorithms or algorithms capable of replacing a dermatologist's expertise.

Moreover, we must thoroughly vet algorithms for bias. For example, most published AI algorithms in dermatology have been developed on lighter skin tones, which raises concerns for biased performance across diverse skin tones. We must ensure that AI algorithms are developed in such a way that they alleviate disparities rather than exacerbate them.

#### **Q5** Have you found that the public are generally receptive to new technology, or do you occasionally experience resistance?

I believe the public is generally receptive to technology. In medicine, it is important for us to explain the limitations of any new technology we are using. For example, if I am conducting a telemedicine visit, and I'm not sure about a lesion, I will explain the limitations of making an assessment based on a photo or over video.

There are consumer-facing AI algorithms that claim to detect melanomas; however, research

has shown that these algorithms have a drop in performance in real-world settings. Based on the most current data, I caution patients against using these kinds of consumer-facing applications and to seek a physician if they have a concern about a lesion.

#### **Q6** How have you acquired the leadership skills to carry out your role as Chair of the Paul and Daisy Soros Fellowship for New Americans (PDSFA) Alumni Organisation, New York, USA?

I am grateful to the mentors and role models around me who have demonstrated the qualities of an effective leader. The leaders I admire most are those who empower those around them. During medical school, graduate school, and residency, I personally benefited from mentors who helped me to become the best version of myself by providing guidance and by putting their trust in me. This is the kind of mentor and leader I strive to be as my career unfolds.

With the PDSFA Alumni Organization, I have had the opportunity to work with other amazing New Americans who come from diverse disciplines such as medicine, law, engineering, and art. The Fellowship honours the contributions of immigrants and the children of immigrants by providing financial support for graduate and professional school. The Alumni Organization is a lifelong community that puts academic and social programming together, but also helps to organise efforts around common causes, such as helping immigrant communities.

#### **Q7** You have undertaken roles involved in social media and have published several papers discussing the role of social media in modern medical education. How do you think social media impacts the field of dermatology and healthcare as a whole?

I acknowledge that social media has also been used for spreading misinformation, particularly during the COVID-19 pandemic. But, I also believe social media can be used by physicians to have a positive impact. For example, social media has been used as a tool for finding mentors. I've connected with senior faculty members at other institutions through social media and even written research papers with them.

At the same time, I have met medical students interested in dermatology, who I have worked with and mentored. Not all institutions have a home dermatology programme and social media allows students to connect with dermatology residents and faculties outside of their home institution.

Social media can also be used to disseminate and discuss the latest research. For example, during the pandemic, the #DermTwitter

community regularly discussed the cutaneous findings associated with COVID-19 and the latest publications on the management of these findings.

I know getting started on social media can seem daunting. My colleagues and I wrote a primer for using Twitter, which was published earlier this year.<sup>2</sup> ■

*"I've connected with senior faculty members at other institutions through social media and even written research papers with them."*



#### References

1. Tschandl et al. Human-computer collaboration for skin cancer recognition. *Nat Med.* 2020;26(8):1229-34.
2. Daneshjou R et al. Research techniques made simple: scientific communication using Twitter. *J Invest Dermatol.* 2021;141(7):16150-21.



# Eleven Myths on Nail Melanoma



**Author:** \*Eckart Haneke<sup>1,2,3,4</sup>

1. Private Dermatologist, Dermatology Practice Dermaticum, Freiburg, Germany
2. Consultant Dermatologist, Department of Dermatology, Inselspital, University of Bern, Switzerland
3. Consultant Dermatologist, Centro Dermatol Epidermis, Instituto CUF Porto, Matosinhos, Portugal
4. Consultant Dermatologist, Department of Dermatology, University Hospital Ghent, Belgium

\*Correspondence to haneke@gmx.net

**Disclosure:** The author has declared no conflicts of interest

**Received:** 19.09.21

**Accepted:** 03.11.21

**Keywords:** Controversies, diagnosis, management, nail melanoma, treatment

**Citation:** EMJ Dermatol. 2021;9[1]:83-86. DOI/10.33590/emjdermatol/21-00207.

Melanoma has a somewhat mystical air in dermatology, probably because it was long thought to be the most malignant skin tumour. Since the Scottish surgeon Handley proposed a safety margin of 2 inches corresponding to approximately 5 cm, this has been taken as a dogma for almost a hundred years. However, in the 1950s and 1960s, some surgeons used wider margins because the prognosis of most patients was very poor. This culminated in huge amputations, which alas, did not improve the patients' prognosis. It was believed that any type of manipulation would set off metastases and some dermatology departments used liquid nitrogen to deep freeze the entire melanoma and surrounding tissue with a three-dimensional 5 cm margin.<sup>1</sup> Incisional biopsies were strictly forbidden. This could also not improve the cure rates. It took a new generation of dermatologists and surgeons to recognise that the time of treatment was crucial, not so much the extent of surgery.<sup>2</sup>

Nail melanoma is usually claimed to be a rare type of acral lentiginous melanoma, and this statement is often used as an excuse for the late diagnosis or frequent misdiagnosis. Large patient series of more than 100 patients with nail melanomas showed appallingly poor survival rates; however,

their mean Breslow index was above 4 mm.<sup>3</sup> Taking the slow progression of most nail melanomas into account, this lends strong evidence to a tremendous delay in the diagnosis and finally the therapeutic attempt. This led other authors to claim that nail melanomas, like presumedly other acral melanomas, were particularly malignant. A number of misconceptions prevail in nail melanoma, concerning its frequency and rarity, aggressiveness, diagnostic challenges, necessary tools for diagnosis, patient age, and treatment. This short essay tries to clarify some of these issues.

## NAIL MELANOMA MYTH 1: NAIL MELANOMA IS SO RARE

Most publications on nail melanomas start with the claim that they are very rare and use this as an excuse for their high percentage of late diagnoses and poor prognosis. Ungual melanomas are not rare: 1.0–2.5% of all melanomas in Caucasian patients, according to the German Melanoma Registry 1.8% of cutaneous melanomas (Garbe, personal communication). However, the nail surface is much less than 1% of the body surface. Most unguinal melanomas, particularly

the pigmented ones, develop from the matrix, which is approximately one third of the whole nail region. Clearly, the nail matrix is a hot spot of melanoma development. A rough estimate would suggest that approximately 1-2% of the melanomas in light-skinned people arise in <0.1% of the body surface.

**NAIL MELANOMA MYTH 2: UNGUAL MELANOMA IS A PARTICULARLY AGGRESSIVE FORM OF MELANOMA, HENCE THE PROGNOSIS IS OFTEN SO POOR**

Nail melanomas represent a subdivision of acral melanomas. They all are diagnosed late because most patients and physicians, dermatologists included, do not look at the soles and palms, and even when they see a greyish-brown or even black area they do not think of melanoma. Patients often present with very large areas of palmar or plantar pigmentation known to them for years or even decades, and the reason for the consultation now is that a non-healing wound has developed. Late diagnosis and very late treatment at a high clinical stage, rather than a particularly aggressive type of melanoma, is the reason for the poor prognosis. Subungual location is not an independent poor prognostic factor.<sup>4</sup>

**NAIL MELANOMA MYTH 3: UNGUAL MELANOMA IS PARTICULARLY DIFFICULT TO DIAGNOSE**

Approximately three quarters of nail melanomas are pigmented (i.e., present with a longitudinal melanonychia). This is obvious for the patient and very easy to see in light-skinned individuals. However, even when the patients ask their physician about the brown streak in the nail, this is commonly dismissed as being nothing and the time for early and curative surgery is therefore often missed. Admittedly, the situation is more demanding in dark-skinned persons where nail pigmentation is the rule rather than an exception. Here, any brown band standing out by its colour, width, border, and internal structure (the so-called 'ugly duckling') is suspicious. The key to diagnosis, early treatment, and better survival rates is awareness.<sup>5</sup>

**NAIL MELANOMA MYTH 4: IT IS DIFFICULT TO DETERMINE THE NATURE OF THE PIGMENT CAUSING THE LONGITUDINAL MELANONYCHIA**

Human melanin is granular. Blood, fungal melanin, microbial pigments, and exogenous pigments can easily be ruled out. The granular human melanin is easily seen in a Fontana stain, whereby the free margin of the nail is clipped and stained for the argentaffin reaction. Blood is positive with the pseudocatalase (peroxidase) reaction and stains with patent blue. Fungal melanin is (usually) diffuse and there is often a reverse triangular pattern.<sup>6</sup> Microbial and exogenous pigments can often be scraped off the nail surface.

**NAIL MELANOMA MYTH 5: MELANIN IS DIFFICULT TO DISTINGUISH FROM BLOOD IN THE NAIL AND DERMATOSCOPY IS REQUIRED TO DIFFERENTIATE BLOOD FROM MELANIN**

Human melanin reaches into the free margin of the nail, subungual haematoma does not. Dermatoscopy shows fine greyish or brown lines whereas subungual haematoma, which in fact soon becomes intraungual, forms large globules. It is even possible to distinguish the blood component from the melanin if a patient has both in the same nail.<sup>7</sup>

Blood globules are easily identified and differentiated from the fine lines of a melanin band in the nail, even with the naked eye.

**NAIL MELANOMA MYTH 6: AGE IS NOT IMPORTANT**

Age is an important factor for the diagnosis of nail melanomas. A melanonychia is benign in babies and children; usually benign in adolescents; probably benign in adults <30 years; suspicious in adults >30 years; probably malignant in adults >40 years; and usually malignant in adults >50 years. This means that all recently developed melanonychias in persons over 30 years of age are suspicious and have to be managed as if they were melanomas until

proven that they are not. This does not mean that children cannot develop nail melanoma but they are exceedingly rare. Further, localisation of the melanonychia is important. Thumb and great toe are highly suspicious, index and middle finger are suspicious, and the other fingers and toes are less suspicious, but may also occasionally be the localisation of a nail melanoma. Patients with nail melanoma are generally older than those with benign melanonychia.<sup>8,9</sup>

### **NAIL MELANOMA MYTH 7: DARK-SKINNED INDIVIDUALS HAVE A HIGHER RISK OF DEVELOPING AN UNGUAL MELANOMA.**

Individuals with dark complexion (e.g., people from an African, Asian, native American, or Indian background) have, in absolute numbers, as many nail melanomas as fair-skinned individuals. In people of colour, longitudinal brown striation is the rule rather than an exception (look for the ugly duckling sign). In Black people, the proportion of nail melanomas in relation to all cutaneous melanomas exceeds 20%, in Asian individuals it exceeds even 40%.

### **NAIL MELANOMA MYTH 8: TRAUMA IS AN AETIOLOGICAL AGENT OF UNGUAL MELANOMA**

Although this cannot be ruled out with absolute certainty, the time lag between a (remembered) trauma and the unguual melanoma is usually far too short.

### **NAIL MELANOMA MYTH 9: A DARK MELANONYCHIA STRIATA IS INDICATIVE OF AN UNGUAL MELANOMA**

The colour of unguual melanomas may range from jet-black to brown to virtually non-pigmented.<sup>10</sup> In fact, most melanomas deriving from the matrix are melanotic whereas those originating in the nailbed are amelanotic.

### **NAIL MELANOMA MYTH 10: A MELANONYCHIA STRIATA WIDER THAN 5 MM INDICATES AN UNGUAL MELANOMA**

Any melanonychia striata ranging from 1 mm to >20 mm may be seen in an unguual melanoma, just as in skin a melanoma may be under 2 mm in diameter.

### **NAIL MELANOMA MYTH 11: UNGUAL MELANOMA REQUIRES AMPUTATION AS ITS ADEQUATE TREATMENT**

A comparison of different amputation levels in unguual melanoma did not show any difference in survival, whether it was ray amputation, metacarpal/metatarsal-phalangeal, interphalangeal, or distal phalangeal amputation.<sup>11</sup> Wide local excision was demonstrated to have a better survival rate than amputation as shown in a comparative study. Worldwide, our approach of functional digit-preserving surgery is now accepted.<sup>12</sup> Wide local excision is the treatment of choice for *in situ* and early invasive nail apparatus melanoma.

There are certainly more scientifically unproven issues concerning nail melanoma that are worth being critically studied.

#### **References**

1. Grüneberg T. Presurgical freezing of malignant melanoma from clinical view. *Dermatol Monatsschr.* 1970;156:433-6. (In German).
2. Thurston OG, Couves CM. Treatment of malignant melanoma--a review of 111 cases. *Can Med Assoc J.* 1966;95:843-5.
3. Blessing K et al. Subungual malignant melanoma: clinicopathological features of 100 cases. *Histopathology.* 1991;19:425-9.
4. Mejbøl HA et al. Prognostic significance of subungual anatomic site in acral lentiginous melanoma. *Arch Pathol Lab Med.* 2021;145:943-52.
5. Mole RJ, MacKenzie DN. Subungual

- melanoma. In: StatPearls [Internet]. 2021. Treasure Island (FL): StatPearls Publishing.
6. Ohn J et al. Dermoscopic patterns of fungal melanonychia: a comparative study with other causes of melanonychia. *J Am Acad Dermatol.* 2017;76:488-93.e2.
  7. Nevares-Pomales OW et al. Pigmented lesions of the nail unit. *Am J Dermatopathol.* 2018;40:793-804.
  8. Lee HY et al. Melanoma: differences between Asian and Caucasian patients. *Ann Acad Med Singap.* 2012;41:17-20.
  9. Yim SH et al. Predictor of subungual melanoma against benign longitudinal melanonychia: a retrospective cohort study from Korea. *Ann Dermatol.* 2021;33:147-53.
  10. Löser C, Maysen PA. Dark nail: clinical findings, diagnostics and therapy of melanonychia. *Hautarzt.* 2014;65:327-36. (In German).
  11. Park KG et al. Surgical aspects of subungual malignant melanomas. The Scottish Melanoma Group. *Ann Surg.* 1992;216:692-5.
  12. Haneke E, Binder D. Subungual melanoma with streaky nail pigmentation. *Hautarzt.* 1978;29:389-391.

FOR REPRINT QUERIES PLEASE CONTACT: [INFO@EMJREVIEWS.COM](mailto:INFO@EMJREVIEWS.COM)

# Botulinum Toxins in Medical and Cosmetic Dermatology

EDITOR'S  
PICK

Botulinum toxin is an extremely versatile injectable medication that can be used for cosmetic and medical treatment of numerous dermatologic conditions. In the Editor's Pick article for this issue, the authors conducted a comprehensive and up-to-date systemic review of the PubMed database using Preferred Reporting Items for Systematic Reviews and Meta-Analyses (PRISMA) guidelines in order to describe the multitude of on- and off-label applications of botulinum toxin in dermatology. This paper is a valuable addition to the literature and will be a stimulus for the EMJ readership.

**Authors:** \*Margit Juhász,<sup>1</sup> Anna-Marie Hosking,<sup>1</sup> Natasha Atanaskova Mesinkovska<sup>1,2</sup>

1. University of California, Irvine, Department of Dermatology, Irvine, California, USA  
2. University of California, Irvine, Beckman Laser Institute, Irvine, California, USA  
\*Correspondence to [mjuhasz@hs.uci.edu](mailto:mjuhasz@hs.uci.edu)

**Disclosure:** The authors have declared no conflicts of interest.

**Received:** 06.08.20

**Accepted:** 22.01.21

**Keywords:** Botulinum toxin (BoNT), hyperhidrosis, Raynaud's phenomenon, rhytides, scarring.

**Citation:** EMJ Dermatol. 2021; DOI/10.33590/emjdermatol/20-00202

## Abstract

**Background:** Botulinum toxin (BoNT), a bacterially produced neurotoxin, is a mainstay in the dermatologic armamentarium. Although BoNT is commonly used to treat rhytides associated with ageing, it can be employed for a variety of other cosmetic purposes and medical disorders.

**Objective:** In this review, the authors aim to describe the multitude of uses for BoNT in the dermatologic field.

**Materials and Methods:** This manuscript was designed as a retrospective review of the on- and off-label applications of BoNT in dermatology.

**Results:** In addition to treatment of rhytides, BoNT has been shown to decrease rosacea, menopause-associated flushing, and facial sebum production, while improving patient confidence in their appearance. Furthermore, BoNT has been successfully used to treat primary hyperhidrosis, hair loss, aberrant scarring, Raynaud's phenomenon-associated vasospasm, as well as a variety of skin diseases. Side effects of BoNT include pain or discomfort associated with injections during treatment, bruising, asymmetry, and swelling. Patients are generally satisfied with clinical results after BoNT treatment.

**Conclusion:** Dermatologists should be aware of all on- and off-label applications of BoNT to provide patients with timely and appropriate medical care. Further research must be completed to fully characterise the safety and use of BoNT for off-label purposes.

## INTRODUCTION

Botulinum neurotoxins (BoNTs) are derived from *Clostridium botulinum*, a gram-positive anaerobe. While there are seven subtypes of BoNT (A to G), only A and B are currently clinically relevant. The cosmetic potential of BoNT-A was first described in the early 1990s by Drs Jean and Alistair Carruthers as a safe and effective treatment for dynamic rhytides.<sup>1</sup> Ten years later, BoNT-A was approved by the U.S. Food and Drug Administration (FDA) for the treatment of glabellar rhytides. Since their commercial availability, BoNTs have been used on- and off-label in both the medical and cosmetic realms for spasticity, migraines, depression, hyperhidrosis, as well as ageing of the face, neck, and décolletage. BoNT is secreted by *C. botulinum* as a three-protein complex with the 150 kDa toxin, a non-toxin haemagglutinin protein, and a

non-toxin, non-haemagglutinin protein. Bacterial proteases cleave the toxin into an active, di-chain product consisting of the 100 kDa 'heavy' and 50 kDa 'light' chains. Once the active toxin is introduced to the presynaptic nerve terminal, the heavy chain binds synaptic vesicle glycoprotein 2 causing endocytosis of the toxin-glycoprotein complex and toxin light chain release into the synaptic space. Toxin light chains cleave either synaptosomal-associated protein 25 (BoNT-A, C, E), or vesicle-associated membrane protein/synaptobrevin (BoNT-B, D, F, G), disallowing the release of acetylcholine from the axon of peripheral motor nerves, and causing subsequent temporary chemical denervation and muscle paralysis.<sup>2</sup>

There are four commercially available, FDA-approved BoNT-A preparations in the USA: onabotulinumtoxinA (ONA; Botox®, Allergan Inc., Irvine, California, USA); abobotulinumtoxinA

**Table 1: Characteristics of commercially available botulinum toxins in the USA.**

Commercially available toxin	FDA approval	Serotype	Molecular target	Molecular weight (kDa); units per vial	Unit equivalents of ONA
OnabotulinumtoxinA (ONA; Botox®)	Medical: axillary hyperhidrosis, blepharospasm, migraine, strabismus.  Cosmetic: glabellar lines, periorcular rhytides	A	SNAP25	900; 100	1
AbobotulinumtoxinA (ABO; Dysport®)	Medical: blepharospasm, cervical dystonia.  Cosmetic: glabellar lines.	A	SNAP25	300-500; 500	3
IncobotulinumtoxinA (INCO; Xeomin®)	Medical: blepharospasm, cervical dystonia.  Cosmetic: glabellar lines.	A	SNAP25	150; 100	1
PrabotulinumtoxinA-xvfs (PRA; Jeuveau™)	Cosmetic: glabellar lines.	A	SNAP25	900; 100	1
Rimabotulinumtoxin (RIMA; Myobloc®)	Medical: cervical dystonia.	B	VAMP	700; 5,000	N/A

N/A: not applicable; ONA: onabotulinumtoxinA; SNAP25: synaptosomal-associated protein 25; VAMP: vesicle-associated membrane protein.

(ABO; Dysport®, Medicis Pharmaceuticals Corp., Scottsdale, Arizona, USA); incobotulinumtoxinA (INCO; Xeomin®, Merz Aesthetics, Frankfurt, Germany); and, newest to the market, prabotulinumtoxinA-xvfs (PRA; Jeuveau™, Evolus, Newport Beach, California, USA); as well as one BoNT-B: rimabotulinumtoxinB (RIMA; Myobloc®, Solstic Pharmaceuticals, San Francisco, California, USA). While ONA, ABO, and INCO are approved for use in the medical and cosmetic settings, PRA is only approved for glabellar lines and RIMA is only approved for the treatment of cervical dystonia (Table 1). For the purposes of this present review, it is important to note that all treatments discussed will refer to units (U) of BoNT-A as ONA equivalents, unless otherwise stated.

## SAFETY

The human medial lethal dose of BoNT-A is estimated at 1.3–2.1 mg/kg (intramuscularly or intravenously), correlating to a median lethal dose (LD50) of 26–42 units/kg;<sup>3</sup> thus, at the doses used for cosmetic and medical treatment, BoNT is considered safe. Though contraindications to BoNT injection are few, they exist, and include allergy to constituents of BoNT because of the potential for anaphylaxis; neuromuscular disorders such as myasthenia gravis, Lambert-Eaton syndrome, and amyotrophic lateral sclerosis; and pregnancy and nursing. Although medications such as cyclosporine, D-penicillamine, and aminoglycosides are not contraindicated, a thorough medication history is warranted as these drugs may cause neuromuscular junction abnormalities and possibly potentiate the effects of BoNT.<sup>4</sup>

The most common side effects of BoNT administration are pain or sensitivity in the area injected, bruising, swelling, and asymmetry. During injection, it is important that injectors are aware of surrounding musculature as diffusion of BoNT may affect areas that were not intended for treatment. In the literature, the majority of reported adverse events occur after cosmetic treatment of the head and neck for rhytides. Headaches can occur in up to 11.4% of BoNT-A-treated patients, considered to be more likely a result of trauma secondary to injection rather than the BoNT itself, as 20% of placebo patients also report headache. Headaches can

arise up to 2 days post-injection and persist for 2–4 weeks.<sup>5</sup> When injecting into the platysma, clinicians should assess patients for dysphagia as this is a rare but serious complication, especially when using high doses of BoNT-A.<sup>6</sup> Generalised reactions to BoNT have been reported in clinical trials, including flu-like symptoms, malaise, nausea, and distant cutaneous reactions such as dermatitis; however, these adverse events are uncommon and self-resolve.<sup>7</sup>

Although immunogenicity to the 150 kDa toxin of BoNT-A was originally reported, it is rare in patients treated after 1997. New formulations of BoNT-A contain only 20% of the original protein and are hypothesised to decrease the likelihood for patient immune reaction. However, cases of immunogenicity even to newer BoNT-A formulations are occasionally reported; for instance, a patient developed neutralising antibodies after treatment of masseter hypertrophy using Vistabel® (Allergan Inc., Irvine, California, USA) and Azzalure® (Galderma S.A., Paris, France). Risks for increased immunogenicity include large BoNT-A doses, frequent injection, and short intertreatment duration (<3 months).<sup>7</sup>

## MATERIALS AND METHODS

A systematic review of the PubMed database using Preferred Reporting Items for Systematic Reviews and Meta-Analyses (PRISMA) guidelines was completed in December 2020 using the search term “botulinum toxin AND (flushing OR erythema OR rosacea OR menopause OR oily OR sebum OR rhytides OR wrinkles OR lines OR mood OR hyperhidrosis OR alopecia OR bullous OR Hailey-Hailey OR pemphigus OR linear IgA OR epidermolysis bullosa OR scar OR keloid OR Raynaud OR hidradenitis suppurativa OR psoriasis),” which resulted in a total of 2,951 total articles. Inclusion criteria were manuscripts written in English pertaining to the use of botulinum toxin in dermatologic conditions in the past 10 years; review papers, commentaries, editorials, practice guidelines, animal studies, and articles not written in English were excluded from review.

## RESULTS

After inclusion and exclusion criteria were applied, 404 studies were reviewed, with 208 discussing cosmetic uses of botulinum toxin such as rhytides or facial rejuvenation (n=185), flushing (n=13), depression or psychologic effects after rhytide treatment (n=7), and oily skin (n=3); while 196 discussed medical uses including hyperhidrosis (n=100), abnormal scarring (n=32), Raynaud's phenomenon (n=25), bullous disease (n=10), alopecia (n=5), as well as other disease processes (n=24).

### Cosmetic Uses

#### Flushing

Flushing or erythema of the scalp, face, neck, and chest can be caused by a variety of underlying neurogenic conditions such as rosacea or symptomatic menopause. Although the use of BoNT has mixed results for the treatment of flushing, multiple studies demonstrate that the injection of 10–500 U of BoNT-A over affected areas in a 1 cm grid-like pattern results in decreased symptomatology (such as 'hot flashes' or perspiration) and improved patient quality of life as measured by the Dermatology Quality of Life Index (DLQI) over 6 months.<sup>8,9</sup>

#### Oily skin

BoNT-A has been trialled for the treatment of excess sebum production of the forehead and 'T-zone'. Although it is not known how BoNT affects sebaceous glands, it is possible that the toxin targets local muscarinic receptors and arrector pili muscles, thus regulating sebum production. Preliminary retrospective data show that patients treated with BoNT report decreased sebum production and pore size. A more recent prospective study injected 30–45 U of ABO to the foreheads of 25 subjects, with 91% of patients reporting a decrease in sebum production and a reduction in pore size after assessment of photographs.<sup>10</sup>

#### Rhytides

Overactive musculature, photodamage, and ageing cause the formation of dynamic and static rhytides (i.e., 'wrinkles') that patients perceive as making their appearance fatigued or angry; treatment of facial rhytides can lead to a

more relaxed and rested appearance. Although currently the FDA has only approved BoNT for treatment of glabellar (corrugator supercilii, depressor supercilii, and procerus muscles) and periorbital lines ('crow's feet'; orbicularis oculi muscle), off-label use of BoNT occurs for the treatment of horizontal forehead lines (frontalis muscle), ptotic brow (lateral orbicularis oculi), horizontal nasal lines ('bunny lines'; nasalis muscle), 'gummy smile' (levator labii superioris alaeque nasi muscle), perioral lines (orbicularis oris muscle), dimpled chin (mentalis muscle), 'downturned smile' (depressor anguli oris), masseter hypertrophy (masseter muscle), mandibular border ('Nefertiti lift'; superior platysmal band), and platysmal bands of the neck (platysma muscle), with clinical results lasting approximately 3 months (Figure 1).<sup>6,11</sup>

#### Combination therapy

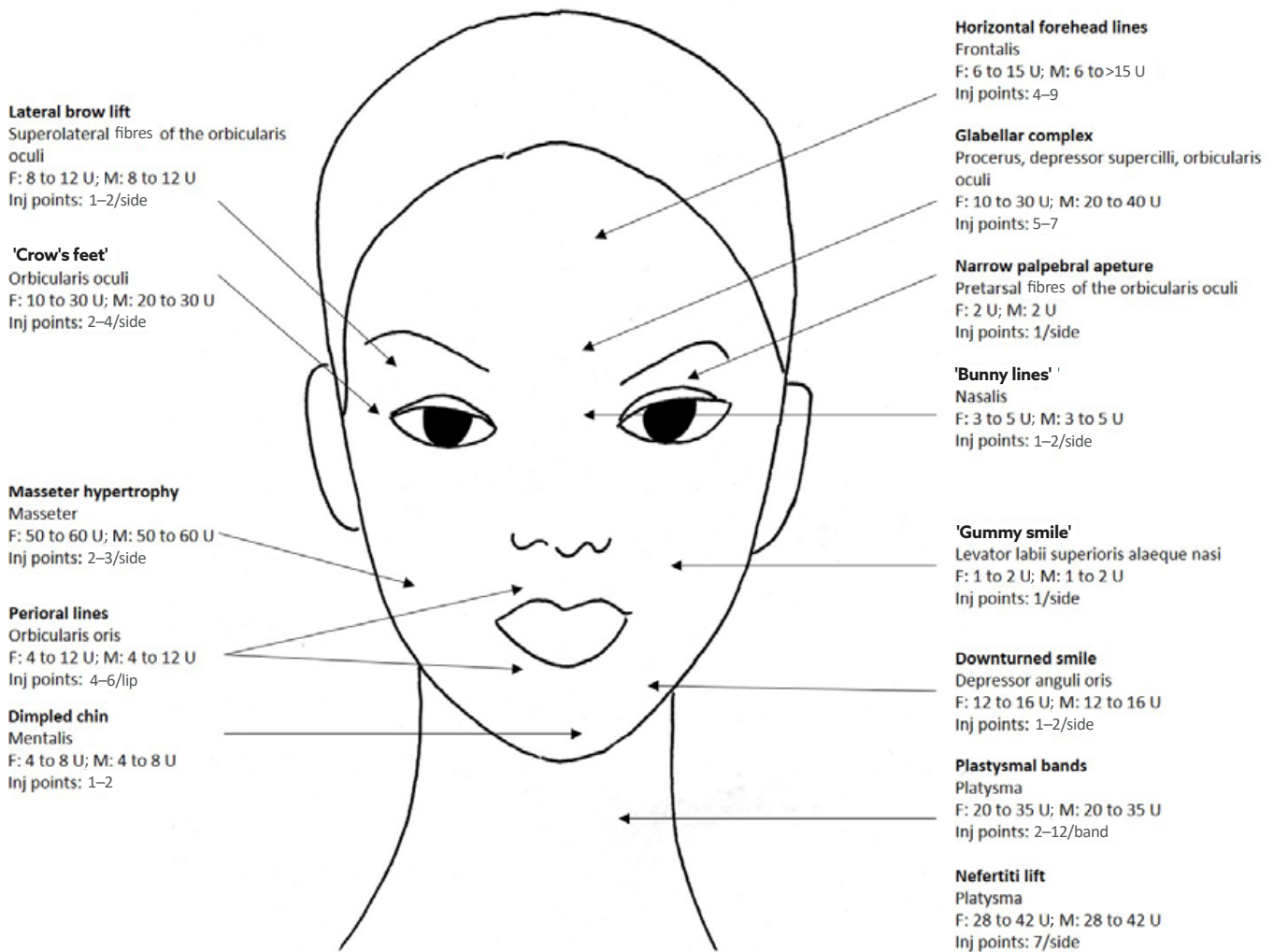
Combining BoNT with filler injection for simultaneous treatment of dynamic rhytides and volume loss is popular in the outpatient setting. Hyaluronic acid and calcium hydroxyapatite fillers in combination with BoNT have been used successfully in multiple areas of the face, including the glabella, periorbital or perioral areas, nasolabial folds, as well as the jaw and chin. Filler should be placed before BoNT to avoid migration of toxin that may occur when injected filler is massaged. It has even been suggested that the combination of filler and BoNT can increase the duration of filler clinical efficacy in the glabellar area to almost double because of decreased facial movement.<sup>5</sup>

BoNT should be avoided on the same day as laser treatment because of concerns for toxin diffusion. Although no studies have shown BoNT diffusion after microfocused/high-intensity focused ultrasound or radiofrequency microneedling treatment, it is reasonable to assume that diffusion may occur after such modalities and the same caution should be considered.

#### Psychological improvement

In conjunction with rhytide reduction, BoNT improves patient mood and perceived confidence. Improvements in the FACE-Q (satisfaction with facial appearance, satisfaction





**Figure 1: Target areas for BoNT-A treatment of the face.**

BoNT-A treatment of rhytides of the upper, mid, and lower face, with suggested total ONA units for female and male patients, as well as number of injection points.<sup>32</sup>

BoNT: botulinum toxin; F: female; inj: injection; M: male; ONA: onabotulinumtoxinA.

**Table 2: Protocols for the treatment of primary hyperhidrosis using BoNT with suggested total ONA units, as well as number of injection points.<sup>19</sup>**

Anatomic location of primary hyperhidrosis	Injection protocol
Axillae	50–100 U/axilla Inject every 1–2 cm (approximately 15 injection sites)
Palms	75–100 U/palm Inject every 1 cm, 2–3 injection points per digit (approximately 35–50 injection sites)
Soles	100–200 U/sole Inject every 1 cm, 2–3 injection points per digit (approximately 35–50 injection sites)

BoNT: botulinum toxin; ONA: onabotulinumtoxinA.

with facial skin, and appraisal of facial lines) score after treatment of moderate-to-severe glabellar lines have been reported. Even after 120 days, when clinical effects of BoNT should be waning, patients have reported increased psychological well-being and improved facial appearance.

Given the impact of BoNT impact on mood lasting beyond its effect on musculature, clinicians should discuss with patients at which point retreatment is necessary to achieve maximal psychological and clinical response, rather than automatically reinjecting BoNT every 3 months.<sup>12,13</sup> In addition, BoNTs have been used in neurology for the successful treatment and prevention of migraines, with a notable increase in patient well-being and quality of life.<sup>14</sup>

## Medical Uses

Within the purview of dermatologic practice, the only FDA-approved medical use of BoNT is ONA for the treatment of axillary hyperhidrosis. Despite further lack of approval, BoNT has been used off-label for the treatment of alopecia, bullous skin disorders, palmar and plantar hyperhidrosis, hypertrophic and keloidal scarring, as well as other dermatologic medical conditions such as Raynaud's phenomenon, hidradenitis suppurativa, and psoriasis.

## Hyperhidrosis

BoNT disrupts acetylcholine-induced secretion from eccrine sweat glands, which are located in the axillae, as well as throughout the body. ONA is approved by the FDA for the treatment of primary axillary hyperhidrosis. The use of BoNT for treatment of primary hyperhidrosis has extended to use in the palms and soles, as well as other areas of the body. Adolescent patients as young as 12 years old have been treated successfully with BoNT, with some researchers advocating for early treatment of hyperhidrosis to decrease future patient morbidity such as decreased quality of life.<sup>15</sup>

Treatment of the primary axillary hyperhidrosis can be accomplished using 50–100 U of BoNT-A per axilla with intradermal injections spaced every 1–2 cm in a grid-like pattern (for approximately 15 injection sites). Clinical results are noticeable after 1 week and last for 3–10 months. Patients are generally satisfied with treatment. It is important to inform patients

that compensatory sweating can occur in up to 5% of cases post-injection.<sup>4,16,17</sup> Treatment of palmar and plantar hyperhidrosis can also be accomplished with BoNT. Injections should be spaced 1 cm apart in a grid-like pattern with 2–3 injection points per digit (for approximately 35–50 injection sites). Each hand can receive 75–100 U of BoNT-A, while each foot can receive 100–200 U. Clinical results take up to 1 week for effect and last 3–6 months. Specific adverse events associated with palmar and plantar injection of BoNT should be discussed with patients prior to treatment. After palmar injection, patients can experience weakness, especially in pinch strength, while plantar injections may impede walking, especially if a nerve block is performed prior to BoNT treatment.<sup>18,19</sup> Unfortunately, 20% of patients injected with BoNT for plantar hyperhidrosis will not respond to treatment (Table 2).<sup>19</sup>

Due to the painful nature of injections into the palms and soles, discomfort during BoNT injections has been mitigated in a variety of ways. Studies have demonstrated that topical lidocaine/prilocaine, vibration, cryoanalgesia, repeated needle replacement, use of microneedles, intravenous administration of anaesthesia and peripheral nerve blocks, iontophoretic administration of 2% lidocaine, needle-free units to administer local anaesthesia using pressure, and inhaled nitrous oxide are all viable methods of analgesia during injection.<sup>17,19–25</sup> Advances in BoNT delivery may also decrease injection-associated pain. Needle-free jet injection devices have been trialled for the treatment of palmar hyperhidrosis (Med-Jet BMX, Medical International Technologies, Montréal, Canada); however, clinical efficacy was decreased as compared to traditional injections.<sup>26</sup> An *in vivo* murine study demonstrated that BoNT-A-coated polylactic acid microneedles are a safe and effective delivery method, resulting in significantly decreased sweating.<sup>27</sup> Delivery of BoNT-A using a combined fractional ablative laser and ultrasound has been trialled successfully to treat palmar hyperhidrosis.<sup>28</sup> A topical formulation of BoNT-A in a liposomal base applied nightly for 7 nights was found to be effective at reducing axillary sweat for up to 8 weeks, compared to vehicle alone, suggesting that painless delivery methods for BoNT are on the horizon.<sup>29</sup>

Recent studies have employed BoNT to treat hyperhidrosis in novel locations. For example, one case report injected 100 U of BoNT-A every 6–8 months at the gluteal cleft of a male patient with pressure-induced ulceration to decrease sweat production and associated wound maceration; over a period of 2 years, skin integrity was maintained with no clinical worsening of the pressure injury.<sup>30</sup> Another study employed a total of 2250 U of BoNT-B (Neurobloc, Eisai Europe, Hatfield, UK) injected every 15 mm across the forehead, frontal scalp, parietal scalp, and occipital scalp in a band-like pattern, as well as periocular and perioral, for the treatment of postmenopausal craniofacial hyperhidrosis. Three weeks after treatment, patients treated with BoNT-B reported a 91% improvement in the DLQI, compared with an 18% decrease in quality of life with placebo injections.<sup>31</sup> In addition, BoNT injection has been shown to be clinically effective for the therapy of Frey's syndrome and sialorrhoea; however given the anatomic location of injections, treatment is often performed by otolaryngology.<sup>32,33</sup>

In addition to hyperhidrosis, BoNT-A has been used successfully to treat chromhidrosis (coloured sweat of the axillae and cheek) and bromhidrosis (malodorous sweat of the axillae and genitals). Treatment protocols generally follow the same recommendations as for axillary hyperhidrosis, with patients receiving approximately 100 U, divided across the affected area(s), per treatment session. Clinical results last from 3 to 9 months.<sup>34,35</sup> Furthermore, small studies demonstrate improvement in hand and dyshidrotic eczema (pompholyx) in patients with palmar hyperhidrosis after injection of 100 U of BoNT-A.<sup>36</sup>

## Alopecia

BoNT-A has been used for the treatment of androgenetic alopecia, cephalalgic alopecia, alopecia areata, and radiation-induced alopecia. Although it is unknown how BoNT contributes to hair regrowth, it is hypothesised that decreasing microvascular pressure through muscle relaxation may increase oxygen delivery to the hair follicles. Treatment protocols range from 30 to 150 U injected into the frontal, temporal, periauricular, and occipital musculature over 1–12 sessions. Most studies

report clinical improvement in hair growth or density and high levels of patient satisfaction; however, further randomised controlled trials are necessary to determine the true effect of BoNT on hair growth.<sup>37–39</sup> On the contrary, multiple BoNT injections for forehead wrinkles have been associated with the development of frontal alopecia.<sup>40</sup>

## Bullous skin disease

BoNT has been trialled off-label for the treatment of several bullous skin disorders including Hailey-Hailey disease (familial benign pemphigus), linear IgA bullous dermatosis, and localised epidermolysis bullosa simplex (Weber-Cockayne). Hailey-Hailey disease has been treated with BoNT-A injections, as well as a combination of BoNT-A and erbium: yttrium aluminum garnet ablative laser or oral tacrolimus, in the axillae, inframammary, groin and intergluteal cleft regions. Doses range from 25 to 200 U every 3 to 6 months with clinical improvement lasting at least 12 months after treatment.<sup>41,42</sup> Case reports have reported the treatment of the bilateral axillae in a young patient with linear IgA bullous dermatosis using 50 U per axilla, and 100 U injected into the foot of a middle-aged female affected by localised epidermolysis bullosa simplex.<sup>43,44</sup>

## Raynaud's phenomenon

Raynaud's phenomenon, vasospasm of the digits, is difficult to treat and is often recalcitrant to first-line therapies such as calcium channel blockers, nitrates, phosphodiesterase inhibitors, iloprost, and bosentan. Surgical procedures such as sympathectomy are invasive and require recovery and downtime. BoNT injection has been used successfully for the treatment of primary and sclerosis-associated Raynaud's phenomenon of the fingers.<sup>45,46</sup> After injection of 50–100 U of BoNT-A in 19 patients with Raynaud's phenomenon, investigators noted that 13 patients reported immediate improvement in pain and chronic ulcerations healed within 60 days.<sup>47</sup> When compared to normal saline injections, digital pulp temperature significantly improved in the fingertips treated with BoNT after 6 weeks, suggesting BoNT is effective at treating Raynaud's phenomenon-associated vasospasm.<sup>48</sup> Currently, there are no standardised injection protocols used

for treatment; one study demonstrated that injection at the wrist, digits, or distal metacarpus does not result in significantly different clinical outcomes, although all were effective at treating Raynaud's phenomenon-associated vasospasm.<sup>49</sup>

## Scarring

BoNT has been used to decrease hypertrophic and keloidal scarring resulting from increased wound edge tension; by paralyzing the surrounding musculature, tensile forces and abnormal scar formation may be decreased. It has also been suggested that BoNT may decrease TGF- $\beta$  signalling, a regulator of hypertrophic scarring.<sup>50</sup> Studies demonstrated the use of 15–140 U of BoNT-A administered up to 9 days post-procedure, every 4–12 weeks for 1–3 treatment sessions resulted in scar softening, reduced elevation, and decreased symptoms such as itching and pain.<sup>51</sup> However, one study using a three-dimensional optical system to image keloidal scars, showed no keloidal tissue regression after treatment with BoNT.<sup>52</sup> When compared to intralesional triamcinolone 10 mg/cc every 4 weeks for 6 injection sessions, 5 U/cm<sup>3</sup> of BoNT-A every 8 weeks for 3 sessions was found to significantly improve subjective complaints such as itch, pain, and allodynia, possibly due to the clinical effects of BoNT-A on small-fibre neuropathy; however, only intralesional triamcinolone resulted in significant improvement in keloid scar softening.<sup>53</sup>

Combination therapy using BoNT-A has also been used for the treatment of hypertrophic or keloidal scarring. Clinical improvement of a traumatic scar of the chin was achieved with injection of 6–8 U of BoNT-A in combination with 4 treatments of 595 nm pulsed dye laser every 2 weeks.<sup>54</sup> A combination of INCO and microneedling of facial scars after non-melanoma skin cancer surgery results in significantly improved cosmetic results and patient satisfaction with appearance post-surgery.<sup>55</sup>

## Other medical diseases

Case reports have reported use of 40–250 U of BoNT-A per site (axilla, inguinal folds) with 1–3 treatment sessions for hidradenitis suppurativa, with complete remission of

disease lasting 6 months to 3 years. Like bullous diseases, it is thought that decreased sweat production contributes to hidradenitis suppurativa improvement by eliminating an environment in which bacteria may flourish, and preventing rupture of the follicular unit.<sup>56,57</sup> BoNT-A has also been trialed as an adjuvant for the treatment of aquagenic keratoderma,<sup>58</sup> congenital eccrine naevus,<sup>53</sup> Darier Disease (keratosis follicularis),<sup>59</sup> inverse and plaque psoriasis,<sup>60</sup> notalgia paraesthetica,<sup>61</sup> pachyonychia congenita,<sup>62</sup> and post-herpetic neuralgia resulting from herpes zoster.<sup>63</sup>

## THE FUTURE

Multiple new formulations of BoNT-A are currently being trialed for the treatment of glabellar and periocular lines. DaxibotulinumtoxinA (DAXI; Revance Therapeutics Inc., Newark, New Jersey, USA) has been studied as both a topical and injectable therapy; but, the topical preparation was not efficacious. Injectable DAXI has entered Phase III FDA trials, with efficacy treating glabellar lines and clinical results possibly lasting 5 weeks longer than ONA (SAKURA 1 and 2, BELMONT).<sup>64</sup> LetibotulinumtoxinA (LETI; Botulax<sup>®</sup>, Hugel, Chuncheon, South Korea) is currently commercially available in Asia and is undergoing studies in anticipation of FDA approval for treatment of periorbital rhytides.<sup>65</sup> When compared to INCO, LETI has a greater amount of neurotoxin protein per volume, but also has increased amounts of inactive neurotoxin, which hypothetically may increase the risk of immunoreaction.<sup>66</sup>

Liquid formulations of BoNT-A are being studied to reduce current concerns for reconstitution contamination or error. NivobotulinumtoxinA (NIVO; Innotox<sup>®</sup>, Medytox, Inc., Seoul, South Korea, and MT10109L, Allergan, Inc., Irvine, California, USA) is non-inferior to ONA for the treatment of frown lines, and is undergoing studies to determine clinical efficacy for glabellar lines.<sup>67,68</sup> QM-1114 (Galderma Laboratories, L.P., Lausanne, Switzerland) is superior for the treatment of glabellar lines compared to placebo, and is currently being studied for the reduction of lateral canthal lines.<sup>69-71</sup>

In addition to new formulations of BoNT-A, liquid BoNT-E (ED-001, Bonti, Inc., Newport Beach, California, USA) is being pursued due to its purported faster onset of action (24 hours post-injection) and decreased duration of clinical results (14–30 days). EB-001 has been shown to safely and effectively decrease appearance of glabellar lines and may improve forehead scar cosmesis post-Mohs micrographic surgery (SHINE).<sup>72,73</sup> It is possible that in addition to the current cosmetic indications being pursued by pharmaceutical companies, dermatologists will be able to use these new BoNT-A formulations for the off-label treatment of dermatologic medical disease as outlined above.

## CONCLUSION

BoNT is an extremely versatile injectable medication that can be used for cosmetic, as

well as medical, treatment of dermatologic diseases such as hyperhidrosis, hair loss, aberrant scarring, bullous skin disorders, psoriasis, and Raynaud's phenomenon, amongst others. Although the use of BoNT use is relatively safe, it is always important to be aware of injection points as the toxin may diffuse and negatively affect adjacent areas that should not have been treated. Clinicians should be acutely aware of site-specific adverse events, especially with injection of BoNT into the neck, hands, or feet. Dermatologists need to be educated on both the on- and off-label uses of BoNT to provide patients with appropriate treatment and decrease associated morbidity. Well-developed clinical trials are required to determine the true clinical efficacy of BoNT in the off-label setting, as well as possible long-term safety concerns.

## References

- Carruthers JD, Carruthers JA. Treatment of glabellar frown lines with C. botulinum-A exotoxin. *J Dermatol Surg Oncol.* 1992;18:17-21.
- Huang W et al. Pharmacology of botulinum toxin. *J Am Acad Dermatol.* 2000;43:249-59.
- Scott AB, Suzuki D. Systemic toxicity of botulinum toxin by intramuscular injection in the monkey. *Mov Disord.* 1988;3:333-5.
- Coté TR et al. Botulinum toxin type A injections: adverse events reported to the US Food and Drug Administration in therapeutic and cosmetic cases. *J Am Acad Dermatol.* 2005;53:407-15.
- Carruthers J, Carruthers A. A prospective, randomized, parallel group study analyzing the effect of BTX-A (Botox) and nonanimal sourced hyaluronic acid (NASHA, Restylane) in combination compared with NASHA (Restylane) alone in severe glabellar rhytides in adult female subjects: treatment of severe glabellar rhytides with a hyaluronic acid derivative compared with the derivative and BTX-A. *Dermatol Surg.* 2003;29:802-9.
- Carruthers J, Carruthers A. Practical cosmetic botox techniques. *J Cutan Med Surg.* 1999;3(4):S49-52.
- Naumann M et al. Meta-analysis of neutralizing antibody conversion with onabotulinumtoxinA (BOTOX®) across multiple indications. *J Mov Disord.* 2010;25: 2211-8 .
- Odo MEY et al. Botulinum toxin for the treatment of menopausal hot flushes: a pilot study. *Dermatol Surg.* 2011;37:1579-83.
- Park KY et al. Botulinum toxin for the treatment of refractory erythema and flushing of rosacea. *Dermatology.* 2015;230:299-301.
- Rose AE, Goldberg DJ. Safety and efficacy of intradermal injection of botulinum toxin for the treatment of oily skin. *Dermatol Surg.* 2013;39:443-8.
- Jensen J et al, "Botulinum toxins," Draelos ZD (eds.), *Cosmetic dermatology: products and procedures* (2015) 2nd edition, Chichester: John Wiley & Sons, Ltd, pp.364-74.
- Chang BL et al. Patient perceived benefit in facial aesthetic procedures: FACE-Q as a tool to study botulinum toxin injection outcomes. *Aesthet Surg J.* 2016;36:810-20.
- Cohen J et al. Assessment of psychological well-being after abobotulinumtoxinA treatment: a comparison of 2 reconstitution volumes. *Dermatol Surg.* 2020;46:289-92.
- Burstein R et al. Mechanism of action of onabotulinumtoxinA in chronic migraine: a narrative review. *Headache.* 2020;60(7):1259-72.
- Bernhard M et al. Sweaty feet in adolescents-early use of botulinum type A toxin in juvenile plantar hyperhidrosis. *Pediatr Dermatol.* 2018;35:784-6 .
- Doft M et al. Treatment of axillary hyperhidrosis with botulinum toxin: a single surgeon's experience with 53 consecutive patients. *Aesthetic Plast Surg.* 2011;35:1079-86.
- Carruthers JD, Carruthers JA, "Focal axillary hyperhidrosis," Glaser D, Mattox AR (eds.), *Botulinum toxin: procedures in cosmetic dermatology* (2018) 4th edition, Toronto: Elsevier Inc, pp.177-85.
- Klein AW. Contraindications and complications with the use of botulinum toxin. *Clin Dermatol.* 2004;22:66-75.
- Carruthers JD, Carruthers JA, "Palmoplantar hyperhidrosis," Mariwalla K, Solish N (eds.), *Botulinum toxin: procedures in cosmetic dermatology* (2018) 4th edition, Toronto: Elsevier Inc, pp.187-92.
- Benohanian A. Needle-free anaesthesia prior to botulinum toxin type A injection treatment of palmar and plantar hyperhidrosis. *Br J Dermatol.* 2007;156:593-6.
- Richards RN. Ethyl chloride spray for sensory relief for botulinum toxin injections of the hands and feet. *J Cutan Med Surg.* 2009;13:253-6.

22. Torrisi BM et al. Pocketed microneedles for rapid delivery of a liquid-state botulinum toxin A formulation into human skin. *J Control Release*. 2013;165:146-52.
23. Blaheta H et al. Intravenous regional anesthesia (Bier's block) is superior to a peripheral nerve block for painless treatment of plantar hyperhidrosis with botulinum toxin. *J Am Acad Dermatol*. 2003;48:302-4.
24. Campanati A et al. Local neural block at the wrist for treatment of palmar hyperhidrosis with botulinum toxin: technical improvements. *J Am Acad Dermatol*. 2004;51:345-8.
25. Reed ML. Surgical pearl: mechanoanesthesia to reduce the pain of local injections. *J Am Acad Dermatol*. 2001;44:671-2.
26. Vadeboncoeur S et al. Treatment of palmar hyperhidrosis with needle injection versus low-pressure needle-free jet injection of onabotulinumtoxinA: an open-label prospective study. *Dermatol Surg*. 2017;43:264-9.
27. Shim DH et al. Development of botulinum toxin A-coated microneedles for treating palmar hyperhidrosis. *Mol Pharm*. 2019;16:4913-9.
28. Issa M et al. Early investigations in drug delivery of onabotulinum toxin A using combined fractional ablative laser with impact ultrasound vs. injections of onabotulinum toxin A for palmar hyperhidrosis: a right-left comparison trial. *Br J Dermatol*. 2018;179:1168-9.
29. Lueangarun S et al. Topical botulinum toxin type A liposomal cream for primary axillary hyperhidrosis: a double-blind, randomized, split-site, vehicle-controlled study. *Dermatol Surg*. 2018;44:1094-101.
30. Uhlig-Reche et al. Treatment of secondary hyperhidrosis of the intergluteal cleft with botulinum toxin. *PM R*. 2020;DOI:10.1002/pmrj.12404.
31. Cabreus P et al. Postmenopausal craniofacial hyperhidrosis treated with botulinum toxin type B. *J Dermatol*. 2019;46(10):874-8.
32. Freni F et al. Use of botulinum toxin in Frey's syndrome. *Clin Case Rep*. 2019;7:482-5.
33. Weitzman RE et al. A 10-year retrospective review of botulinum toxin injections and surgical management of sialorrhea. *Cureus*. 2020;12:e7916.
34. Beer K, Oakley H. Axillary chromhidrosis: report of a case, review of the literature and treatment considerations. *J Cosmet Dermatol*. 2010;9:318-20.
35. Wu CJ et al. Efficacy and safety of botulinum toxin a in axillary bromhidrosis and associated histological changes in sweat glands: a prospective randomized double-blind side-by-side comparison clinical study. *Dermatol Surg*. 2019;45:1605-9.
36. Swartling C et al. Treatment of dyshidrotic hand dermatitis with intradermal botulinum toxin. *J Am Acad Dermatol*. 2002;47:667-71.
37. Cho HR . Treatment effects of intradermal botulinum toxin type A injection on alopecia areata. *Dermatol Surg*. 2010;36(Suppl 4):2175-81.
38. Hyun M et al. Radiation-induced alopecia treated with botulinum toxin type A injection. *Plast Reconstr Surg Glob Open*. 2014;2:e226.
39. Shon U et al. The effect of intradermal botulinum toxin on androgenetic alopecia and its possible mechanism. *J Am Acad Dermatol*. 2020;83(6):1838-9.
40. Di Pietro A, Piraccini BM. Frontal alopecia after repeated botulinum toxin type A injections for forehead wrinkles: an underestimated entity? *Skin Appendage Disord*. 2016;2:67-9.
41. Bedi M, Taylor AL. Recalcitrant Hailey-Hailey disease responds to oral tacrolimus and botulinum toxin type A. *Cutis*. 2015;96:e14-16.
42. Ho D, Jagdeo J. Successful botulinum toxin (onabotulinumtoxinA) treatment of Hailey-Hailey disease. *J Drugs Dermatol*. 2015;14:68-70.
43. Abitbol RJ, Zhou LH. Treatment of epidermolysis bullosa simplex, Weber-Cockayne type, with botulinum toxin type A. *Arch Dermatol*. 2009;145:13-5.
44. Legendre L et al. Botulinum toxin A: an effective treatment for linear immunoglobulin A bullous dermatosis located in the axillae. *Acta Derm Venereol*. 2016;96:122-3.
45. Herrick AL. The pathogenesis, diagnosis and treatment of Raynaud phenomenon. *Nat Rev Rheumatol*. 2012;8:469-79.
46. Smith L et al. Botulinum toxin-A for the treatment of Raynaud syndrome. *Arch Dermatol*. 2012;148:426-8.
47. Neumeister MW et al. Botox therapy for ischemic digits. *Plast Reconstr Surg*. 2009;124:191-201.
48. Jenkins SN et al. A pilot study evaluating the efficacy of botulinum toxin A in the treatment of Raynaud phenomenon. *J Am Acad Dermatol*. 2013;69:834-5.
49. Fregene et al. Botulinum toxin type A: a treatment option for digital ischemia in patients with Raynaud's phenomenon. *J Hand Surg*. 2009;34:446-52.
50. Elhefnawy AM. Assessment of intralesional injection of botulinum toxin type A injection for hypertrophic scars. *Indian J Dermatol Venereol Leprol*. 2016;82:279-83.
51. Xiao Z et al. Treatment of hypertrophic scars with intralesional botulinum toxin type A injections: a preliminary report. *Aesthetic Plast Surg*. 2009;33:409-12.
52. Gauglitz GG et al. Botulinum toxin A for the treatment of keloids. *Skin Pharmacol Physiol*. 2012;25:313-8.
53. Shaarawy E et al. Intralesional botulinum toxin type A equally effective and better tolerated than intralesional steroid in the treatment of keloids: a randomized controlled trial. *J Cosmet Dermatol*. 2015;14:161-6.
54. Lee SJ et al. Combined treatment with botulinum toxin and 595-nm pulsed dye laser for traumatic scarring. *Ann Dermatol*. 2015;27:756-8.
55. Casabona GR, Giacomo TB. Improving the appearance of surgical facial scars with incobotulinumtoxinA and microneedling. *J Drugs Dermatol*. 2020;19:611-5.
56. Khoo ABS, Burova EP. Hidradenitis suppurativa treated with Clostridium botulinum toxin A. *Clin Exp Dermatol*. 2014;39:749-50.
57. Martina E et al. Botulinum toxin in dermatology A review- hidradenitis suppurativa: how to treat with BoNT-A. *Skin Appendage Disord*. 2017;3(1):39-56.
58. Bagazgoitia L et al. Letter: aquagenic keratoderma: successful treatment with botulinum toxin. *Dermatol Surg*. 2010;36:434-6.
59. Santiago-et-Sánchez-Mateos JL et al. Botulinum toxin type A for the preventive treatment of intertrigo in a patient with Darier's disease and inguinal hyperhidrosis. *Dermatol Surg*. 2008;34:1733-7.
60. Gilbert E, Ward NL. Efficacy of botulinum neurotoxin type A for treating recalcitrant plaque psoriasis. *J Drugs Dermatol*. 2014;13:1407-8.
61. Maari C et al. Treatment of notalgia paresthetica with botulinum toxin A: a double-blind randomized controlled trial. *J Am Acad Dermatol*. 2014;70:1139-41.
62. González-Ramos J et al. Efficacy of botulinum toxin in pachyonychia congenita type 1: report of two new cases. *Dermatol Ther*. 2016;29:32-6.
63. Apalla Z et al. Botulinum toxin A in postherpetic neuralgia: a parallel, randomized, double-blind, single-dose, placebo-controlled trial. *Clin J Pain*. 2013;29:857-64.
64. Bertucci V et al. DaxibotulinumtoxinA for Injection has a prolonged duration of response in the treatment of glabellar lines: pooled data from two multicenter, randomized, double-blind, placebo-controlled, phase 3 studies (SAKURA 1 and SAKURA 2). *J Am Acad Dermatol*. 2020;82:838-45.

65. Hugel, Inc. Evaluate the Safety and Efficacy of Botulax® as Compared to Botox® in Subject With Moderate to Severe Crow's Feet Lines. NCT03408236. <https://clinicaltrials.gov/ct2/show/NCT03408236>.
66. Frevert J et al. Comparison of botulinum neurotoxin type A formulations in Asia. *Clin Cosmet Investig Dermatol*. 2018;11:327-31.
67. Allergan, Inc. MT10109L in the Treatment of Glabellar Lines. NCT03795922. <https://clinicaltrials.gov/ct2/show/NCT03795922>.
68. Kim J E et al. The efficacy and safety of liquid-type botulinum toxin type A for the management of moderate to severe glabellar frown lines. *Plast Reconstr Surg*. 2015;135:732-41.
69. Q-Med AB. Long-term Treatment of Moderate to Severe Glabellar Lines and Lateral Canthal Lines (READY-4). NCT04225260. <https://clinicaltrials.gov/ct2/show/NCT04225260>.
70. Q-Med AB. Treatment of Moderate to Severe Lateral Canthal Lines (READY-2). NCT04249687. <https://clinicaltrials.gov/ct2/show/NCT04249687>.
71. Monheit G et al. Evaluation of QM-1114, a novel ready-to-use liquid botulinum toxin, in aesthetic treatment of glabellar lines. 2019. Available at: <https://www.wcd2019milan-dl.org/abstract-book/documents/late-breaking-abstracts/03-aesthetic-cosmetic-dermatology/evaluation-of-qm1114-a-novel-490.pdf>. Last accessed: April 2021.
72. Yoelin SG et al. Safety and efficacy of EB-001, a novel type E botulinum toxin, in subjects with glabellar frown lines: results of a phase 2, randomized, placebo-controlled, ascending-dose study. *Plast Reconstr Surg*. 2018;142:847e-55e.
73. Rodrigues O; Bonti. Bonti Announces Successful Completion of Phase 2a Scar Reduction Clinical Study. 2018. Available at: <https://www.biospace.com/article/releases/bonti-announces-successful-completion-of-phase-2a-scar-reduction-clinical-study/>. Last accessed : April 2021.

FOR REPRINT QUERIES PLEASE CONTACT: [INFO@EMJREVIEWS.COM](mailto:INFO@EMJREVIEWS.COM)

# Mosaicism in Tuberous Sclerosis Complex: A Case Report, Literature Review, and Original Data from Danish Hospitals

**Authors:** \*Julie Loft Nagel,<sup>1</sup> Maja Patricia Smerdel,<sup>2</sup> Lisbeth Birk Møller,<sup>3</sup> Lotte Andreasen,<sup>4</sup> Anette Bygum<sup>5</sup>

1. Faculty of Health Sciences, University of Southern Denmark, Odense, Denmark

2. Department of Clinical Genetics, Hospital of Lillebaelt – University Hospital of Southern Denmark, Vejle, Denmark

3. Applied Human Molecular Genetics, Kennedy Center, Department of Clinical Genetics, Copenhagen University Hospital, Glostrup, Denmark

4. Department of Clinical Genetics, Aarhus University Hospital, Skejby, Denmark

5. Department of Clinical Genetics, Odense University Hospital, Denmark & Clinical Institute, University of Southern Denmark, Odense, Denmark

\*Correspondence to [junag16@student.sdu.dk](mailto:junag16@student.sdu.dk)

**Acknowledgements:** The authors would like to thank Amalie Pauline Bjerregaard Clausen for drawing Figure 1 for their article.

**Received:** 17.04.21

**Accepted:** 01.07.21

**Keywords:** Genodermatoses, mosaicism, tuberous sclerosis complex (TSC).

**Citation:** EMJ Dermatol. 2021;9[1]:98-105.

## Abstract

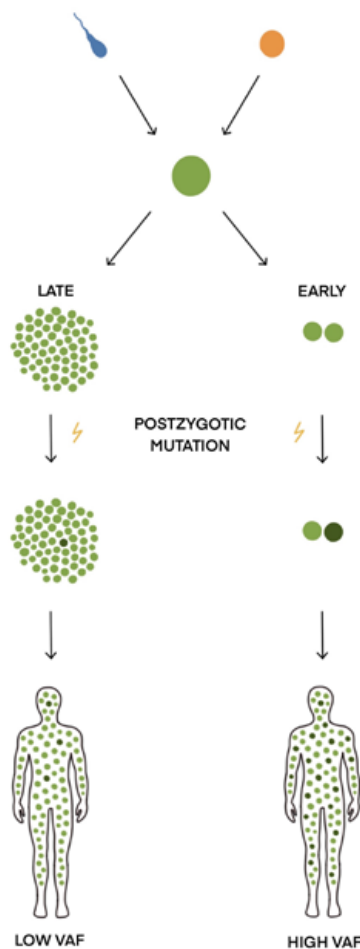
Tuberous sclerosis complex (TSC) is an autosomal dominant hereditary disease with hamartomatous growths in multiple organs due to loss-of-function variants in *TSC1* or *TSC2*. In approximately 15% of patients with clinical TSC, no pathogenic variant can be identified, and low-level mosaicism is suggested to be one of the reasons. Mosaicism is well-known in TSC and challenges the molecular genetic diagnosis. The advent of next-generation sequencing has improved the diagnostics in TSC including in patients with mosaicism. The TSC phenotype varies widely, and mosaic patients with TSC are often considered to have a milder phenotype. Here, the authors describe a patient with mosaic TSC with a 10% variant allele fraction and manifestations in three organ systems (skin, eyes, and kidneys). Furthermore, the authors studied existing literature about phenotypic organ manifestations in patients with mosaic TSC. No clear definition of the phenotype of patients with mosaic TSC could be established, but unilateral angiofibromas and the absence of tubers and a subependymal nodule could indicate mosaicism. The case shows that patients with low-level mosaic TSC can have multiple affected organ systems though still a mild clinical picture.



## INTRODUCTION

Tuberous sclerosis complex (TSC) is an autosomal dominant hereditary disease characterised by a variable phenotype and growth of hamartomas in multiple organs.<sup>1-6</sup> Affected organs include skin, brain, eyes, heart, kidneys, and lungs, and the diagnosis is often established in childhood, where most patients develop seizures.<sup>7</sup> The disease is caused by the pathogenic loss-of-function variants in the tumour suppressor genes *TSC1* and *TSC2*.<sup>5,6,8,9</sup> In patients with clinical TSC, pathogenic variants of *TSC1* and *TSC2* can be identified in a blood sample in 75–90% of cases.<sup>3</sup> One-third of patients have an inherited form, while the other two-thirds result from a *de novo* variant.<sup>1,2,10</sup>

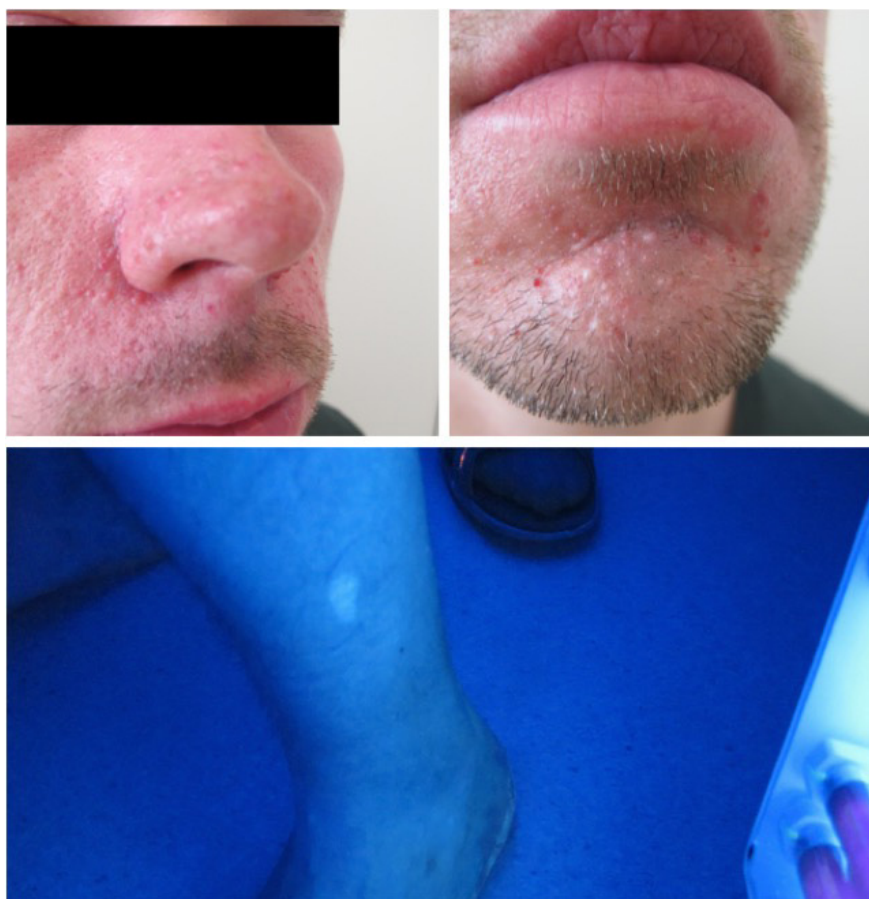Mosaicism in TSC arises from post-zygotic mutations in *TSC1* and *TSC2*, whereby the cells in an individual harbour different genotypes (Figure 1).<sup>2,4,5,11</sup> It can be generalised mosaicism manifesting in several cell types and organs or mosaicism limited to a single cell line.<sup>11,12</sup> Mosaicism challenges the molecular genetic diagnosis of TSC.<sup>2</sup> In approximately 15% of patients with clinical TSC, no pathogenic variant can be identified in the blood (no mutation identified [NMI]).<sup>1-3,13</sup> Mosaicism with a low variant allele fraction (VAF; mosaic variant reads/total reads) is one of the reasons and is suggested to constitute approximately 50% of NMI cases.<sup>1,3,12-14</sup>



**Figure 1: How mosaicism arises during embryogenesis.**

Mosaicism is the presence of two or more cell populations with different genotypes. It arises from a single zygote. If the post-zygotic mutation happens early during embryogenesis, the VAF (mosaic variant reads/total reads) will be high; if the mutation occurs late, VAF will be low.

VAF: variant allele fraction.



**Figure 2: Patient with mosaic tuberous sclerosis complex, symmetric facial angiofibromas, and hypomelanotic macula illustrated in Woods light.**

Here, the authors present their most recent case of mosaic TSC in a 32-year-old male, who was diagnosed with low-level mosaicism and several affected organs. They provide a review of published literature regarding mosaicism in TSC to elucidate the phenotype in patients with mosaic TSC. Furthermore, original data from Danish hospitals are presented.

## CASE REPORT

A 32-year-old male was referred to the Department of Clinical Genetics to confirm a clinical diagnosis of TSC. At the age of 11 years, he had an angiofibroma removed from his chin. Since then, several skin lesions had emerged around his nose and chin. He was the only child of seemingly healthy parents and there were no other cases of TSC known in the family. He had no history of seizures. A diagnostic work-up with an MRI scan of the cerebrum was unremarkable.

An MRI scan of the abdomen showed multiple small cysts in both kidneys as well as two larger angiomyolipomas, which were confirmed by a CT scan and an ultrasound-guided biopsy. A dermatological evaluation revealed numerous angiofibromas in the central part of the face and three hypomelanotic macules on the left forearm, left lower part of the back, and on his left leg (Figure 2). An ophthalmologist could not rule out or confirm TSC when examining the eyes. A molecular genetic analysis using standardised next-generation sequencing (NGS) with the HaloPlex Target Enrichment System (Agilent, California, USA) and data filtering, in which all variants observed with an allele frequency of 10% or less were removed, showed no pathogenic variant in the *TSC1* or *TSC2* gene. At this point, a mosaic form of TSC was suspected. A revised, more sensitive version of the molecular genetic analysis of *TSC1* and *TSC2* (HaloPlex™ HS Target Enrichment System; Agilent) and data filtering, in which only variants observed with an allele

frequency of 1% or less were removed, showed a pathogenic splice variant in the *TSC2* gene (c.4663-1G>A) in a mosaic form (10%). A new evaluation by the Department of Ophthalmology showed a suspected astrocytoma in the right eye.

## METHODS

At the Department of Clinical Genetics, Copenhagen University Hospital, Rigshospitalet, Denmark, the coding regions of *TSC1* and *TSC2* were sequenced by NGS using a MiSeq benchtop sequencer (Illumina, San Diego, California, USA) after HaloPlex™ Custom Target Enrichment System (Agilent). The obtained data were subsequently analysed, and the BAM and VCF files were obtained using SureCall NGS Data Analysis software (Agilent), with the help of the Burrows-Wheeler Alignment maximal exact matches tool and SNPPEP single nucleotide polymorphism caller. At least 99% of the target regions (exons including 20 base pair flanking regions) were covered by at least 20 reads.

HaloPlex HS was used, and all variants with an allele frequency of >1% were analysed. Using this very sensitive method, a splice variant, c.4663-1G>A, was identified in mosaic form (10%). The presence of the variant was confirmed by allele-specific PCR using four different allele-specific primer pairs:

1. *Tsc24663-1GWT/mutF*:  
*ggtgtgctttgagtgtggag/Tsc24663-1GWtR*:  
*tggcgagctcgctgttgctc*
2. *Tsc24663-1GWtF*: *gcctctcccctctccccacag/*  
*Tsc24663-1GWt/mutR*:  
*TGCCAGCAGTAGGTGAACTG*
3. *Tsc24663-1GWT/MutF*:  
*ggtgtgctttgagtgtggag/Tsc24663-1GMutR*:  
*tggcgagctcgctgttgctg*
4. *Tsc24663-1GMutF*: *gcctctcccctctccccacac/*  
*Tsc24663-1GWt/MutR*:  
*TGCCAGCAGTAGGTGAACTG*

Primer pairs 1 and 2 amplify the normal (wt) allele (G) in a forward and reverse direction, whereas primer pairs 3 and 4 amplify the variant allele (C) in a forward and reverse direction. A normal DNA sample was included as a control in addition to DNA from the authors' case.

The above is a *TSC2* GenBank reference sequence (accession number: NG\_005895.1). Numbering is according to the *TSC2* GenBank reference sequence (accession number: NM\_000548.3), in which nucleotide 1 is A in ATG-translation initiation codon.

## DISCUSSION

The case describes a patient with mosaic TSC, with a low VAF variant (10%) but still with three affected organ systems (skin, eyes, and kidneys). This shows that, even though a patient with TSC has a mosaic form of the disease and a mild clinical phenotype, several organ systems can be affected. Regarding the diagnostic criteria of TSC, the patient had three major features (three hypomelanotic macules, facial angiofibromas, and angiomyolipomas) and one minor feature (multiple renal cysts), and thereby fulfilled a clinical diagnosis of TSC (Table 1).<sup>15</sup>

After the introduction of NGS, more pathogenic variants in *TSC1* and *TSC2* are now detected including pathogenic variants in mosaic state.<sup>3,5</sup> NGS, with sufficient depth, can detect pathogenic variants with a very low VAF (>1%).<sup>4,16</sup>

Patients with mosaic TSC tend to have fewer major symptoms (Table 1) and fewer organ systems involved compared to patients with germline TSC.<sup>2,3</sup> Overall, patients with mosaic TSC have a milder phenotype compared to patients with germline TSC, but the disease spectrum for patients with mosaic TSC can resemble and overlap with patients with germline TSC.<sup>1,2,12</sup> Treichel et al.<sup>13</sup> have proposed a diagnostic algorithm to detect possible mosaic TSC in patients. It was suggested that low-level mosaicism includes <3 mucocutaneous findings, the absence of tubers and subependymal nodules, and asymmetrical distributed angiofibromas with <100 lesions;<sup>13</sup> however, exceptions from this suggestion exist.

Angiofibromas are a common skin manifestation and have been reported in as many as 92% of a cohort of 24 patients with mosaicism.<sup>12</sup> Most frequently, angiofibromas are distributed bilaterally over the central part of the face, as with the authors' patient; however, unilateral involvement has been found in some patients with mosaicism.<sup>1,18-20</sup> In the authors' patient, the hypomelanotic macules were unilateral. Many

**Table 1: Major and minor diagnostic criteria in tuberous sclerosis complex.**

<b>Major criteria</b>
1. Hypomelanotic macules ( $\geq 3$ , at least 5 mm diameter)
2. Angiofibromas ( $\geq 3$ ) or fibrous cephalic plaques
3. Ungual fibromas ( $\geq 2$ )
4. Shagreen patch
5. Multiple retinal hamartomas
6. Cortical dysplasias
7. Subependymal nodules
8. Subependymal giant cell astrocytoma
9. Cardiac rhabdomyoma
10. Lymphangiomyomatosis
11. Angiomyolipomas ( $\geq 2$ )
<b>Minor criteria</b>
1. 'Confetti' skin lesions
2. Dental enamel pits ( $> 3$ )
3. Intra-oral fibromas ( $\geq 2$ )
4. Retinal achromic patch
5. Multiple renal cysts
6. Non-renal hamartomas

Definite diagnosis: two major features or one major feature with  $\geq 2$  minor features. Possible diagnosis: either one major feature or  $\geq 2$  minor features.<sup>15,17</sup>

mucocutaneous findings are less frequent among patients with mosaic TSC, and the time of onset for unguinal fibromas and angiofibromas is, in general, delayed.<sup>1,12</sup> Overall, there is no significant difference in the prevalence of skin manifestations between patients with germline variants in *TSC1* or *TSC2* and patients with NMI.<sup>4</sup>

The neurological phenotype in patients with mosaic TSC can be characteristic and thereby an indication of mosaicism in TSC.<sup>1</sup> The most common neurological phenotype in patients with mosaic TSC is the presence of cortical tubers and absence of subependymal nodules. However, the presence as well as the absence of both cortical tubers and subependymal nodules has been observed in patients with mosaic TSC.<sup>1,13,21,22</sup> Cortical tubers, subependymal nodules, and subependymal giant cell astrocytomas occur more often in patients with germline TSC compared with patients with mosaic TSC.<sup>12</sup> Subependymal nodules and cortical tubers are both relatively frequent manifestations, and subependymal giant cell astrocytomas are more

rare manifestations.<sup>4,23-26</sup> The authors' patient had no abnormal findings on his brain scan.

Seizures are a frequent manifestation in patients with germline TSC as two studies have shown 91% and 88% are affected, respectively, while it is less frequently seen in patients with mosaicism (57.0% and 32.3%).<sup>12,27</sup>

Prevalence of intellectual disability varies greatly in patients with NMI.<sup>4,23-26,28-31</sup> The median prevalence value is 39%.<sup>4</sup> Both intellectual disability and attention deficit hyperactivity disorder occur more frequently in patients with NMI than patients with a pathogenic variant in *TSC1*, but less frequently compared to patients with *TSC2* variants.<sup>4,32</sup> Autism is seen in patients with TSC with a higher prevalence among patients with a *TSC2* pathogenic variant, and less frequent among patients with a *TSC1* variant and in patients with mosaicism.<sup>4,12</sup>

Ocular manifestations consist of hamartomas limited to the retina.<sup>4,33</sup> Retinal hamartomas have been found in 14.8% of patients with mosaic TSC

compared with 21% of patients with TSC, but without statistical significance.<sup>12</sup>

Renal lesions, including angiomyolipomas and renal cysts, have been described in 39–67% and 18–31% of patients with NMI, respectively.<sup>4,23–26,28,34</sup> One study found angiomyolipomas to be more common in patients with mosaicism compared to patients with TSC, although there was no statistically significant difference.<sup>12</sup> The *TSC2* gene is adjacent to the *PKD1* gene, which causes polycystic kidney disease, and a gene alteration involving both genes results in a very serious renal phenotype.<sup>4,33,35</sup> Among mosaic patients, deletions involving *TSC2* and *PKD1* are frequent, but the renal function is better preserved.<sup>36</sup>

Cardiac rhabdomyomas can be seen in patients with TSC and, less frequently, in patients with mosaicism.<sup>12</sup> They have been reported in 33–56% of patients with NMI.<sup>4,24–26,28,37</sup>

The frequency of pulmonary lymphangiomyomatosis (LAM) in patients with mosaicism has been reported with contradictory results. One study suggests that the prevalence of LAM is the same for patients with mosaicism and patients with germline TSC,<sup>1</sup> while another concludes LAM to be less frequent among patients with mosaic TSC.<sup>12</sup> Additionally, LAM has been described to occur more often in patients with NMI compared with patients with *TSC2* and *TSC1* pathogenic variants.<sup>4,23,28</sup> The high rate in patients with NMI might be influenced by the small samples that have been analysed.<sup>4</sup>

When TSC is diagnosed in a family, genetic counselling is necessary. Usually, genetic tests and thorough clinical evaluations of the parents are needed to determine whether the variant is inherited or *de novo*.<sup>4,5</sup> In patients with mosaic TSC, the pathogenic variant has occurred postzygotic and, therefore, is not inherited. The descendants of a patient with mosaicism should always be offered a thorough clinical as well as a genetic examination, since patients with mosaic TSC are at risk of having offspring with non-mosaic TSC.<sup>18,38</sup> The risk of inheriting the pathogenic variant is up to 50% in the descendants of patients with mosaic TSC and depends on the size of the VAF.<sup>16</sup>

If the parents of a child with TSC are unaffected, without a pathogenic variant, and mosaicism has not been confirmed in the index patient, gonadal

mosaicism cannot be excluded and the sibling(s) of the patient with TSC should be thoroughly examined.<sup>18,38</sup> The incidence of gonadal mosaicism in TSC is approximately 2%.<sup>16,18,38</sup>

Mosaicism can be defined as a VAF <40%.<sup>1,39</sup> The size of VAF depends on the timing of the mutation during embryogenesis (Figure 1).<sup>40</sup> VAF varies in different types of tissue within the same patient. Affected skin biopsies have a median VAF that is twice as high as in blood, saliva, and normal skin.<sup>3,9,12</sup> The size of VAF and the number of major features correlate, i.e., clinical manifestations can vary depending on the timing of the mutation during embryogenesis. If it occurs early, a large fraction of the cells will contain the pathogenic variant, resulting in a phenotype with more TSC manifestations. If the mutation occurs later, the pathogenic variant will only be present in certain tissues and patients will have a milder phenotype.<sup>1,5,18</sup>

There is a considerable inter- and intrafamilial variation among organ manifestations.<sup>4,5</sup> These make it difficult to predict the phenotype at the individual level.<sup>4</sup>

Since 2003, Copenhagen University Hospital has offered screening for pathogenic variants in *TSC1* and *TSC2*. From 2017, the screening has been performed using NGS, and since 2018, screening for mosaic pathogenic variants were included. So far, predicted pathogenic variants in *TSC1* or *TSC2* have been identified in a total of 178 individuals. Since 2015, Aarhus University Hospital, Denmark, has also examined the *TSC1* and *TSC2* genes using NGS, with an allele frequency of 10% as limit of detection. In the last 3 years, Copenhagen University Hospital has identified pathogenic variants in 12 patients, of which three had pathogenic variants in mosaic state (patients with mosaic TSC). Aarhus University Hospital has identified pathogenic variants in 17 patients with TSC, where two patients had a VAF of 37% and 40%, respectively, and mosaicism could neither be confirmed nor excluded.

Low VAF and mosaicism continue to be hurdles in molecular genetic diagnostics of TSC, but the advent of NGS has improved the potential in diagnostics of patients with mosaicism. The phenotype among patients with mosaic TSC varies considerably, and it is nearly impossible to establish a clear definition of the clinical picture

of TSC mosaics; however, a hint may be unilateral angiofibromas and the absence of tubers and subependymal nodules in low-level mosaicism. It is important to discover and diagnose even the mildly affected patients with mosaic TSC, since the descendants can inherit non-mosaic TSC with a more severe phenotype. Therefore, genetic counselling, including thorough clinical as well as a genetic examination, is crucial.

In the case reported here, the patient presented with mild clinical symptoms of TSC in adulthood. When examining the patient, TSC manifestations were found in eyes, skin, and kidneys, and a molecular genetic analysis showed a pathogenic variant in *TSC2* with a mosaic level of 10%. It would be interesting to investigate the different affected and non-affected tissues to see if the mosaic frequency is similar in all.

## References

- Treichel AM et al. Phenotypic distinctions between mosaic forms of tuberous sclerosis complex. *Genet Med*. 2019;21(11):2594-604.
- Byers HM et al. Minimal mosaicism, maximal phenotype: Discordance between clinical and molecular findings in two patients with tuberous sclerosis. *Am J Med Genet C Semin Med Genet*. 2018;178(3):374-8.
- Tyburczy ME et al. Mosaic and intronic mutations in *TSC1/TSC2* explain the majority of TSC patients with no Mutation identified by conventional testing. *PLoS Genet*. 2015;11(11):e1005637.
- Curatolo P et al. Genotype/phenotype correlations in tuberous sclerosis complex. *Semin Pediatr Neurol*. 2015;22(4):259-73.
- Peron A et al. Genetics, genomics, and genotype-phenotype correlations of TSC: insights for clinical practice. *Am J Med Genet C Semin Med Genet*. 2018;178(3):281-90.
- Crino PB et al. The tuberous sclerosis complex. *New Engl J Med*. 2006;355(13):1345-56.
- Chu-Shore CJ et al. The natural history of epilepsy in tuberous sclerosis complex. *Epilepsia*. 2010;51(7):1236-41.
- Henske EP et al. Tuberous sclerosis complex. *Nat Rev Dis Primers*. 2016;2:16035.
- Lam HC et al. New developments in the genetics and pathogenesis of tumours in tuberous sclerosis complex. *J Pathol*. 2017;241(2):219-25.
- Sampson JR et al. Genetic aspects of tuberous sclerosis in the west of Scotland. *J Med Genet*. 1989;26(1):28-31.
- Campbell IM et al. Somatic mosaicism: implications for disease and transmission genetics. *Trends Genet*. 2015;31(7):382-92.
- Giannikou K et al. Low-level mosaicism in tuberous sclerosis complex: prevalence, clinical features, and risk of disease transmission. *Genet Med*. 2019;21(11):2639-43.
- Treichel AM et al. A diagnostic algorithm for enhanced detection of mosaic tuberous sclerosis complex in adults. *Brit J Dermatol*. 2020;182(1):235-7.
- Nellist M et al. Targeted next generation sequencing reveals previously unidentified *TSC1* and *TSC2* mutations. *BMC Med Genet*. 2015;16:10.
- Northrup H, Krueger DA. Tuberous sclerosis complex diagnostic criteria update: recommendations of the 2012 International Tuberous Sclerosis Complex Consensus Conference. *Pediatr Neurol*. 2013;49:243-54.
- Verhoef S et al. High rate of mosaicism in tuberous sclerosis complex. *Am J Hum Genet*. 1999;64(6):1632-7.
- Portocarrero LKL et al. Tuberous sclerosis complex: review based on new diagnostic criteria. *An Bras Dermatol*. 2018;93(3):323-31.
- Nathan N et al. Mosaic disorders of the PI3K/PTEN/AKT/TSC/mTORC1 signaling pathway. *Dermatol Clin*. 2017;35(1):51-60.
- Chernoff KA, Schaffer JV. Cutaneous and ocular manifestations of neurocutaneous syndromes. *Clin Dermatol*. 2016;34(2):183-204.
- Baroni A et al. Facial unilateral angiofibromas: a postzygotic tuberous sclerosis like mutation. *Indian J Dermatol Venereol Leprol*. 2011;77(6):731.
- Boronat S et al. Absence of subependymal nodules in patients with tubers suggests possible neuroectodermal mosaicism in tuberous sclerosis complex. *Clev Med Child Neurol*. 2014;56(12):1207-11.
- Boronat S et al. Tuberous Sclerosis complex without tubers and subependymal nodules: a phenotype-genotype study. *Clin Genet*. 2014;86(2):149-54.
- Camposano SE et al. Distinct clinical characteristics of tuberous sclerosis complex patients with no mutation identified. *Ann Hum Genet*. 2009;73(2):141-6.
- Au KS et al. Genotype/phenotype correlation in 325 individuals referred for a diagnosis of tuberous sclerosis complex in the United States. *Genet Med*. 2007;9(2):88-100.
- Sancak O et al. Mutational analysis of the *TSC1* and *TSC2* genes in a diagnostic setting: genotype - phenotype correlations and comparison of diagnostic DNA techniques in tuberous sclerosis complex. *Eur J Hum Genet*. 2005;13(6):731-41.
- Lee JS et al. Mutational analysis of paediatric patients with tuberous sclerosis complex in Korea: genotype and epilepsy. *Epileptic Disord*. 2014;16(4):449-55.
- Kozłowski P et al. Identification of 54 large deletions/duplications in *TSC1* and *TSC2* using MLPA, and genotype-phenotype correlations. *Hum Genet*. 2007;121(3-4):389-400.
- Dabora SL et al. Mutational analysis in a cohort of 224 tuberous sclerosis patients indicates increased severity of *TSC2*, compared with *TSC1*, disease in multiple organs. *Am J Hum Genet*. 2001;68(1):64-80.
- van Eeghen AM et al. Genotype and cognitive phenotype of patients with tuberous sclerosis complex. *Eur J Hum Genet*. 2012;20(5):510-5.
- Jansen FE et al. Overlapping neurologic and cognitive phenotypes in patients with *TSC1* or *TSC2* mutations. *Neurology*. 2008;70(12):908-15.
- Winterkorn EB et al. Cognitive prognosis of patients with tuberous sclerosis complex. *Neurology*. 2007;68(1):62-4.
- Muzykewicz DA et al. Psychiatric comorbid conditions in a clinic population of 241 patients with tuberous sclerosis complex. *Epilepsy Behav*. 2007;11(4):506-13.
- Northrup H et al. "Tuberous sclerosis complex," Adam MP et al, (eds.) *GeneReviews*® (1993-2021), Seattle: University of Washington, Seattle.
- Rakowski SK et al. Renal manifestations of tuberous sclerosis complex: incidence, prognosis, and predictive factors. *Kidney Int*. 2006;70(10):1777-82.

35. Martignoni G et al. Renal disease in adults with *TSC2/PKD1* contiguous gene syndrome. *Am J Surg Pathol.* 2002;26(2):198-205.
36. Sampson JR et al. Renal cystic disease in tuberous sclerosis: role of the polycystic kidney disease 1 gene. *Am J Hum Genet.* 1997;61(4):843-51.
37. Józwiak S et al. Clinical and genotype studies of cardiac tumors in 154 patients with tuberous sclerosis complex. *Pediatrics.* 2006;118(4):e1146-51.
38. Biesecker LG, Spinner NB. A genomic view of mosaicism and human disease. *Nat Rev Genet.* 2013;14(5):307-20.
39. Acuna-Hidalgo R et al. Post-zygotic point mutations are an underrecognized source of de novo genomic variation. *Am J Hum Genet.* 2015;97(1):67-74.
40. Strom SP. Current practices and guidelines for clinical next-generation sequencing oncology testing. *Cancer Biol. Med* 2016;13(1):3-11.

FOR REPRINT QUERIES PLEASE CONTACT: [INFO@EMJREVIEWS.COM](mailto:INFO@EMJREVIEWS.COM)

# Emerging Treatment Regimens in Psoriasis: Are There Advantages Over Current Biologic Therapies?

**Authors:** \*Joseph M. Nenow,<sup>1</sup> Esther A. Balogh,<sup>2</sup> Steven R. Feldman<sup>1,2,3,4</sup>

1. Center for Dermatology Research, Department of Dermatology, Wake Forest School of Medicine, Winston-Salem, North Carolina, USA
2. Department of Pathology, Wake Forest School of Medicine, Winston-Salem, North Carolina, USA
3. Department of Social Sciences & Health Policy, Wake Forest School of Medicine, Winston Salem, North Carolina, USA
4. Department of Dermatology, University of Southern Denmark, Odense, Denmark

\*Correspondence to [josephnenow@gmail.com](mailto:josephnenow@gmail.com)

**Disclosure:** Feldman has received research, speaking, and/or consulting support from Galderma, GlaxoSmithKline (GSK)/Stiefel, Almirall, Leo Pharma, Boehringer Ingelheim, Mylan, Celgene, Pfizer, Valeant, Abbvie, Samsung, Janssen, Lilly, Menlo, Merck, Novartis, Regeneron, Sanofi, Novan, QuriEnt, National Biological Corporation, Caremark, Advance Medical, Sun Pharma, Suncare Research, Informa, UpToDate, and National Psoriasis Foundation; is founder and majority owner of [www.DrScore.com](http://www.DrScore.com); and founder and part owner of Causa Research, a company dedicated to enhancing patients' adherence to treatment. The other authors have declared no conflicts of interest.

**Received:** 14.07.21

**Accepted:** 08.10.21

**Keywords:** Adherence, antagonist, IL-17, IL-23, JAK inhibitors, naltexone, plaque psoriasis, psoriatic arthritis, retinoic acid receptor-related orphan receptor  $\gamma$  antagonist.

**Citation:** EMJ Dermatol. 2021;9[1]:106-121.

## Abstract

Psoriasis is a chronic inflammatory skin condition that impacts patients' quality of life and has large economic consequences. While current biologics are remarkable for their efficacy and safety, opportunities for improvement exist due to their rare side effects, fading efficacy, method of delivery, and expense. Biologics such as bimekizumab offer high likelihood of clearance, while oral options (e.g., deucravacitinib) allow patients to avoid injections and achieve efficacies similar to adalimumab or ustekinumab. As a result, there is limited room for the development of new biologics. Several oral therapies such as the oral monoclonal microbial EDP1815 have the potential to meet patient expectations for efficacy and convenient administration. However, emerging treatment regimens for plaque psoriasis will increasingly require a multimodal approach, addressing patient adherence, lifestyle choices, and awareness of the individual's underlying pathophysiological processes. In this narrative review, the authors discuss recent advances in the development of biologic and oral small molecules for plaque psoriasis.



## Disease Background and Overview of Treatment

Psoriasis is a chronic inflammatory skin condition that affects 2–3% of the population in the USA and has extensive psychosocial and economic consequences.<sup>1</sup> Sustained inflammation leads to uncontrolled proliferation and differentiation of keratinocytes. Although psoriasis variants share a root pathophysiology, variations in pathways lead to variable treatment effectiveness.<sup>2</sup> There are three categories of treatment for plaque psoriasis: topical medications, phototherapy, and systemic therapies. Topical therapies are the first-line treatment for localised psoriasis.<sup>3,4</sup> Ultraviolet (UV) light can be used for localised and extensive psoriasis.<sup>3</sup> Home phototherapy units can reduce cost and increase convenience. Nevertheless, the use of UV for moderate-to-severe psoriasis is declining in popularity, likely due to perceived high price, poor reimbursement, and the availability of highly effective, safe, and more convenient systemic treatments.<sup>5–7</sup> The presence of moderate-to-severe disease often requires treatment with systemic therapies. Of the available systemic treatments, current professional dermatological association guidelines recommend biologics for the treatment of moderate-to-severe plaque psoriasis that is recalcitrant to local therapies.<sup>8</sup>

### Systemic Therapy: Indications and General Options

Among biologic therapies, three classes are used for moderate-to-severe psoriasis: TNF- $\alpha$  inhibitors, IL-17 inhibitors, and IL-23 inhibitors.<sup>8</sup>

#### TNF- $\alpha$ inhibitors

The first generation of TNF- $\alpha$  inhibitors has potent initial efficacies. The most common method of reporting efficacy is the Psoriasis Area and Severity Index (PASI), a standard tool for scoring psoriasis severity. Following 12 weeks of use for infliximab or adalimumab, PASI90 (i.e., a 90% improvement from baseline) was achieved in approximately 50% of patients in treatment arms.<sup>9–11</sup> PASI75 was achieved by 49% of patients treated with etanercept 50 mg twice a week at 12 weeks ( $p < 0.0001$ ). When combined

with phototherapy, etanercept therapies have achieved a PASI90 in 58.1% over the same timeframe.<sup>12,13</sup> These strong initial responses often fade. In the Danish DERMBIO registry study of 1,867 psoriasis treatment courses, 41.3% of these regimens were discontinued. The most common reason for discontinuation was the loss of efficacy (67.0%).<sup>14</sup> TNF- $\alpha$  inhibitors are contraindicated in those with a strong family history of malignancy or chronic infection (e.g., tuberculosis, hepatitis B virus).<sup>3</sup> As a result, there was an opportunity to develop novel therapies that averted some of the major class side effects, including the risk of serious infections (e.g., tuberculosis), malignancy, and major adverse cardiovascular events.<sup>15</sup>

TNF- $\alpha$  inhibitors also face competition from biosimilars. Recent adalimumab biosimilars include mjevita (adalimumab-atto), Cyltezo (adalimumab-adbm), Hyrimoz (adalimumab-adaz), Hadlima (adalimumab-bwwd), Abrilada (adalimumab-afzb), and Hulio (adalimumab-fkjp), with more on the way. Infliximab biosimilars include Inflectra (infliximab-dyyb), Renflexis (infliximab-abda), Ixifi (infliximab-qbtx), and Avsola (infliximab-axxq).<sup>16–19</sup> The influx of competitive agents may lead to a decrease in cost.

#### IL-17/23 axis

The IL-17/IL-23 axis is central to psoriasis pathophysiology, and inhibitors of these cytokines are effective psoriasis treatments.<sup>3</sup> The IL-17 inhibitor class consists of secukinumab, ixekizumab, and brodalumab.<sup>4,8</sup> The IL-23 inhibitor class contains inhibitors to the p19 subunit of IL-23 (guselkumab, tildrakizumab, and risankizumab) and ustekinumab, which binds the p40 subunit of IL-23 that is also in IL-12.<sup>4</sup> Many of these agents are both highly efficacious and generally well tolerated when used as treatments for moderate-to-severe plaque psoriasis. Ustekinumab, secukinumab, ixekizumab, brodalumab, guselkumab, and tildrakizumab have all entered clinical use for the treatment of moderate-to-severe plaque psoriasis.<sup>20</sup> In a systematic review, ixekizumab appears to be the most effective short-term agent (i.e., greatest PASI75/90 over 12 weeks [ $p < 0.00001/0.00001$ ]). It is also the most likely to be associated with one or more adverse effects (AE) ( $p < 0.00001$ ). Ixekizumab 80 mg, risankizumab 150 mg, and

brodalumab 210 mg have similar numbers needed to treat for PASI75 (1.18, 1.19, and 1.19, respectively).<sup>21</sup>

As novel therapies, the long-term AEs of the IL-17 and IL-23 classes are not fully known. Throughout recent years of clinical testing, they appear to be very safe. However, similarly to TNF- $\alpha$  inhibitors, efficacy can fade over time, perhaps due to neutralising antibodies.<sup>3,22</sup> Unfortunately, these therapies can cost 50,000 USD or more annually.<sup>23</sup> Though with several exceptions, most require administration by injection, which can be unfavourable for some patients.<sup>3,24</sup>

## EMERGING THERAPIES

### Biologics

#### IL-17 inhibitor: bimekizumab

Bimekizumab is an injectable IgG1 monoclonal antibody targeting IL-17A and IL-17F under development by UCB (Brussels, Belgium). Bimekizumab recently completed a direct comparison study against secukinumab in the BE RADIANT study, following its completion of comparison studies against adalimumab (BE SURE) and ustekinumab (BE VIVID). In this randomised, multicentre, double-blind study bimekizumab was compared to secukinumab, with the primary endpoint of PASI100 at 16 weeks.<sup>25</sup> At 16 weeks, 61.7% of the bimekizumab arm achieved PASI100 versus 48.9% in the secukinumab arm. Analysis proved bimekizumab to be non-inferior, and, subsequently, superior to secukinumab ( $p < 0.001$  each). After 48 weeks, 67.0% of the bimekizumab arm achieved PASI100 compared with 46.2% in the secukinumab arm. However, it must be noted that there was a documented greater association with oral candidiasis in the bimekizumab arm.<sup>26</sup>

In the BE SURE trial, the most common side effects for bimekizumab were found to be nasopharyngitis (20.9%), oral candida infection (16.2%), and upper respiratory tract infection (9.0%). Throughout the trial, no serious AEs were reported in the treatment arm. Potential serious AEs included suicidal ideation or behaviour, inflammatory bowel disease, or major adverse cardiac events.

Previously, bimekizumab had undergone a Phase

III, randomised, double blind, placebo-controlled trial (BE READY).<sup>27</sup> The study enrolled 435 adults with moderate-to-severe plaque psoriasis. It consisted of an initial treatment period followed by a randomised withdrawal period lasting a combined 56 weeks. BE READY met its primary endpoints of PASI90 and an Investigator's Global Assessment (IGA) response of clear or almost clear (IGA 0/1) compared to placebo after 16 weeks of treatment.<sup>27</sup>

In a previous Phase IIb study (BE ABLE 1) on bimekizumab's safety, there was no association of bimekizumab with any dose-related safety risks or unexpected safety signals in a set of 250 patients. Treatment-emergent AEs occurred in 61% (126/208) of bimekizumab patients compared with 36% (15/42) of patients in the placebo arm. These AEs led to a study discontinuation rate of 4.8% (10/208) in the bimekizumab arm and 2.4% (1/42) in the placebo arm. The side effects leading to discontinuation included the diagnosis of colon cancer and, in a separate case, a large gastrointestinal polyp, which was deemed unrelated to the study treatment by the investigator.<sup>28</sup>

#### Inhibitory receptor agonist: CC-90006

CC-90006 is a subcutaneous injection programmed cell death protein-1 agonist antibody being developed by Celgene (Uxbridge, UK) for the treatment of mild-to-moderate plaque-type psoriasis. It recently completed Phase I testing in a multicentre, randomised, double-blind, placebo-controlled, multiple-dose study to evaluate drug safety, tolerability, pharmacokinetics, and pharmacodynamics in 34 participants with mild-to-moderate plaque-type psoriasis.<sup>29</sup> No results are currently available for this or any other previous trials. Phase I testing was completed on April 26<sup>th</sup> 2019, but results have not yet been posted.<sup>29,30</sup>

### Oral Small Molecules

#### JAK family

##### *Filgotinib (GLPG0634)*

Filgotinib (GLPG0634) is an oral, selective JAK1 inhibitor developed by Galapagos (Mechelen, Belgium) for use in adults with psoriatic arthritis (PsA), ulcerative colitis, and Crohn's disease. Filgotinib was recently approved

for the treatment of rheumatoid arthritis by the European Medicines Agency (EMA) and Pharmaceuticals and Medical Devices Agency (PMDA), with initial clinical use beginning in 2020. In the USA, under a collaborative agreement, Gilead (Foster City, California) sought U.S. Food and Drug Administration (FDA) approval of filgotinib for rheumatoid arthritis. In August 2020, they discontinued the pursuit for approval in the USA.<sup>31</sup> Results from the previous Phase II EQUATOR trial,<sup>32</sup> a randomised, placebo-controlled trial for moderate-to-severely active PsA, are available. Primary study endpoints were based on American College of Rheumatologists 20 (ACR20), a composite measure defined as the improvement in at least 20% of tender and swollen joints among additional criteria and while in a state of minimal disease activity. At 16 weeks, 80% (52/65) of patients in the filgotinib group achieved ACR20 compared to 33% (22/66) in the placebo group ( $p < 0.0001$ ).<sup>33</sup> During the open-label extension portion of the study, which was extended until 52 weeks, 33.6% of patients in the filgotinib arm achieved minimal disease activity response and 55.0% achieved ACR50.<sup>34</sup> The drug is currently advancing to the pivotal Phase III PENGUIN clinical trial programme to confirm the safety and efficacy.<sup>35</sup>

### **PF-06826647**

PF-06826647 is an oral once daily tablet that acts through the inhibition of tyrosine kinase 2. It is being developed by Pfizer (New York City, New York, USA) for patients with moderate-to-severe plaque psoriasis. The drug is currently in a randomised, double-masked, parallel assignment, Phase II study of 179 participants to investigate its safety and efficacy for patients with moderate-to-severe plaque psoriasis.<sup>36</sup> The study was nominally completed on 26<sup>th</sup> November 2020, with results currently undergoing quality control as of 3<sup>rd</sup> May 2021.<sup>36</sup>

In a previous Phase I trial of PF-06826647 investigating safety, there were no clinically relevant differences in physical exam or lab data between the 400 mg, 100 mg, and placebo arms.<sup>37</sup> In the psoriasis cohort, the patients in the 400 mg treatment arm experienced AEs at a rate of 80.0% compared to 45.5% in the 100 mg arm and 50% in the placebo arm. All AEs were mild in severity, but were not individually identified. No serious or severe AEs of clinical

relevance were reported.<sup>37</sup>

### **BMS-986165 (deucravacitinib)**

BMS-986165 (deucravacitinib) is an oral selective tyrosine kinase 2 inhibitor developed by Bristol Myers Squibb (Uxbridge, UK) for the treatment of patients with moderate-to-severe plaque psoriasis. In recently published data from the POETYK PSO-1<sup>38</sup> and PSO-2<sup>39</sup> Phase II trials, 58.7%/53.6% of patients receiving deucravacitinib achieved PASI75 as compared to 35.1%/40.2% receiving apremilast, and 12.7%/9.4% in placebo groups at 16 weeks. Following 24 weeks of treatment, 69.0%/59.3% of patients reached PASI75 compared to 38.1%/37.8% receiving apremilast. Of the patients achieving PASI75 at 24 weeks, 82.5%/81.4% of patients in the PSO-1/PSO-2 trials maintained PASI75 response at 52 weeks. No serious or severe AEs were reported, including severe or opportunistic infections or thrombotic events. Among mild AEs, nasopharyngitis (5.7–17.9% versus 7.6% placebo) and sinusitis (0–7.6% versus 0% placebo) were the most reported complaints.<sup>37,40</sup>

## **Receptor antagonists**

### **Nuclear receptor antagonist: BI 730357**

BI 730357 is a film-coated tablet that acts as a pyrazinone retinoic acid receptor orphan receptor  $\gamma$  (ROR $\gamma$ ) antagonist. It is a ligand-regulated transcriptional factor with diverse roles in cell proliferation and differentiation.<sup>41</sup> It is being developed by Boehringer Ingelheim (Ingelheim am Rhein, Germany) for the treatment of moderate-to-severe plaque psoriasis. It is currently in a Phase II, interventional, randomised, double-blind, placebo-controlled long-term extension study of 180 participants to assess safety, tolerability, and efficacy in patients with moderate-to-severe plaque psoriasis.<sup>42</sup> It is estimated to be completed on 28<sup>th</sup> February 2027.<sup>42</sup> A previous, shorter-term Phase II study on safety, tolerability, and efficacy in 274 patients with moderate-to-severe plaque psoriasis was completed in June 2021, but no results are currently available.<sup>43</sup>

### **IL-2 receptor agonist: C-92252**

CC-92252 is an IL-2 receptor agonist and regulatory T-lymphocyte stimulant currently being developed by the Celgene for the

treatment of adults with psoriasis. It is now in Phase I of clinical development in a three-part interventional, randomised, parallel assignment study with quadruple masking.<sup>44</sup> With 133 enrolled participants, the study aims to evaluate pharmaceutical safety, tolerability, pharmacokinetics, and pharmacodynamics of ascending doses of CC-92252 in both healthy adult subjects and adult subjects with psoriasis. It is estimated to be completed on 30<sup>th</sup> September 2022.<sup>44</sup>

## Anti-inflammatory agents

### *μ-opioid antagonists (naltrexone)*

Naltrexone is a  $\mu$ -opioid antagonist taken orally and is under study for treatment of mild psoriasis by the Jinnah Postgraduate Medical Centre (JPMC; Karachi, Pakistan). The therapy has recently completed a Phase I clinical trial for the use of low-dose naltrexone in mild psoriasis in a tertiary care hospital in Karachi, Pakistan.<sup>45</sup> This interventional, single group assignment trial with no masking of 42 participants was completed on 30<sup>th</sup> September 2019. Following 12 weeks of low-dose naltrexone, relevant markers of psoriasis severity decreased compared with patient baseline before treatment: PASI by 4.96 ( $p < 0.001$ ), Dermatology Life Quality Index (DLQI) by 6.32 ( $p < 0.001$ ), and Investigator's Global Assessment and Body Surface Area (IGA\*BSA) by 3.9 ( $p < 0.001$ ). The efficacy of the drug may be due to regulation of lymphocyte responses, reduced cytokine production, and decreased mast cell activity. Via reduction of pruritus, systemic naltrexone can act in an adjunctive role to control patient scratching behaviours and minimise physical trauma to the affected area. Low-dose naltrexone is generally considered safe, but mood and liver abnormalities have occasionally been reported at high doses.<sup>46,47</sup>

### *Cannabinoids*

The endocannabinoid system maintains many aspects of skin homeostasis, such as proliferation, differentiation, and release of inflammatory mediators.<sup>48</sup> Cannabinoids may aid in the management of cutaneous diseases. They can act directly via neuronal modulation of peripheral itch fibres. They can also act centrally on cannabinoid receptors with additional unspecified actions in the endocannabinoid system and cholinergic

anti-inflammatory pathway.<sup>48,49</sup> In refractory cases following standard therapies, cannabinoid formulations may be considered as an adjuvant therapy due to their ability to reduce symptoms of chronic pruritus in limited human studies.<sup>48,50</sup>

Brown University (Providence, Rhode Island, USA) has begun to investigate the impact of cannabis on pain and inflammation in patients with arthritis. In a Phase II, randomised, placebo-controlled, cross-over assignment, double-blind study.<sup>49</sup> Brown University is exploring the effects of oral medium tetrahydrocannabinol or cannabidiol on pain symptomology and inflammatory markers in patients with rheumatoid or PsA. The study consists of 76 participants and has an estimated completion date of 31<sup>st</sup> July 2022.<sup>49</sup>

## Oral microbials

### *EDP1815*

EDP1815 is an oral tablet form of a monoclonal strain of *Prevotella histicola*, selected for its potent anti-inflammatory pharmacology. It is being developed by Evelo Biosciences (Cambridge, Massachusetts, USA). It is currently in Phase II of development for the treatment of mild-to-moderate plaque psoriasis.<sup>51</sup>

In a Phase II, multicentre, randomised, double-blind, placebo-controlled trial, EDP1815 is being investigated for its efficacy and safety in the treatment of 225 participants with mild-to-moderate plaque psoriasis. It aims to identify an optimal dose in these patients and is expected to be completed by 23<sup>rd</sup> December 2021.<sup>52</sup>

Previously, EDP1815 had been explored in a Phase I, randomised, double-blind, placebo-controlled, ascending dose study in healthy participants, patients with atopic dermatitis and patients with mild-to-moderate psoriasis.<sup>53</sup> The study was completed on 31<sup>st</sup> October 2019. Results are compared to placebo and following a 56-day treatment regimen. In the atopic dermatitis cohorts, there was a 62% difference in Eczema Area and Severity Index (EASI) score ( $p = 0.034$ ) and 71% difference ( $p = 0.019$ ) in IGA\*BSA. On Day 56, 10/16 patients showed improvements in EASI, with three of those ten patients achieving an EASI75 clinical response. In the psoriasis cohorts, EDP1815 limited the production of inflammatory-mediator cytokines, including IL-1, -6, and -8, and TNF. There was no

statistical significance in the incidence of nausea, vomiting, diarrhoea, or abdominal pain between treatment and placebo arms. No serious side effects were reported.<sup>54</sup>

## PSORIASIS PHARMACOLOGY IN BROADER CONTEXT

Compared to today's standard of care (e.g., IL-17/IL-23 inhibitors) (Table 1), emerging agents (Table 2) do not show apparent advantages in terms of efficacy or safety. Emerging agents will likely need to demonstrate a benefit outside of clinical efficacy (e.g., cost or ease of use) to ensure clinical adoption. By comparison, the pharmacology of the future promises increased effectiveness and adherence through personalisation. Technological advances in tissue imaging, analysis, and proteogenomics will elucidate disease pathophysiology and help individualise treatment regimens.<sup>67,68</sup> Recent discoveries in inflammatory marker and regulator systems (including pentraxin, receptor-acting protein kinases, and mixed-lineage kinase domain-like pseudokinase) offer potential targets for therapeutic intervention.<sup>69,70</sup> As advances are made in the understanding of mRNA regulation in psoriasis, opportunities will arise for more accurate monitoring and efficacious intervention.<sup>69,71,72</sup>

Exclusive discussion of pharmacology creates an incomplete picture of the advances made in psoriasis management. Understanding and combating poor medication adherence is essential to improving clinical outcomes. Currently, poor adherence not only leads to poor clinical outcomes, but also skews clinical trial data. It is important to note that adherence in clinical trials may be higher than in daily life when dosing is not monitored.<sup>73</sup>

Persistence rates vary significantly by agent and class. In a 2015 cross-sectional study, persistence rates were 19% for etanercept, 53% for adalimumab, and 71% for ustekinumab over 12 months ( $p < 0.05$ ).<sup>74</sup> In a study of ustekinumab, which measured patient persistence rates over 6 months, ustekinumab showed a persistence rate of 81.4%; this is similar to the 80.6% and 87.4% persistence rates as seen in ixekizumab patients.<sup>75</sup> The underlying reasons for these varying persistence rates remain complex.

In one study, the most reported reason for discontinuing a psoriasis treatment regimen was 'ineffective treatment' (cited by 64.7% of patients). Poor dose-escalation schedule may impact these findings as patients may be pre-emptively discontinuing treatment due to perceived lack of efficacy. Alternatively, class efficacy may play a role. After switching to an IL-17 inhibitor, 45.7% of patients reported symptoms as "better," while 26.5% reported no change in symptoms. Patients are more adherent to treatment regimens if their prescribing provider had specialty training in rheumatology.<sup>76</sup> This finding may be due to greater adherence from patients with joint symptomology or the association of joint symptomatology with more severe skin findings. When appropriately treated, this patient population may experience greater improvement in quality of life than patients without rheumatological findings.

Medication adherence is associated with numerous factors outside of the treatment class used. Important negative predictors of adherence include a negative emotional state (i.e., presence of anxiety or depression) and unaddressed concerns regarding the disease, medication side effects, or potential for medication overuse. The evidence between demographic traits and adherence is more mixed, and definitive conclusions cannot be drawn.<sup>77,78</sup> For patients with poor medication adherence, the three most common reasons for missing doses included forgetting (49%), feeling unwell (26%), and being too busy (15%).<sup>77</sup> eHealth interventions (e.g., app notification services) have some effectiveness in using patient data to improve treatment adherence.<sup>73,79-81</sup> Through clinical deployment, they may improve adherence through patient education and assistance in scheduling medication administration.

## CONCLUSION

Overall, many patients with psoriasis have mild disease and could be adequately treated with a combination of topical treatments and phototherapy. For those requiring systemic treatment, current biologic therapies provide safety and efficacy but can be costly. The current market is competitive. Excellent efficacy rates are available through bimekizumab for those who seek the highest

likelihood of clearance. Oral options are available (e.g., deucravacitinib) with efficacies similar to adalimumab or ustekinumab. Current clinical trials display no clear advantage in efficacy (Table 3). As a result, there is little room for the development of new biologics. Several oral therapies, including oral monoclonal microbials EDP1066, can meet patient

expectations as favourable and effective treatments of plaque psoriasis. Emerging treatment regimens for plaque psoriasis will increasingly require a multimodal approach addressing patient adherence, lifestyle choices, and awareness of the individual's underlying pathophysiological processes.

**Table 1: Efficacy and adverse effects of current systemic plaque psoriasis therapies.**

Class	Agents	Efficacy (at 12 weeks)	Adverse effects
TNF- $\alpha$ inhibitors	Etanercept, infliximab, adalimumab	Infliximab/adalimumab: <ul style="list-style-type: none"> <li>• PASI90: approximately 50.0%<sup>8-10</sup></li> </ul> Etanercept: <ul style="list-style-type: none"> <li>• PASI75: 49.0%<sup>11</sup></li> </ul> Etanercept + phototherapy: <ul style="list-style-type: none"> <li>• PASI90: 58.1%<sup>12</sup></li> </ul>	<ul style="list-style-type: none"> <li>• Risk of serious infection (TB, HBV) or malignancy<sup>14</sup></li> <li>• Some evidence of increased development of non-melanomatous skin cancers<sup>55</sup></li> <li>• Mixed evidence concerning risk of heart failure<sup>56</sup></li> <li>• Black box warnings for increased risk of developing active tuberculosis, invasive fungal infections, and opportunistic bacterial and viral infections<sup>55</sup></li> </ul>
IL-23 Inhibitors	Guselkumab, tildrakizumab, risankizumab	Guselkumab: <sup>57</sup> <ul style="list-style-type: none"> <li>• PASI75: 50.0-100.0%</li> <li>• PASI90: 70.0-73.3% (16 weeks)</li> </ul> Tildrakizumab: <sup>58</sup> <ul style="list-style-type: none"> <li>• PASI75: 66.3-74.4% (16 weeks)</li> </ul> Risankizumab: <sup>59</sup> <ul style="list-style-type: none"> <li>• PASI90: 74.8-75.3% (16 weeks)</li> </ul>	<ul style="list-style-type: none"> <li>• No statistical difference in occurrence of serious adverse effects versus placebo.<sup>60,61</sup></li> <li>• Minor side effects such as upper respiratory infections, nasopharyngitis, and headaches were experienced widely across all agents, including guselkumab (49%), tildrakizumab (data not available), and risankizumab (56%) at the end of 16 weeks<sup>61,62</sup></li> </ul>

Table 1 continued.

Class	Agents	Efficacy (at 12 weeks)	Adverse effects
IL-17 Inhibitors	Secukinumab, ixekizumab, brodalumab <sup>59</sup>	<p>Secukinumab:<sup>63,64</sup></p> <ul style="list-style-type: none"> <li>• PASI75: 71.6–81.6%</li> </ul> <p>Brodalumab:<sup>63,65</sup></p> <ul style="list-style-type: none"> <li>• PASI75: 77.0–82.0%</li> </ul> <p>Ixekizumab:<sup>63</sup></p> <ul style="list-style-type: none"> <li>• PASI75: 76.7–82.8%</li> </ul>	<p>Secukinumab:<sup>64</sup></p> <ul style="list-style-type: none"> <li>• Most commonly associated with nasopharyngitis, headache, and diarrhoea</li> </ul> <p>Brodalumab:<sup>65</sup></p> <ul style="list-style-type: none"> <li>• Most commonly associated with upper respiratory infections, nasopharyngitis, and injection-site erythema.</li> <li>• There are two documented cases of neutropenia that resolved with cessation</li> </ul> <p>Ixekizumab:</p> <ul style="list-style-type: none"> <li>• Has been associated with hypertriglyceridaemia, peripheral oedema, hypersensitivity, and urticaria</li> <li>• Most commonly associated with injection site erythema (15%)</li> <li>• Risk of serious side effects in one meta-analysis was not significantly different than placebo</li> </ul>

HBV: hepatitis B virus; PASI75: Psoriasis Area and Severity Index with 75% improvement from baseline; PASI90: Psoriasis Area and Severity Index with 90% improvement from baseline; TB: tuberculosis.

Table 2: Summary of discussed biologic and oral compounds.

Compound	Company	Indications	Development state	Route of administration	Mechanism of action	Efficacy	Adverse effects
Bimekizumab	UCB (Brussels, Belgium)	Moderate-to-severe psoriasis	Phase III	Injectable	Inhibition of IL-17A and IL-17F	PASI100 61.7% (16 weeks), 67.0% (48 weeks)	Nasopharyngitis (20.9%), oral candida infection (16.2%) and upper respiratory tract infection (9.0%) (BE SURE) <sup>66</sup>
CC-90006	Calgene (Uxbridge, UK)	Mild-to-moderate plaque psoriasis	Phase I	Injectable	PD-1 agonist	No data available	No data available

Table 2 continued.

Compound	Company	Indications	Development state	Route of administration	Mechanism of action	Efficacy	Adverse effects
Filgotinib (GLPG0634)	Galapagos (Mechelen, Belgium)	Psoriatic arthritis, ulcerative colitis, and Crohn's disease	Phase II	Oral	Selective JAK1 inhibitor	ACR20, 80% (16 weeks) ACR50, 55.0% (52 weeks) <sup>40</sup>	Most commonly associated with nasopharyngitis and headache (57.0%)  One instance of fatal pneumonia (1.5%) <sup>40</sup>
PF-06826647	Pfizer (New York City, New York, USA)	Moderate-to-severe plaque psoriasis	Phase II	Oral	TYK2 inhibitor	No data available	No serious, severe, or fatal AEs  Patients experienced AEs at a rate of 45.5–80.0%. All were mild  Exact nature of AEs was not specified. <sup>35</sup>
BMS-986165 (deucravacitinib)	Bristol Myers Squibb (Uxbridge, UK)	Moderate-to-severe plaque psoriasis	Phase II	Oral	TYK2 inhibitor	PASI75 53.6–58.7% (16 weeks), 59.3–69.0% (24 weeks) <sup>37,40</sup>	No opportunistic infections or thrombotic events  Most common complaints were nasopharyngitis (5.7–17.9%) and sinusitis (0–7.6%) <sup>37,40</sup>
BI 730357	Boehringer Ingelheim (Ingelheim am Rhein, Germany)	Moderate-to-severe plaque psoriasis	Phase II	Oral	Pyrazinone RORγ antagonist	No data available	No data available
EDP1815	Evelo Biosciences (Cambridge, Massachusetts, USA)	Mild-to-moderate plaque psoriasis	Phase II	Oral	Monoclonal strain of <i>Prevotella histicola</i>	EASI 62% treatment difference versus placebo <sup>54</sup>	No difference in incidence of diarrhoea, abdominal pain, nausea, or vomiting versus placebo  No related serious adverse events <sup>54</sup>
Medium THC/CBD	Brown University (Providence, Rhode Island, USA)	Psoriatic arthritis	Phase II	Oral	Cannabinoid receptor agonist or via anti-inflammatory cholinergic pathway	No data available	No data available



Table 2 continued.

Compound	Company	Indications	Development state	Route of administration	Mechanism of action	Efficacy	Adverse effects
Naltrexone	JPMC (Karachi, Pakistan)	Mild psoriasis	Phase I	Oral	$\mu$ -opioid antagonists	PASI score difference of 4.96 comparing same patient cohort before and after treatment at 12 weeks <sup>46,47</sup>	Mood and liver abnormalities (requiring monitoring) have been observed at higher doses <sup>46,47</sup>
CC-92252	Celgene (Uxbridge, UK)	Psoriasis	Phase I	Oral	IL-2 receptor agonist and regulatory T-lymphocyte stimulant	No data available	No data available

ACR20: American College of Rheumatology score with 20% improvement; ACR50: American College of Rheumatology score with 50% improvement; CBD: cannabidiol; EASI: Eczema Area and Severity Index; PASI75: Psoriasis Area and Severity Index with 75% improvement from baseline; PASI100: Psoriasis Area and Severity Index with 100% improvement from baseline; PD-1: programmed cell death-1; ROR $\gamma$ : retinoic acid receptor-related orphan receptor  $\gamma$ ; THC: tetrahydrocannabinol; TYK2: tyrosine kinase 2.

**Table 3: Clinical trial summaries and associated efficacy results.**

Identifier	Agents	Phase	Indication	Summary Points
NCT03536884 (BE RADIANT) <sup>25</sup>	Bimekizumab versus secukinumab	III	Moderate-to-severe plaque psoriasis	<p>At Week 4, 71.0% in the bimekizumab group (compared with 47.3% in the secukinumab group) had 75.0% or greater reduction from baseline in the PASI score (adjusted risk difference: 23.7; p&lt;0.001)</p> <p>At Week 16, PASI100 achieved by 61.7% in the bimekizumab group versus 48.9% in the secukinumab group. Bimekizumab was proved to be non-inferior, then superior secukinumab (p&lt;0.001 for each).</p> <p>After 48 weeks, PASI100 was achieved by 67.0% of those in the bimekizumab arm and 46.2% of those in the secukinumab arm (adjusted risk difference: 20.9 percentage points; p&lt;0.001)</p> <p>Oral candidiasis was more often associated with bimekizumab (19.3%) than with secukinumab (3.0%)</p>

**Table 3: Clinical trial summaries and associated efficacy results.**

Identifier	Agents	Phase	Indication	Summary Points
NCT03101670 (EQUATOR) <sup>82</sup>	Filgotinib (GLPG0634)	II	Moderate-to-severely active psoriatic arthritis	<p>At 16 weeks, 80.0% (52/65) patients in the filgotinib group achieved ACR20 compared with 33.0% (22/66) in the placebo group (p&lt;0.0001)</p> <p>During the open label extension portion of the study, following 52 weeks, 33.6% of patients achieved MDA response and 55.0% achieved ACR50</p>
NCT03624127 (POETYK PSO-1) <sup>38</sup>	Deucravacitinib versus apremilast	II	Moderate-to-severe plaque psoriasis	<p>Following 16 weeks of treatment, PASI75 was achieved in 58.7% of the deucravacitinib arm, 35.1% of the apremilast group, and 12.7% of the placebo group</p> <p>Following 24 weeks of treatment, PASI75 was achieved in 69.0% of the deucravacitinib arm compared with 38.1% of the apremilast arm</p> <p>Of the patients achieving PASI75 at 24 weeks, 82.5% of these maintained PASI75 response at 52 weeks</p>

Table 3 continued.

Identifier	Agents	Phase	Indication	Summary Points
NCT03611751 (POETYK PSO-2) <sup>39</sup>	Deucravacitinib versus apremilast versus placebo	II	Moderate-to-severe plaque psoriasis	<p>Following 16 weeks of treatment, PASI75 was achieved in 53.6% of the deucravacitinib arm, 40.2% of the apremilast arm, and 9.4% of the placebo group</p> <p>Following 24 weeks of treatment, PASI75 was achieved in 59.3% of the deucravacitinib arm compared with 37.8% of the apremilast arm</p> <p>Of the patients achieving PASI75 at 24 weeks, 81.4% of these maintained PASI75 response at 52 weeks</p>
NCT03733353 <sup>52</sup>	EDP1815 versus placebo	I	Atopic dermatitis, and patients with mild-to- moderate psoriasis	<p>Following 56-day treatment regimen, there was a 62% difference in EASI score in EDP1815 versus placebo (p=0.034) and 71% treatment difference in IGA*BSA (p=0.019)</p> <p>On Day 56, 10/16 patients showed improvements in EASI (with 3/10 achieving an EASI75 clinical response)</p> <p>In the psoriasis cohorts, EDP1815 limited the production of mediator inflammatory cytokines including 1L-6, IL-8, TNF, and IL-1</p>

Table 3 continued.

Identifier	Agents	Phase	Indication	Summary Points
NCT04250792 <sup>45</sup>	Naltrexone post-versus pre-treatment	I	Mild psoriasis	Following 12 weeks of low dose naltrexone therapy, PASI score difference of 4.96 (p<0.001), DLQI score difference of 6.32 (p<0.001), and a IGA*BSA score difference of 3.9 (p<0.001) compared with observations of the same group before treatment

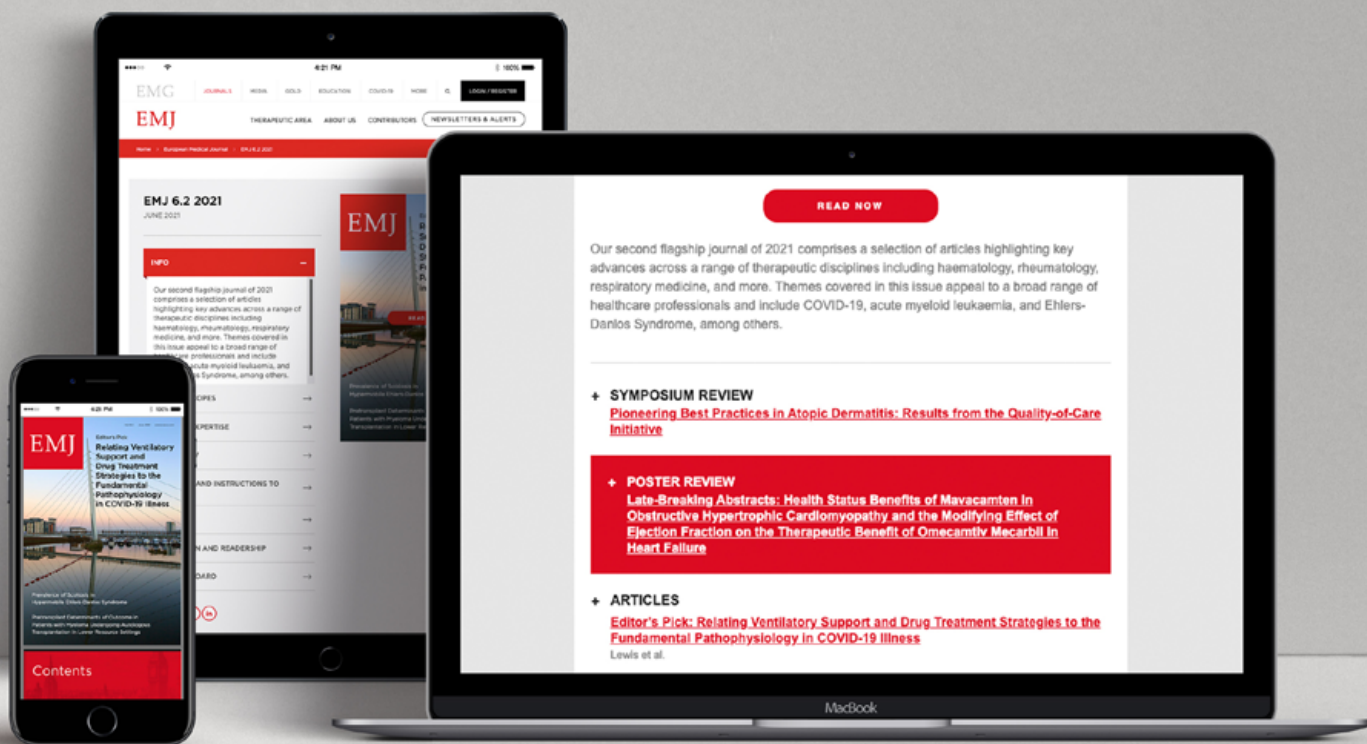
ACR20: American College of Rheumatology score with 20% improvement; ACR50: American College of Rheumatology score with 50% improvement; DLQI: Dermatology Life Quality Index; EASI: Eczema Area and Severity Index; IGA\*BSA: Investigator's Global Assessment and Body Surface Area; MDA: minimal disease activity; PASI75: Psoriasis Area and Severity Index with 75% improvement from baseline; PASI100: Psoriasis Area and Severity Index with 100% improvement from baseline.

## References

- Afonina IS et al. Immune responses and therapeutic options in psoriasis. *Cell Mol Life Sci.* 2021;78(6):2709-27.
- Rendon A, Schäkel K. Psoriasis pathogenesis and treatment. *Int J Mol Sci.* 2019;20(6):1475.
- Balogh EA et al. Emerging systemic drugs in the treatment of plaque psoriasis. *Expert Opin Emerg Drugs.* 2020;25(2):89-100.
- Bagel J, Gold LS. Combining topical psoriasis treatment to enhance systemic and phototherapy: a review of the literature. *J Drugs Dermatol.* 2017;16(12):1209-22.
- Armstrong AW, Read C. Pathophysiology, clinical presentation, and treatment of psoriasis: a review. *JAMA.* 2020;323(19):1945-60.
- Foerster J, Dawe R. Phototherapy achieves significant cost savings by the delay of drug-based treatment in psoriasis. *Photodermatol Photoimmunol Photomed.* 2020;36(2):90-6.
- Housman TS et al. Phototherapy utilization for psoriasis is declining in the United States. *J Am Acad Dermatol.* 2002;46(4):557-9.
- Ighani A et al. Comparison of management guidelines for moderate-to-severe plaque psoriasis: a review of phototherapy, systemic therapies, and biologic agents. *J Cutan Med Surg.* 2019;23(2):204-21.
- Menter A et al. Adalimumab therapy for moderate to severe psoriasis: a randomized, controlled Phase III trial. *J Am Acad Dermatol.* 2008;58(1):106-15.
- Menter A et al. A randomized comparison of continuous vs. intermittent infliximab maintenance regimens over 1 year in the treatment of moderate-to-severe plaque psoriasis. *J Am Acad Dermatol.* 2007;56(1):31.e1-15.
- Langley RG et al. Long-term efficacy and safety of ustekinumab, with and without dosing adjustment, in patients with moderate-to-severe psoriasis: results from the PHOENIX 2 study through 5 years of follow-up. *Br J Dermatol.* 2015;172(5):1371-83.
- Papp KA et al. Etanercept Psoriasis Study Group. A global Phase III

- randomized controlled trial of etanercept in psoriasis: safety, efficacy, and effect of dose reduction. *Br J Dermatol*. 2005;152(6):1304-12.
13. Kircik L et al.; Unite Study Group. Utilization of narrow-band ultraviolet light B therapy and etanercept for the treatment of psoriasis (UNITE): efficacy, safety, and patient-reported outcomes. *J Drugs Dermatol*. 2008;7(3):245-53.
  14. Menter A et al. Drug survival of biologic therapy in a large, disease-based registry of patients with psoriasis: results from the Psoriasis Longitudinal Assessment and Registry (PSOLAR). *J Eur Acad Dermatol Venereol*. 2016;30(7):1148-58.
  15. Gaspari AA, Tying S. New and emerging biologic therapies for moderate-to-severe plaque psoriasis: mechanistic rationales and recent clinical data for IL-17 and IL-23 inhibitors. *Dermatol Ther*. 2015;28(4):179-93.
  16. U.S. Food and Drug Administration (FDA). Biosimilar product information. Available at: <https://www.fda.gov/drugs/biosimilars/biosimilar-product-information>. Last Accessed: 7 May 2021.
  17. Sandoz. Study to demonstrate equivalent efficacy and to compare safety of biosimilar adalimumab (GP2017) and humira. NCT02016105. <https://ClinicalTrials.gov/show/NCT02016105>.
  18. Global News Wire. Adalimumab biosimilar landscape report provides an analysis. 2021. Available at: <https://www.globenewswire.com/news-release/2021/01/20/2161094/0/en/Adalimumab-Biosimilar-Landscape-Report-Provides-an-Analysis-of-35-Companies-along-with-Updated-45-Marketed-and-Pipeline-Drugs-DelveInsight.html>. Last accessed: 12 October 2021.
  19. Coherus BioSciences Inc. Coherus BLA filing for adalimumab biosimilar candidate accepted by FDA for review. 2021. Available at: <https://investors.coherus.com/news-releases/news-release-details/coherus-bla-filing-adalimumab-biosimilar-candidate-accepted-fda>. Last accessed: 7 May 2021.
  20. Bilal J et al. A systematic review and meta-analysis of the efficacy and safety of the interleukin (IL)-12/23 and IL-17 inhibitors ustekinumab, secukinumab, ixekizumab, brodalumab, guselkumab and tildrakizumab for the treatment of moderate to severe plaque psoriasis. *J Dermatolog Treat*. 2018;29(6):569-78.
  21. Armstrong AW et al. Comparative efficacy and relative ranking of biologics and oral therapies for moderate-to-severe plaque psoriasis: a network meta-analysis. *Dermatol Ther* (Heidelb). 2021;11(3):885-905.
  22. Kim WB et al. Diagnosis and management of psoriasis. *Can Fam Physician*. 2017;63(4):278-85.
  23. Cheng J, Feldman SR. The cost of biologics for psoriasis is increasing. *Drugs Context*. 2014;3:212266.
  24. Fleming WK. Pharmacy management strategies for improving drug adherence. *J Manag Care Pharm*. 2008;14(6 Suppl B):16-20.
  25. UCB Biopharma SR. A study to evaluate the safety and efficacy of bimekuzinab compared to an active comparator in adult subjects with moderate-to-severe chronic plaque psoriasis (BE RADIANT). NCT03536884. <https://clinicaltrials.gov/ct2/show/NCT03536884>.
  26. Reich K et al. Bimekizumab versus secukinumab in plaque psoriasis. *N Engl J Med*. 2021;385(2):142-52.
  27. Gordon KB et al. Bimekizumab efficacy and safety in moderate to severe plaque psoriasis (BE READY): a multicentre, double-blind, placebo-controlled, randomised withdrawal Phase 3 trial. *Lancet*. 2021;397(10273):475-86.
  28. Papp KA et al. Dual neutralization of both interleukin 17A and interleukin 17F with bimekizumab in patients with psoriasis: results from BE ABLE 1, a 12-week randomized, double-blinded, placebo-controlled Phase 2b trial. *J Am Acad Dermatol*. 2018;79(2):277-86.e10.
  29. Colgene. Study to evaluate the safety, tolerability, pharmacokinetics, pharmacodynamics, and immunogenicity of CC-90006 in subjects with mild to moderate plaque-type psoriasis. NCT03337022. <https://ClinicalTrials.gov/show/NCT03337022>.
  30. Grebinoski S, Vignali DA. Inhibitory receptor agonists: the future of autoimmune disease therapeutics? *Curr Opin Immunol*. 2020;67:1-9.
  31. Galapagos. Filgotinib. 2021. Available at: <https://www.glp.com/filgotinib>. Last accessed: 14 June 2021.
  32. Mease P et al. Efficacy and safety of filgotinib, a selective Janus kinase 1 inhibitor, in patients with active psoriatic arthritis (EQUATOR): results from a randomised, placebo-controlled, Phase 2 trial. *Lancet*. 2018;392(10162):2367-77.
  33. Gladman DD et al. FRI0339 Long-term efficacy of the oral selective janus kinase 1 inhibitor filgotinib in psoriatic arthritis: week 52 response patterns in individual patients from an open-label extension (OLE) study (EQUATOR2). *Ann Rheum Dis*. 2020;79:763.
  34. Gilead. New analyses of phase 2 EQUATOR clinical program support durable efficacy of filgotinib in psoriatic arthritis. 2020. Available at: <https://www.gilead.com/news-and-press/press-room/press-releases/2020/6/new-analyses-of-phase-2-equator-clinical-program-support-durable-efficacy-of-filgotinib-in-psoriatic-arthritis>. Last Accessed: 19 May 2020.
  35. Pfizer. A study to evaluate safety and efficacy of PF-06826647 for moderate to severe plaque psoriasis. NCT03895372. <https://ClinicalTrials.gov/show/NCT03895372>.
  36. Pfizer. A first in human study to evaluate safety, tolerability, and pharmacology of PF-06826647 in healthy subjects and subjects with plaque psoriasis. NCT03210961. <https://clinicaltrials.gov/ct2/show/NCT03210961>.
  37. Business Wire. Bristol Myers Squibb presents positive data from two pivotal phase 3 psoriasis studies demonstrating superiority of deucravacitinib compared to placebo and Otezla® (apremilast). 2021. Available at: <https://www.businesswire.com/news/home/20210423005134/en/Bristol-Myers-Squibb-Presents-Positive-Data-from-Two-Pivotal-Phase-3-Psoriasis-Studies-Demonstrating-Superiority-of-Deucravacitinib-Compared-to-Placebo-and-Otezla%C2%AE-apremilast>. Last accessed: 14 June 2021.
  38. Bristol-Myers Squibb. Effectiveness and safety of BMS-986165 compared to placebo and active comparator in participants with psoriasis (POETYK-PSO-1). NCT03624127. <https://clinicaltrials.gov/ct2/show/NCT03624127>.
  39. Bristol-Myers Squibb. An investigational study to evaluate experimental medication BMS-986165 compared to placebo and currently available treatment in participants with moderate-to-severe plaque psoriasis (POETYK-PSO-2). NCT03611751. <https://clinicaltrials.gov/ct2/show/NCT03611751>.
  40. Mease PJ et al. Efficacy and safety of deucravacitinib (BMS-986165), an oral, selective tyrosine kinase 2 inhibitor, in patients with active psoriatic arthritis: results from a Phase 2, randomized, double-blind, placebo-controlled trial. Abstract L03. ACR Convergence 2020, 5-9 November, 2020.
  41. Zhang Y et al. ROR nuclear receptors: structures, related diseases, and drug discovery. *Acta Pharmacol Sin*. 2015;36(1):71-87.
  42. Boehringer Ingelheim. A study to test how well patients with plaque psoriasis tolerate BI 730357 over a longer period and how effective it is. NCT03835481. <https://ClinicalTrials.gov/show/NCT03835481>.
  43. Boehringer Ingelheim. This study is done in patients with plaque psoriasis and tests how well they tolerate

- BI 730357 and how effective it is. NCT03635099. <https://ClinicalTrials.gov/show/NCT03635099>.
44. Celgene. A safety study of CC-92252 in healthy adult subjects and adult subjects with psoriasis. NCT03971825. <https://ClinicalTrials.gov/show/NCT03971825>.
  45. Jinnah Postgraduate Medical Centre (JPMC). Efficacy of low dose naltrexone in psoriasis. NCT04250792. <https://clinicaltrials.gov/ct2/show/NCT04250792>.
  46. Weinstock LB et al. Low-dose naltrexone therapy for psoriasis. *Int J Pharm Compd.* 2020;24(2):94-6.
  47. Lee B, Elston DM. The uses of naltrexone in dermatologic conditions. *J Am Acad Dermatol.* 2019;80(6):1746-52.
  48. Milando R, Friedman A. Cannabinoids: potential role in inflammatory and neoplastic skin diseases. *Am J Clin Dermatol.* 2019;20(2):167-80.
  49. Brown University. Impact of cannabis on pain and inflammation among patients with rheumatoid or psoriatic arthritis. NCT04269993. <https://ClinicalTrials.gov/show/NCT04269993>.
  50. Derakhshan N, Kazemi M. Cannabis for refractory psoriasis-high hopes for a novel treatment and a literature review. *Curr Clin Pharmacol.* 2016;11(2):146-7.
  51. Itano AC et al. 16003 Orally administered EDP1815, a monoclonal strain of *Prevotella histicola*, has potent systemic anti-inflammatory effects. *JAAD.* 2020;83(6):AB52.
  52. Evelo Biosciences, Inc. A Phase 2 study investigating the effect of EDP1815 in the treatment of mild to moderate plaque psoriasis. NCT04603027. <https://ClinicalTrials.gov/show/NCT04603027>.
  53. Evelo Biosciences Inc. A study of EDP1815 in healthy participants and participants with mild-to-moderate psoriasis and atopic dermatitis. NCT03733353. <https://clinicaltrials.gov/ct2/show/NCT03733353>.
  54. Global News Wire. Evelo Biosciences reports positive topline clinical data in phase 1b trial of EDP1815 in atopic dermatitis. 2020. Available at: <https://www.globenewswire.com/news-release/2020/12/09/2142090/0/en/Evelo-Biosciences-Reports-Positive-Topline-Clinical-Data-in-Phase-1b-Trial-of-EDP1815-in-Atopic-Dermatitis.html>. Last Accessed: 7 May 2021.
  55. Balkwill F. Tumour necrosis factor and cancer. *Nat Rev Cancer.* 2009;9(5):361-71.
  56. Dogra S, Khullar G. Tumor necrosis factor-alpha antagonists: side effects and their management. *Indian J Dermatol Venereol Leprol.* 2013;79 Suppl 7:S35-46.
  57. Blauvelt A et al. Efficacy and safety of guselkumab, an anti-interleukin-23 monoclonal antibody, compared with adalimumab for the continuous treatment of patients with moderate to severe psoriasis: results from the Phase III, double-blinded, placebo- and active comparator-controlled VOYAGE 1 trial. *J Am Acad Dermatol.* 2017;76(3):405-17.
  58. Ghazawi FM et al. A review of the efficacy and safety for biologic agents targeting IL-23 in treating psoriasis with the focus on tildrakizumab. *Front Med (Lausanne).* 2021;8:702776.
  59. Gordon KB et al. Efficacy and safety of risankizumab in moderate-to-severe plaque psoriasis (UltIMMa-1 and UltIMMa-2): results from two double-blind, randomised, placebo-controlled and ustekinumab-controlled Phase 3 trials. *Lancet.* 2018;392(10148):650-61.
  60. Loft ND et al. Adverse events with IL-17 and IL-23 inhibitors for psoriasis and psoriatic arthritis: a systematic review and meta-analysis of Phase III studies. *J Eur Acad Dermatol Venereol.* 2020;34(6):1151-60.
  61. Sbidian E et al. Systemic pharmacological treatments for chronic plaque psoriasis: a network meta-analysis. *Cochrane Database Syst Rev.* 2020;1(1):CD011535.
  62. Bolick NL et al. Management of plaque psoriasis: a review and comparison of IL-23 inhibitors. *EMJ Dermatol.* 2020;8(1):84-95.
  63. Wasilewska A et al. Interleukin-17 inhibitors. A new era in treatment of psoriasis and other skin diseases. *Postepy Dermatol Alergol.* 2016;33(4):247-52.
  64. Langley RG et al. Secukinumab in plaque psoriasis — results of two Phase 3 trials. *N Engl J Med.* 2014;371(4):326-38.
  65. Papp KA et al. Brodalumab, an anti-interleukin-17-receptor antibody for psoriasis. *N Engl J Med.* 2012;366(13):1181-9.
  66. Warren RB et al. Bimekizumab versus adalimumab in plaque psoriasis. *N Engl J Med.* 2020;385(2):130-41.
  67. Jadon DR et al. Applying precision medicine to unmet clinical needs in psoriatic disease. *Nat Rev Rheumatol.* 2020;16(11):609-27.
  68. Grajdeanu IA et al. Imaging techniques in the diagnosis and monitoring of psoriasis. *Exp Ther Med.* 2019;18(6):4974-80.
  69. Duan X et al. Inhibition of keratinocyte necroptosis mediated by RIPK1/RIPK3/MLKL provides a protective effect against psoriatic inflammation. *Cell Death Dis.* 2020;11(2):134.
  70. Wu Q et al. Pentraxin 3: a promising therapeutic target for autoimmune diseases. *Autoimmun Rev.* 2020;19(12):102584.
  71. Xiuli Y, Honglin W. miRNAs flowing up and down: the concerto of psoriasis. *Front Med (Lausanne).* 2021;8:646796.
  72. Sun S et al. Circulating CD14+HLA-DR-/low myeloid-derived suppressor cells as potential biomarkers for the identification of psoriasis TCM blood-heat syndrome and blood-stasis syndrome. *Evid Based Complement Alternat Med.* 2020;2020:4582459.
  73. Carroll CL et al. Better medication adherence results in greater improvement in severity of psoriasis. *Br J Dermatol.* 2004;151(4):895-7.
  74. Feldman SR et al. Patterns of medication utilization and costs associated with the use of etanercept, adalimumab, and ustekinumab in the management of moderate-to-severe psoriasis. *J Manag Care Spec Pharm.* 2015;21(3):201-9.
  75. Cao Z et al. Ustekinumab dosing, persistence, and discontinuation patterns in patients with moderate-to-severe psoriasis. *J Dermatolog Treat.* 2015;26(2):113-20.
  76. Baiano R et al. Psoriasis patients utilizing secukinumab, ixekizumab, or brodalumab – comparisons to prior biologic medication adherence levels, reasons for switching, and reported changes in disease symptoms. *Journal of Drug Assessment.* 2019;8(Suppl 1):3.
  77. Hambly R et al. Medication adherence among patients with psoriasis on traditional systemic and biologics treatment. *Br J Dermatol.* 2018;178(1):e46-8.
  78. Vangeli E et al. A systematic review of factors associated with non-adherence to treatment for immune-mediated inflammatory diseases. *Adv Ther.* 2015;32(11):983-1028.
  79. Murage MJ et al. Medication adherence and persistence in patients with rheumatoid arthritis, psoriasis, and psoriatic arthritis: a systematic literature review. *Patient Prefer Adherence.* 2018;12:1483-503.
  80. Svendsen MT et al. eHealth technologies as an intervention to improve adherence to topical antipsoriatics: a systematic review. *J Dermatolog Treat.* 2018;29(2):123-8.
  81. Wang W et al. Poor medication adherence in patients with psoriasis and a successful intervention. *J Dermatolog Treat.* 2019;30(6):525-8.
  82. Galapagos NV. A study to assess efficacy and safety of filgotinib in active psoriatic arthritis (EQUATOR). NCT03101670. <https://clinicaltrials.gov/ct2/show/NCT03101670>.



# Receive our free newsletters and alerts

Get the latest updates on all our upcoming journals and receive first-class insights into ground-breaking news and advancements in medicine across multiple therapeutic areas.

[Join our mailing list](#)

[WWW.EMJREVIEWS.COM](http://WWW.EMJREVIEWS.COM)

**EMJ**