

Imaging of Ovarian Cancer: From Early Detection to Post-treatment Relapse

Editor's Pick

Our Editor's Pick featured article focuses on ovarian cancer, where successful treatment often depends on early detection. In this review, Forstner provides a practical update on the role of imaging throughout every phase of the ovarian cancer disease course. This includes an analysis of the utilisation of sonography for cancer detection and characterisation, MRI as a complementary tool for indeterminate findings, and CT for ovarian cancer staging. The benefits of CT are also discussed in relation to selecting patients suitable for medical therapy and providing pivotal information for individualised treatment.



| | |
|--------------------|--|
| Authors: | *Rosemarie Forstner Paracelsus Medical University, Salzburg, Austria *Correspondence to r.forstner@salk.at |
| Disclosure: | The author has declared no conflicts of interest. |
| Received: | 12.04.21 |
| Accepted: | 25.08.21 |
| Keywords: | CT, imaging, MRI, ovarian cancer, ovarian cancer recurrence, sonography, treatment planning. |
| Citation: | EMJ Radiol. 2021; DOI/10.33590/emjradiol/21-00086. https://doi.org/10.33590/emjradiol/21-000861 . |

Abstract

Ovarian cancer refers to a multitude of different cancer types originating from or involving the ovaries. Although it ranks third in gynaecological cancers, it is among the deadliest cancers in females. The prognosis mainly depends on early detection, but the majority of cases are diagnosed at advanced stages. Exact tumour delineation is crucial for individualised therapy planning. This review will provide a practical update of the role of imaging in every phase throughout the course of this disease. The imaging technique of choice depends mainly on the clinical setting. Sonography remains the first-line imaging modality for cancer detection and is the most important for characterisation of adnexal masses. MRI is a valuable complementary imaging tool in sonographically indeterminate findings. For ovarian cancer staging, CT is considered an optimal imaging technique. CT renders all critical information for treatment stratification. It assists in surgery planning by displaying the load and the distribution of the disease and alerts to sites difficult to resect. It also renders critical information in selecting patients more suitable for medical therapy. In a females treated for ovarian cancer, imaging is only recommended when there is suspicion of recurrence, where CT and PET/CT are most commonly used to confirm relapse and provide pivotal information for individualised treatment.

Key Points

1. Ovarian cancer is among the most harmful cancers in females and is generally diagnosed at a late stage, when the prognosis is poor. Moreover, despite optimal therapy, the relapse rate of ovarian cancer is as high as 70–85%. Almost 25% of females will relapse within 6 months and in most cases the cancer will recur within 2 years after completion of therapy.
2. Imaging plays a pivotal role throughout the course of the disease: from the characterisation of adnexal masses to treatment planning, and confirmation of suspected ovarian cancer relapse.
3. Imaging gives crucial information for selecting candidates eligible for cytoreductive surgery. In this case, PET/CT is useful to demonstrate small or distant metastases. It is also optimally combined with MRI as it provides the single best modality for local surgery planning.

INTRODUCTION

Currently, ovarian cancer is recognised not as a single entity but as an umbrella term that refers to different malignancies arising from or involving the ovaries.¹ The vast majority (85–90%) of ovarian cancers constitute of epithelial ovarian cancers (EOC) that mostly affect females who are peri- and post-menopausal age. Recent advances in molecular and genetic analysis distinguish between five major histopathological subtypes of EOC, which differ not only in terms of origin, precursor lesions, prognosis, and molecular characteristics but also in emerging therapeutic implications.^{2,3}

In fact, it is well established that premalignant precursors of high-grade EOCs, the most common type of ovarian cancer, and *BRCA*-associated cancers are arising not in the ovaries but in the distal fallopian tube.¹

Although in the past four decades there has been an improvement in the 10-year survival rates from 18–35%, ovarian cancer is still among the deadliest cancers in females.⁴ This is mostly due to the fact that ovarian cancer is diagnosed at an advanced stage, when prognosis is poor, and, despite optimal initial treatment, it takes a fatal course characterised by serial relapses. Conversely, detection of ovarian cancer at an early stage or, ideally, of precursor lesions is associated with an excellent prognosis.

Imaging plays a pivotal role in females with ovarian cancer throughout the course of their

disease: for the characterisation of adnexal masses, treatment planning of ovarian cancer, and confirmation of suspected ovarian cancer relapse. From the beginning, disease imaging renders pivotal information for individualised tailored treatment.⁵ The selection of the appropriate imaging technique depends on various factors, but mostly on the clinical scenario. This review will focus on the value of the different imaging modalities used in assessing ovarian cancer.

EARLY DETECTION OF OVARIAN CANCER

Screening

Due to the lack of or only vague clinical symptoms, the vast majority of ovarian cancer is diagnosed at a late stage, when the prognosis is poor. The clinical impact of diagnosing invasive ovarian cancer or precursors such as borderline tumours early would be enormous.⁶ Early detection is the only way to achieve a high survival rate in females with ovarian cancer. Stage I ovarian cancer has an excellent 5-year survival rate of more than 90%.⁷ A recent comprehensive analysis of subtypes extracted from 28,118 ovarian cancers of the Surveillance, Epidemiology, and End Results (SEER) Program database showed that 39.2% of EOCs are diagnosed in Stages I and II. Of note, these tend to present the more indolent Type I ovarian cancers. In contrast, Type II (high-grade cancers and carcinosarcomas) tumours accounted for the vast majority of advanced stage cancers

and were associated with a poor outcome independent of the stage.⁸

Unfortunately, there are no existing, effective strategies for screening ovarian cancer using imaging, rapidly emerging biomarkers, or a combination.⁹ At present, screening for females with a normal-risk of ovarian cancer is not recommended.⁹ Data from large screening programmes failed to show a survival benefit of females who were screened compared with females who were not screened.^{10,11} The rate of detected ovarian cancers was low, the performance in detecting Stage I disease was limited, and harms related to false positive testing were seen.

However, in females who are at high-risk of ovarian cancers due to *BRCA* mutations, a family history of ovarian cancer, or Lynch syndrome, semi-annual screening is recommended. Such a predisposition is estimated to occur in 10–15% of ovarian cancers. Carriers of the *BRCA* mutation have an increased life-time risk of ovarian cancer. It is estimated that carriers of the *BRCA1* and *BRCA2* mutations have an increased life-risk of 40–45% and 15–20%, respectively, by age 70.^{6,9} These females also tend to develop ovarian cancer in younger ages, but ovarian cancer is rarely found under the age of 40.⁹ In this population, transvaginal ultrasonography is generally accepted as the optimal imaging test for screening for ovarian cancer. Due to its high specificity, MRI can be offered for further characterisation of sonographically indeterminate masses. Thus, it may assist in reducing the number of surgical interventions if physiological ovarian masses or uterine fibroids are detected.¹² Current evidence supports that prophylactic salpingo-oophorectomy reduces the ovarian cancer risk. It is recommended in the high-risk population, aged 35–40, or after the completion of childbearing.⁹

Prediction of Malignancy in Adnexal Masses

The accurate characterisation of an adnexal mass is essential for appropriate patient management.¹³ Likely benign lesions can be managed conservatively or by laparoscopic surgery, whereas females with malignant lesions will benefit from treatment by gynaecological oncologists or in cancer centres.^{12,14}

Advanced ovarian cancer usually requires radical cytoreductive surgery, followed by chemotherapy, or, alternatively, neoadjuvant chemotherapy, followed by interval debulking.^{15,16}

Several imaging-based models for preoperatively assessing the risk of malignancy of an adnexal mass have been developed. These include the pattern recognition approach, e.g., the commonly used International Ovarian Tumour Analysis (IOTA) simple ultrasound (US) rules or other mathematical models developed by the IOTA, Risk of Malignancy Index (RMI), the Gynaecologic Imaging Report and Data System (GI-RADS), and the recently published Ovarian-Adnexal Reporting and Data System (O-RADS) risk stratification system.

Transvaginal sonography, combined with Doppler techniques, remains the mainstay for assessing adnexal masses. Due to its clinical utility and cost effectiveness, it has been established as the first-line imaging modality.¹⁷ It performs excellently in evaluating cystic adnexal lesions, which constitute the vast majority of adnexal masses. However, MRI is generally considered as a second-line, problem-solving modality and is particularly useful in complex or solid adnexal masses and when the clinical likelihood of malignancy is low.¹² A systematic review demonstrated that the major advent of MRI is its high specificity to provide a confident diagnosis of benign adnexal lesions.¹⁸

Pattern recognition analysis, the gold standard for analysing an adnexal mass, is highly dependent on the level of expertise. Transvaginal sonography yields sensitivities of 85% and specificities of 90%, which might be even higher if they were performed in expert centres.^{19,20} The value of grey scale and colour Doppler US has been extensively analysed by the IOTA. Subjective assessment by highly trained clinicians in US performed equivalently to mathematical models such as the IOTA-simple rules models and logistic regression models.²¹ The combination of imaging techniques, usually with US, clinical features, and cancer antigen-125 (CA-125) levels is the basis of scoring in the RMI.

Recently, the O-RADS scoring and management system was introduced.^{13,22} This 5-point risk classification system for ovarian or adnexal masses was developed in close co-operation

for US and MRI by the American College of Radiology (ACR) O-RADS Committee. A standardised imaging technique and terminology should be used for risk categorisation at initial diagnosis, as well as for the follow-up. In the US O-RADS score, ovarian masses are categorised based on their morphology and Doppler assessment. Incomplete evaluation (Score 0) and physiological ovarian follicles (score 1) are separated from almost certainly benign (Score 2: <1%) masses, low risk of malignancy (Score 3: 1–<10%), intermediate risk (Score 4: 10–<50%), and high risk (Score 5: >50%) masses.²²

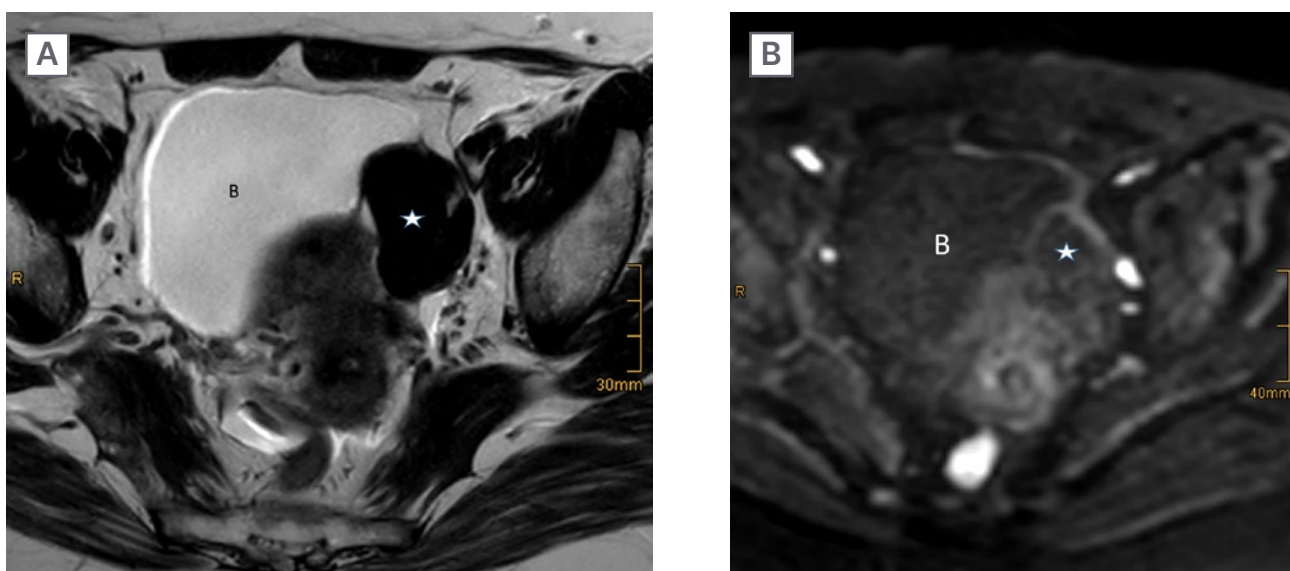
US and MRI O-RADS were implemented to provide a standardised risk stratification system for ovarian and adnexal masses, which should serve as a consistent basis for analysis and reporting.^{13,22} O-RADS scoring should only be used in average-risk patients with no acute symptoms. It is also aimed at providing a guidance for management of adnexal masses in clinical practice. The integration of the risk score in the reports is ultimately intended to improve communication with referring clinicians by eliminating uncertainties in term usage and to assist in clinical decision making.¹³

However, clinical management directed by the treating physician supersedes management recommendations, based on imaging alone.¹³

Even in the hands of experts, 5–22% of adnexal masses will remain sonographically indeterminate or difficult to classify.²³ Such masses typically exhibit the following sonographic features: large size, uni- or multi-locular, with solid aspects, irregular walls, papillary projections, and multilocular cysts. The vast majority of these lesions are benign tumours at histopathology, mostly cystadenomas, cystadenofibromas, and fibromas.^{23–25}

To date, MRI is usually performed as a complementary imaging tool to further characterise adnexal masses that are indeterminate on US (Figure 1).¹² The European Society of Urogenital Radiology (ESUR) guidelines recommend an algorithmic approach using basic and problem-solving sequences that will allow a confident diagnosis in the majority of cases, and thus assist in stratifying patients to the most appropriate treatment.¹² Thomassin et al. introduced a 5-point risk score that combined morphologic pattern analysis, diffusion-weighted

Figure 1: Left ovarian thecoma in a 55-year-old-female.



Sonography showed an indeterminate solid mass. A solid tumour (asterisk) is shown as separate from the uterus and adjacent to the bladder (B). MRI showed typical features of a benign tumour with low signal intensity on T2WI (A) and DWI (B) using a high b-value.

DWI diffusion-weighted imaging; T2WI: T2 weighted image.

Table 1: Magnetic resonance Ovarian-Adnexal Reporting and Data System™ Scoring classification system*.

| O-RADS MRI score | Risk category | PPV for malignancy (%) |
|------------------|-------------------------|------------------------|
| 0 | Incomplete evaluation | N/A |
| 1 | Normal ovaries | N/A |
| 2 | Almost certainly benign | <0.5 |
| 3 | Low risk | Approx. 5 |
| 4 | Intermediate risk | Approx. 50 |
| 5 | High Risk | Approx. 90 |

The PPV values for malignancy include both borderline tumours and invasive cancers.

*Adapted from Reinhold C et al.¹³

†Approximate PPV based on data from Thomassin-Naggara I et al.²⁷

Approx: approximately; PPV: positive predictive value; O-RADS: Ovarian-Adnexal Reporting and Data System.

imaging, and perfusion analysis of solid tissue within an adnexal mass using time intensity curves.^{26,27} Recently, this MRI O-RADS score has been validated in a large European multicentre study. The results demonstrate a robust score, with sensitivities of 93% and specificities of 91%, for detecting malignant lesions in sonographically indeterminate masses, regardless of the level of radiological expertise.^{6,27} Data from this study also provided the evidence for the MRI O-RADS risk stratification scoring system (Table 1).

IMAGING FOR TREATMENT PLANNING IN OVARIAN CANCER

Traditionally, newly diagnosed ovarian cancer is surgically staged according to the International Federation of Gynaecology and Obstetrics (FIGO) or Tumour, Nodes, Metastases (TNM) staging classification. The 2014 updated FIGO system provides not only tumour stage categorisation but also incorporates information of the histological subtype and grade.²⁸

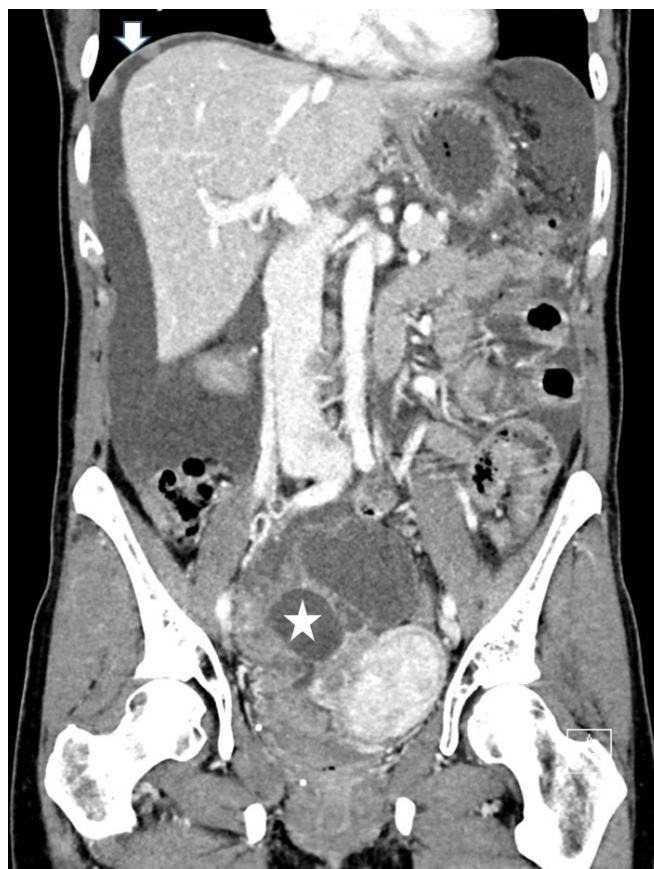Staging is usually performed during a staging laparotomy, including upfront cytoreductive surgery and is followed in most cases by taxane- and platinum based chemotherapy.¹⁶ It has been

established that cytoreduction to a cut off of 1 cm (optimal cytoreduction) is associated with increased survival in ovarian cancer.²⁹ However, a trend towards ultraradical surgery, with complete resection of all gross tumour deposits, can be noted.³⁰ The reported rates of optimal cytoreduction vary broadly from 15–85%, with high-volume oncologic centres achieving rates of optimal cytoreduction of up to 60–75%.^{31,32}

The optimal treatment for the advanced cancer Stages IIIC and IV has long been a subject of debate.^{16,30} Recent data support that in advanced ovarian cancer, neoadjuvant chemotherapy renders equivalent survival outcomes but lacks the issue of high perioperative complications of ultraradical surgeries.^{16,30}

CT has been established as an important tool not only for preoperative staging of ovarian cancer but also for providing pivotal information for management decisions.⁵ It is the mainstay of ascertaining the extent of the disease and exact depiction of distribution of the metastatic dissemination. It may also alert to sites that might be difficult to completely resect and where a multidisciplinary approach during surgery may be appropriate.³³ Thus, it provides pivotal information for selecting between patients

Figure 2: CT of advanced ovarian cancer.



Staging CT demonstrates a large solid and cystic pelvic mass (asterisk) adjacent to the uterus. Large amounts of ascites are seen, as well as peritoneal implants at the dome of the right diaphragm (arrow).

suitable for upfront cytoreductive surgery and those more likely to benefit from medical therapy prior to surgery, e.g., due to extreme tumour load or in patients unfit for surgery.³⁴ When neoadjuvant chemotherapy is planned, an image-guided biopsy can be offered to confirm the diagnosis of disseminating ovarian cancer and to identify the histological subtype.³³

Dissemination via the peritoneal cavity beyond the pelvis is typical for ovarian cancer and is found in more than 60% of females at diagnosis (Figure 2). The vast majority of these will present with high grade EOC. Solid or more diffuse peritoneal deposits are commonly found in the omentum, diaphragm, liver or spleen surface, the bowel, mesentery, and along peritoneal reflections. Perihepatic metastases (Stage III) present as a typical liver manifestation in newly diagnosed ovarian cancer. They usually present

scalloping lesions with smooth margins along the liver surface but may sometimes invade the liver surface.³⁵

Structured reporting of CT in ovarian cancer is a powerful tool of providing crucial information for therapy decisions in multidisciplinary meetings. The ESUR guidelines suggest not only defining the stage according to the FIGO or TNM classification but strongly recommend a management-driven, structured report that includes comprehensive information of the primary tumour, including the tumour burden and sites of the metastatic disease, as well as other information relevant for treatment planning.³³ Potentially difficult to resect disease (not optimally resectable) should also be highlighted in the report. Although the clinical practice varies, these include tumour deposits of >2 cm in size in the root of the mesentery, gastrosplenic

ligament, lesser sac, porta hepatis and falciform ligament, and suprarenal or supradiaphragmatic lymphadenopathy.³⁴ Various tests have been developed to predict the likelihood of optimal cytoresection.^{31,32,36} Major determinants include clinical risk factors, CA-125 levels, and imaging tests, most commonly using CT. However, the clinical utility of such standardised prediction of resectability could not be proven.^{24,31,32}

To date, preoperative staging of ovarian cancer remains a CT domain. It is widely available, reproducible, and provides all relevant information for staging in a short examination time.³³ The reported accuracy for all stages ranges from 70–90%, with an overall sensitivity in detection of peritoneal implants of 85–93%.^{34,47} Limitations, however, include small volume peritoneal disease (<5 mm) and sites such as the bowel surface and the mesentery. PET/CT is not routinely used for initial staging of ovarian cancer but may be useful as an adjunct test to inconclusive CT findings or in case of contraindications for contrast media.^{33,38} Although MRI performs similarly for staging and is superior to CT in the visualisation of small peritoneal implants, it is still regarded as a second-line imaging modality.^{33,38} Apart from costs, this is mainly attributed to technical issues and a much longer examination time. MRI is recommended when radiation exposure or its superior soft tissue contrast capability is an issue, e.g., in pregnancy or in young females presenting with presumed borderline tumours and if fertility preservation is considered.³⁸ Similarly, the role of fluorodeoxyglucose-PET/CT remains that of a problem solving imaging test, that is particularly useful in advanced ovarian cancer or as an alternative to contraindications of contrast-enhanced CT. Whole body MRI has shown excellent results and performs comparably to PET/CT for assessing metastatic disease within and outside the abdominal cavity.³⁹ As this imaging technique is emerging from research to clinical application, it may become a central management tool in newly diagnosed ovarian cancer.

PREDICTION OF TUMOUR RESPONSE IN OVARIAN CANCER

Neoadjuvant chemotherapy prior to cytoreductive surgery is a treatment option

in selected patients with advanced EOC. Clinical, routine serial CA-125 assessments and CT serve as the mainstay for response assessment during this therapy. CT is usually performed as a baseline study and after 3 cycles of chemotherapy to determine eligibility for cytoreductive surgery. Alternatively, in insufficient response medical treatment is continued.

Assessment of the change in tumour load is a critical feature in patients undergoing clinical trials. Here, response has traditionally been assessed by serial CA-125 monitoring and standardised quantification of the tumour using Response Evaluation Criteria in Solid Tumours (RECIST), mostly in CT. In ovarian cancer, however, application of the RECIST criteria is challenging due to the diffuse peritoneal spread in most cases of EOC and the problem of defining target lesions.⁴⁰

A recent, large multicentre study conducted in patients undergoing neoadjuvant chemotherapy showed that response criteria using only CA-125 or RECIST were limited to predict optimal cytoreduction.⁴¹

CA-125 is the currently best-established biomarker in ovarian cancer. However, a multitude of potential novel biomarkers are under investigation. Moving forward to individualised treatment of ovarian cancer, research activities include comprehensive molecular profiling of tissue biopsies and of tumour DNA circulating in the blood (liquid biopsies).

Prediction of tumour response prior to therapy is also an area of ongoing research, utilising the functional imaging techniques of PET/CT and MRI.⁴⁰ In one study, apparent diffusion coefficient quantification obtained by diffusion-weighted MRI showed differences between the primary tumour and peritoneal metastases, reflecting inter-site tumour heterogeneity and potentially resulting in different biological effects.⁴²

Radiomics and radiogenomics data render information beyond the morphological tumour manifestations. Radiomic signature of the primary tumour and deposits based on preoperative CT may provide information as a prognostic imaging biomarker in high-grade

ovarian cancer.⁴³ The role of both intra- and inter-site heterogeneity in ovarian cancer has been addressed by Vargas et al., who showed that CT radiomic features of tumour heterogeneity were associated with a poorer outcome and incomplete surgical resection.⁴⁴ In the future, the combination of radiomic features and clinical data may allow for the development of predictive models of resectability or of tumour progression.⁴⁵

IMAGING OF THE TREATED OVARIAN CANCER

Despite optimal therapy, the relapse rate of ovarian cancer is as high as 70–85%.⁴⁵ Almost 25% of females will relapse within 6 months and, in the majority, the cancer will recur within 2 years after completion of therapy.⁴⁶ In advanced ovarian cancer, the 5-year overall survival rate differs across the different subtypes of EOC.⁴⁷

When ovarian cancer has relapsed, it is a treatable but rarely curable disease. In general, relapse introduces a chronic and consecutively lethal stage of the disease, with reported survival rates ranging from 12–32 months.⁴⁸ Survival after the relapse is related to several factors including chemosensitivity, the time of progression-free interval after therapy, and the number of recurrent lesions. The standard of care for recurrent ovarian cancer is systemic platinum-based chemotherapy or subsequent line therapies. Secondary cytoreductive surgery is not routine but may be performed in selective patients.⁴⁸ This individualised approach depends on the size and site of the recurrent disease and is usually based upon a multidisciplinary conference decision.⁴⁹ Cytoreductive surgery for relapsed ovarian cancer is mostly performed in the localised disease at its first recurrence or after a long disease free-interval.^{49,50} Patients with a prolonged platinum-free interval (>6 months) and those with an isolated or limited volume of disease and a positive Arbeitsgruppe Gynäkologische Onkologie (AGO) score are likely to benefit from secondary surgery compared with those with a shorter progression-free interval or large volume disease.⁵⁰

Although there is lack of evidence that routine imaging after completion of primary therapy improves survival in ovarian cancer, in clinical practice CT is commonly used for surveillance in females in clinical remission.⁵¹ Major gynaecological guidelines, however, advise against routine imaging in a patient treated for ovarian cancer.^{48,49,51} Surveillance is recommended by clinical assessment and CA-125 monitoring for 3–4 months in the first 2 years and in a 6 months interval for Years 3–5. Imaging in a female treated for ovarian cancer is only recommended if recurrence is suspected, e.g., in rising CA-125 levels or in clinical symptoms suspicious of relapse.⁴⁸

Ovarian cancer usually relapses in the abdomen or the pelvis, with recurrence found in the surgical bed in up to 50% of patients.⁵² Peritoneal carcinomatosis is the typical manifestation of metastases and is seen in approximately 75% of cases.⁵³ Less common manifestations of metastases in treated ovarian cancer are the lymph nodes, lungs, pleura, and liver parenchyma.^{52,53} Unusual and rare types of recurrence including isolated distant, central nervous system manifestations, bone, skin, or soft tissue metastases tend to occur late in the disease.⁵⁴

CT has been widely used for assessing suspected recurrence in patients treated for ovarian cancer. Complementary PET/CT is mostly performed in patients with unremarkable or equivocal CT findings but rising tumour markers. A systematic review reported that contrast-enhanced PET/CT has a pooled sensitivity and specificity of 93.94% and 93.80%, respectively, for detecting recurrent disease.⁵⁵ Apart from whole body assessment, advantages of PET/CT include the depiction of small size metastases or metastases at sites difficult to assess with CT, e.g., of the bowel surface, mesentery, or subtle lymphadenopathy. However, microscopic peritoneal recurrence or lymph node metastases with a diameter of less than 5 mm are also beyond the detection of fluorodeoxyglucose-PET/CT.⁵⁶

In patients treated for ovarian cancer, imaging renders pivotal information for tailored treatment planning in multidisciplinary boards. It ascertains the presence of suspected recurrence and demonstrates their site and tumour load. It also

provides other important information such as potential complications of treatment.⁵³ Imaging also renders crucial information for selecting candidates eligible for cytoreductive surgery. In these patients, distant metastases as well as irresectable local disease have to be excluded. In this scenario PET/CT is superior to CT to demonstrate small or distant metastases.⁵⁷

It is optimally combined with MRI, as this presents the single best modality for local surgery planning, e.g., the pelvic sidewalls or other important structures.⁵ Advances in the management of ovarian cancer recurrence are to be expected when PET/MRI will become more widely available in clinical practice.

References

- Kim J et al. Cell origins of high-grade serous ovarian cancer. *Cancers (Basel)*. 2018;10(11):433.
- Höhn AK et al. [New FIGO classification of ovarian, fallopian tube and primary peritoneal cancer]. *Pathologe*. 2014; 35(4):322-6. (In German).
- Prat J. Ovarian carcinomas: five distinct diseases with different origins, genetic alterations, and clinicopathological features. *Virchows Arch*. 2012; 460(3):237-49.
4. Cancer Research UK. Ovarian cancer statistics for UK. 2020. Available at: <https://www.cancerresearchuk.org/health-professional/cancer-statistics/statistics-by-cancer-type/ovarian-cancer/survival>. Last accessed: 20 September 2021.
- Sala E et al. The added role of MR imaging in treatment stratification of patients with gynaecologic malignancies: what the radiologists needs to know. *Radiology*. 2013;266(3):717-40.
- Forstner R. Early detection of ovarian cancer. *Eur Radiol*. 2020;30(10):5370-73.
- American Cancer Society (ACS). Survival rates for ovarian cancer. 2021. Available at: <https://www.cancer.org/cancer/ovarian-cancer/detection-diagnosis-staging/survival-rates>. Last accessed: 20 September 2021.
- Peres LC et al. Invasive epithelial ovarian cancer survival by histotype and disease stage. *J Natl Cancer Inst*. 2019;111(1):60-8.
- Carlson KJ. Screening for ovarian cancer. 2021. Available at: <https://www.uptodate.com/contents/screening-for-ovarian-cancer#H26>. Error! Hyperlink reference not valid.. Last accessed: 20 September 2021.
- Buys SS et al. Effect of screening on ovarian cancer mortality: the prostate, lung, colorectal and ovarian (PLCO) cancer screening randomized controlled trial. *JAMA*. 2011;305(22):2295-303.
- Menon U et al. Sensitivity and specificity of multimodal and ultrasound screening for ovarian cancer, and stage distribution of detected cancers: results of the prevalence screen of the UK Collaborative Trial of Ovarian Cancer Screening (UKCTOCS). *Lancet Oncol*. 2009;10(4):327-40.
- Forstner R et al. ESUR recommendations for MR imaging of the sonographically indeterminate adnexal mass: an update. *Eur Radiol*. 2017;27(6):2248-57.
- Reinhold C et al. Ovarian-adnexal reporting lexicon for MRI: a white paper of the ACR Ovarian-Adnexal Reporting and Data Systems MRI committee. *J Am Coll Radiol*. 2021;18(5):713-29.
- Vernooij F et al. The outcomes of ovarian cancer treatment are better when provided by gynecologic oncologists and in specialized hospitals: a systematic review. *Gynecol Oncol*. 2007;105(3):801-12.
- Vergote I et al. Neoadjuvant chemotherapy in advanced ovarian cancer: on what do we agree and disagree? *Gynecol Oncol*. 2013;128(1):6-11.
- Ledermann JA. First-line treatment of ovarian cancer: questions and controversies to address. *Ther Adv Med Oncol*. 2018; DOI:10.1177/1758835918768232.
- Koirala P et al. Clinical utility of preoperative assessment in ovarian cancer cytoreduction. *Diagnostics*. 2020;10(8):568.
- Anthoulakis C, Nikouloudis N. Pelvic MRI as the "gold standard" in the subsequent evaluation of ultrasound- indeterminate adnexal lesions: a systematic review. *Gynecol Oncol*. 2014;132(3):661-8.
- Valentin L et al. Comparison of 'pattern recognition' and logistic regression models for discrimination between benign and malignant pelvic masses: a prospective cross validation. *Ultrasound Obstet Gynecol*. 2001;18(4):357-65.
- Timmerman D et al. Subjective assessment of adnexal masses with the use of ultrasonography: an analysis of interobserver variability and experience. *Ultrasound Obstet Gynecol*. 1999;13(1):11-6.
- Meys EMJ et al. Subjective assessment versus ultrasound models to diagnose ovarian cancer: a systematic review and meta-analysis. *Eur J Cancer*. 2016;58:17-29.
- Andreotti RF et al. O-RADS US risk stratification and management system: a consensus guideline from the ACR ovarian-adnexal reporting and data system committee. *Radiology*. 2020;294(1):168-85.
- Van Calster B et al. Evaluating the risk of ovarian cancer before surgery using the ADNEX model to differentiate between benign, borderline, early and advanced stage invasive, and secondary metastatic tumours: prospective multicentre diagnostic study. *BMJ*. 2014;349:g5920.
- Forstner R et al. Update on imaging of ovarian cancer. *Curr Radiol Rep*. 2016;4:31.
- Kaijser J et al. Presurgical diagnosis of adnexal tumours using mathematical models and scoring systems: a systematic review and meta-analysis. *Hum Reprod Update*. 2014;20(3):449-62.
- Thomassin-Naggara I et al. Characterization of complex adnexal masses: value of adding diffusion and perfusion MRI to conventional MR imaging. *Radiology*. 2011;258(3):793-803.
27. Thomassin-Naggara I et al. Ovarian-Adnexal Reporting and Data System Magnetic Resonance Imaging (O-RADS MRI) score for risk stratification

- of sonographically indeterminate adnexal masses. *JAMA Netw Open*. 2020;3(1):e1919896.
28. Prat J; FIGO Committee on Gynecologic Oncology. Staging classification for cancer of the ovary, fallopian tube, and peritoneum. *Int J Gynaecol Obstet*. 2014;124(1):1-5.
 29. Du Bois A et al. Role of surgical outcome as prognostic factor in advanced epithelial ovarian cancer: a combined exploratory analysis of 3 prospectively randomized phase 3 multicenter trials: by the Arbeitsgemeinschaft Gynaekologische Onkologie Studiengruppe Ovarialkarzinom (AGO-OVAR) and the Groupe d'Investigateurs Nationaux Pour les Etudes des Cancers de l'Ovaire (GINECO). *Cancer*. 2009;115(6):1234-44.
 30. Chang SJ et al. Role of aggressive surgical cytoreduction in advanced ovarian cancer. *J Gynecol Oncol*. 2015;26(4):336-42.
 31. Suidan RS et al. A multicenter prospective trial evaluating the ability of preoperative computed tomography scan and serum CA-125 to predict suboptimal cytoreduction at primary debulking surgery for advanced ovarian, fallopian tube, and peritoneal cancer. *Gynecol Oncol*. 2014;134(3):455-61.
 32. Borley J et al. Radiological predictors of cytoreductive outcomes in patients with advanced ovarian cancer. *BJOG*. 2015;122(6):843-49.
 33. Forstner R et al.; European Society of Urogenital Radiology. ESUR guidelines: ovarian cancer staging and follow-up. *Eur Radiol*. 2010; 20(12):2773-80.
 34. Sahdev A. CT in ovarian cancer staging: how to review and report with emphasis on abdominal and pelvic disease for surgical planning. *Cancer Imaging*. 2016;16(1):19.
 35. Nougaret S et al. Ovarian carcinomatosis: how the radiologist can help plan the surgical approach. *Radiographics*. 2012;32(6):1775-800.
 36. Aletti GD et al. A new frontier of quality of care in gynecologic oncology surgery: multi-institutional assessment of short term-outcomes for ovarian cancer using a risk adjusted model. *Gynecol Oncol*. 2007;107(1):99-106.
 37. Tempany CM et al. Staging of advanced ovarian cancer: comparison of imaging modalities—report from the Radiological Diagnostic Oncology Group. *Radiology*. 2000;215(3):761-7.
 38. Kang SK et al; Expert Panel on Women's Imaging. ACR Appropriateness Criteria® staging and follow-up of ovarian cancer. *J Am Coll Radiol*. 2018;15(5):S198-207.
 39. Michielsen K et al. Whole-body MRI with diffusion-weighted sequence for staging of patients with suspected ovarian cancer: a clinical feasibility study in comparison to CT and FDG-PET/CT. *Eur Radiol*. 2014;24(4):889-901.
 40. Rockall et al. New ways of assessing ovarian cancer response: metabolic imaging and beyond. *Cancer Imaging*. 2012;12(2):310-4.
 41. Morgan RD et al. Objective responses to first-line neoadjuvant carboplatin-paclitaxel regimens for ovarian, fallopian tube, or primary peritoneal carcinoma (ICON8): post-hoc exploratory analysis of a randomised, phase 3 trial. *Lancet Oncol*. 2021;22(2):277-88.
 42. Sala E et al. Advanced ovarian cancer: multiparametric MR imaging demonstrates response- and metastasis-specific effects. *Radiology* 2012;263(1):149-59.
 43. Wei W et al. A computed tomography-based radiomic prognostic marker of advanced high-grade serous ovarian cancer recurrence: a multicenter study. *Front Onco*. 2019;9:255.
 44. Vargas HA et al. Radiogenomics of high-grade serous ovarian cancer: multireader multi-institutional study from the cancer genome atlas ovarian cancer imaging research group. *Radiology*. 2017;285(2):482-92.
 45. Rizzo S et al. Radiomics of high grade serous ovarian cancer: association between quantitative CT features, residual tumour and disease progression within 12 months. *Eur Radiol* 2018;28(11):4849-59.
 46. Ozols RF et al. Phase III trial of carboplatin and paclitaxel compared with cisplatin and paclitaxel in patients with optimally resected stage III ovarian cancer: a Gynecologic Oncology Group study. *J Clin Oncol*. 2003;21(17):3194-200.
 47. Pignata S et al. Treatment of recurrent ovarian cancer. *Ann Oncol*. 2017;28(Suppl 8):viii51-6.
 48. Zhou J et al. The effect of histological subtypes on outcomes of stage IV epithelial ovarian cancer. *Font Oncol*. 2018;8:577.
 49. Colombo et al.; ESMO-ESGO ovarian cancer consensus conference working group. ESMO-ESGO consensus conference recommendations on ovarian cancer: pathology and molecular biology, early and advanced stages, borderline tumours and recurrent disease. *Ann Oncol*. 2019;30(5):672-705.
 50. Chi DS, Skih KS. Cancer of the ovary, fallopian tube, and peritoneum: surgical options for recurrence. Available at: <https://www.uptodate.com/contents/cancer-of-the-ovary-fallopian-tube-and-peritoneum-surgical-options-for-recurrent-cancer>. Last accessed: 20 September 2021.
 51. Coleman RL et al. Secondary surgical cytoreduction for recurrent ovarian cancer. *N Engl J Med*. 2019;381(20):1929-39.
 52. Esselen KM et al. Use of CA-125 tests and CT scans for surveillance in ovarian cancer. *JAMA Oncol*. 2016;2(11):1427-33.
 53. Amate P et al. Ovarian cancer: sites of recurrence. *Int J Gynecol Cancer*. 2013;23(9):1590-6.
 54. Manganaro L et al. Imaging strategy in recurrent ovarian cancer: a practical review. *Abdom Radiol (NY)*. 2019;44(3):1091-102.
 55. Kwek JW, Iyer RB. Recurrent ovarian cancer: spectrum of imaging findings. *AJR Am J Roentgenol*. 2006;187(1):99-104.
 56. Suppiah S et al. Systematic review on the accuracy of positron emission tomography/computed tomography and positron emission tomography/magnetic resonance imaging in the management of ovarian cancer: is functional information really needed? *World J Nucl Med*. 2017;16(3):176-85.
 57. Sala E et al. Recurrent ovarian cancer: use of contrast-enhanced CT and PET/CT to accurately localize tumor recurrence and to predict patients' survival. *Radiology*. 2010;257(1):125-34.
 58. Khiewvan B et al. An update on the role of PET/CT and PET/MRI in ovarian cancer. *Eur J Nucl Med Mol Imaging*. 2017;44(6):1079-91.