

EMJ

Congress Review

Volume 10 Supplement 11
November 2022
emjreviews.com



An Overview of the
EORTC-CLTG 2022
Congress

Oncology 

An Overview of the EORTC-CLTG 2022 Congress

The European Organisation for Research and Treatment of Cancer (EORTC) Cutaneous Lymphoma Tumours Group (CLTG) Annual Meeting took place in Madrid, Spain, between 22nd and 24th September 2022



Authors:	Nicola Humphry
Affiliation:	Nottingham, UK
Disclosure:	Humphry has declared no conflicts of interest.
Support:	The publication of this article was funded by Helsinn Healthcare SA.
Citation:	EMJ Oncol. 2022;10[Suppl 11]:2-11. DOI/10.33590/emjoncol/10045588. https://doi.org/10.33590/emjoncol/10045588 .



Meeting Summary

This year's European Organisation for Research and Treatment of Cancer (EORTC) Cutaneous Lymphoma Tumours Group (CLTG) Annual Meeting was held in Madrid, Spain. Presentations covered a broad range of topics in the field of cutaneous lymphomas, from molecular mechanisms, through diagnostics and prediction of prognosis, to skin-directed and targeted therapies, combination therapies, and patient-reported outcomes.

There was an overall feeling at the EORTC-CLTG meeting that further research is needed to better define the molecular basis for the different forms of cutaneous T cell lymphoma (CTCL), which will facilitate the development of novel treatments and therapeutic drug combinations. However, it was clear that significant progress had been made in understanding the biology behind CTCL, and that a broad range of therapies are available that provide symptomatic control in many patients.

Introduction

Cutaneous T cell lymphoma (CTCL) is the predominant form of primary cutaneous lymphoma and comprises a heterogeneous group of rare diseases.¹ Mycosis fungoides (MF) is the most common CTCL, accounting for 62% of cases, while other CTCL types such as Sézary syndrome (SS) are less prevalent.¹

MF is caused by the malignant transformation of effector memory T cells in the skin.² MF is usually associated with an indolent clinical course, and can remain stable for many years, though painful, itchy lesions can affect quality of life.^{2,3}

Ulcerating tumours may occur in more advanced disease.⁴ SS is an erythrodermic, leukaemic variant of CTCL, thought to arise from thymic memory T cells, which is characterised by blood involvement and lymphadenopathy.^{2,4}

Molecular Mechanisms in Cutaneous T Cell Lymphoma

Martine Bagot and Manuel Serrano

Bagot (Hôpital Saint Louis, Paris, France) presented the current understanding of the

tumour microenvironment (TME) in MF and SS as part of an industry-sponsored symposium. It was explained that in both of these forms of CTCL, malignant T cells cause a shift from a predominantly Type 1 helper T cell to a Type 2 helper T cell immune profile in the TME.^{5,6} Progressive immune dysfunction is associated with tumour cell growth, with a shift from anti-tumorigenic tumour-associated macrophages to pro-tumorigenic tumour-associated macrophages.⁷ It was emphasised that optimal therapies for MF and SS are likely to be those targeting malignant cells and/or restoring the Type 1 helper T cell/Type 2 helper T cell balance.⁵⁻⁷

Cellular senescence plays a role in post-therapeutic outcomes in CTCL and other malignancies. Research data presented by Serrano (Institute for Research in Biomedicine, Barcelona, Spain) during the symposium explained that senescent cells are often able to avoid cancer immunotherapy by secreting immunosuppressive factors, and that, upon cessation of therapy, this environment permits the regrowth of tumour cells.⁸ It was emphasised that senolytic drugs, such as those that target programmed death ligand 2, can be used to induce apoptosis in senescent cells, and that promising pre-clinical data have been published regarding senolytic drugs, including when used in combination with other agents such as immune checkpoint inhibitors.⁹⁻¹²

Diagnosis of Cutaneous T Cell Lymphoma

Miguel Piris, Thom Doeleman, Ruth Alonso-Alonso, and Pietro Quaglino

Data presented by Piris (Fundación Jiménez Díaz, Madrid, Spain) as part of another industry-sponsored symposium indicated that the application of immunohistochemistry in CTCL diagnosis has reached a plateau, and that molecular diagnostics should be at the centre of routine diagnostics. To facilitate the introduction of new, non-cytotoxic therapies, research needs to better define the molecular bases of the different forms of CTCL, and mechanistic models are needed to analyse the mutated genes and pathways involved. Furthermore, Piris explained

that more information is needed regarding the contribution of the stroma, the role of potential infectious agents, the mutations present in lymphoid progenitor cells, and sub-clonal dynamics in CTCL.

The application of artificial intelligence (AI) could potentially help to distinguish between early MF and benign inflammatory dermatoses. Research data from Doeleman (Leiden University Medical Center, the Netherlands), described a proof-of-concept study that evaluated the use of deep learning to assist with the classification of these conditions using digital skin biopsies.²³ An institutional dataset of images from patients with MF (n=178) or inflammatory dermatoses (n=165) was used. At a magnification of 200x, the trained AI algorithm differentiated MF from inflammatory dermatoses with a similar level of accuracy as two expert pathologists. Doeleman explained that although these results indicate the potential of AI to support MF diagnostics, this model requires expansion into a multi-institutional dataset.

Evaluating differential gene expression during the progression of CTCL may be one approach to improving staging. Alonso-Alonso (Instituto de Investigación Sanitaria, Hospital Universitario Fundación Jiménez Díaz, Madrid, Spain) presented data from a NanoString (NanoString Technologies, Seattle, Washington, USA) analysis of tissue samples from patients with MF (n=31) or inflammatory dermatoses (n=16) at a single centre in Spain.¹⁴ Unsupervised gene clustering was used to analyse the differential expression of a custom panel of genes. Differential expression of several genes was identified in patients with MF when compared to those with inflammatory dermatoses, and differences were also observed between early MF and advanced MF. It was noted that the high degree of inter-tumoural heterogeneity observed in this study suggests the existence of individual molecular signature features in patients.

Staging of MF includes the identification of patches, plaques, and tumours on the skin of the patient, although differentiating between these lesion types can be rather subjective.¹⁵ The current tumour, node, metastasis plus blood staging system does not modify MF stage according to the presence of plaques,¹⁵ despite their association with lower overall survival (OS)

and progression-free survival (PFS),^{16,17} and with more frequent use of systemic therapy at first-line.¹⁸ Quaglino (Università degli Studi di Torino, Turin, Italy) presented data from a survey of expert physicians in which all 22 respondents concurred that it was important to distinguish between patches and plaques in early-stage MF, and over half agreed that a biopsy should be performed for confirmation.¹⁹ Most respondents felt that the current positioning of plaques in the tumour, node, metastasis plus blood system was clinically inadequate. Quaglino concluded that prospective studies are needed to identify clinicopathological correlations between prognosis and patches/plaques and emphasised that there is a role for biomarkers in distinguishing disease stage.

Prediction of Prognosis

Julia Scarisbrick and Vanessa Gargallo Moneva

The estimated 5-year survival rate ranges from 89% to 98% for early-stage MF, and prognostic risk factors include advanced disease stage and older age.¹⁶ Additionally, higher levels of β 2-microglobulin, lactate dehydrogenase, and total IgE are associated with a more advanced disease stage.²⁰

Scarisbrick (University Hospital Birmingham and the University of Birmingham, UK) reported the results of an analysis of the PROspective Cutaneous Lymphoma International Prognostic Index (PROCLIP) study, which aimed to identify prognostic factors in MF and SS (n=698).²¹ In early-stage CTCL, the presence of plaques and large cell transformation (LCT) in the skin were associated with disease progression. Characteristics that differed between patients with late-stage versus early-stage disease included older age, poorer quality of life, and greater disease-related mortality. A prognostic index consisting of four risk factors (Stage IV disease, age >60 years, raised lactate dehydrogenase level, and LCT in the skin) permitted the stratification of patients into low-, intermediate-, and high-risk groups, with significant differences in the rates of disease progression and OS between groups.

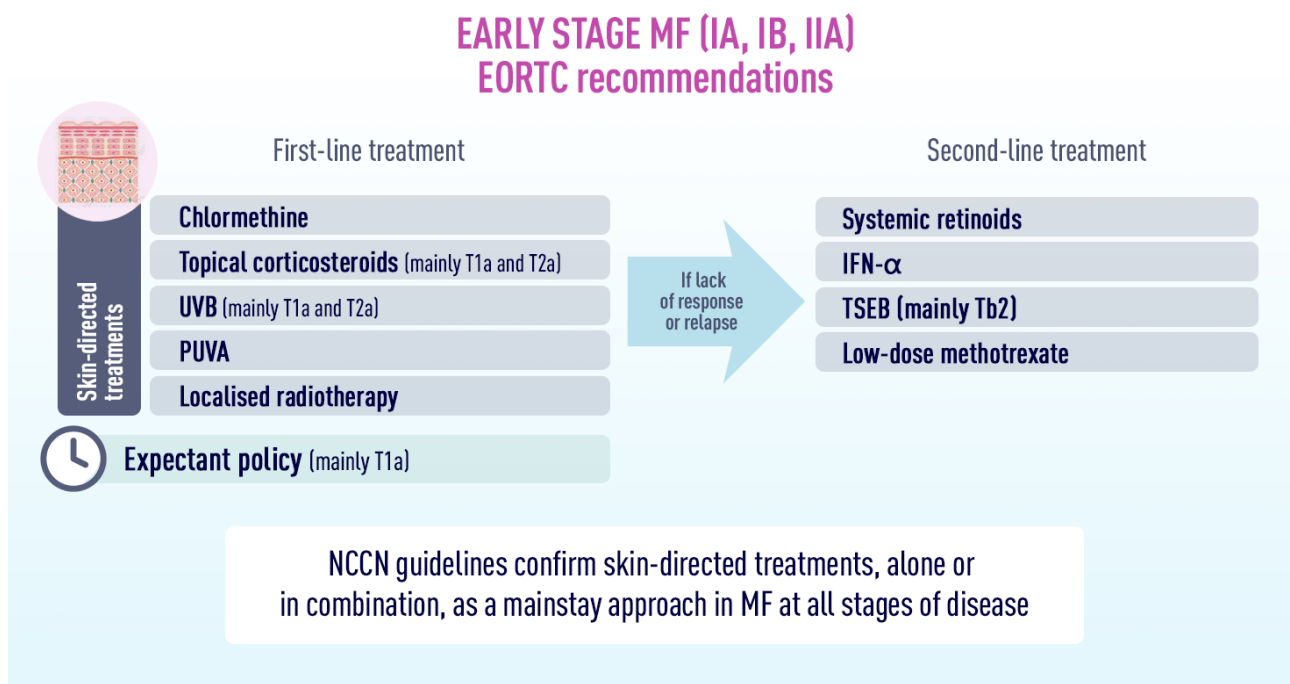
A retrospective genetic analysis of biopsy samples from 51 patients with early-stage MF, of whom 21 experienced disease progression over a median follow-up of 8 years, was presented by Gargallo Moneva (Hospital Universitario del Sureste, Arganda del Rey, Madrid, Spain).²² Samples were analysed using NanoString technology by using a panel of 97 genes. Several genes were highly expressed in the no-progression group versus the progression group, including genes encoding cluster of differentiation (CD) 8, which has been associated with better prognosis in MF,^{23,24} and *CXCL10*, which is related to epidermotropism.^{25,26} On the other hand, genes that were more highly expressed in the progression group versus the no-progression group included *CD79A/B*, *CD19*, and *CXCL13*. Interestingly, *CD79A/B* and *CD19* are associated with B cells, which are found in greater numbers in more advanced MF,²⁷ and *CXCL13* encodes B cell-attracting chemokine 1, which acts as a B cell chemoattractant.²⁸

Updates in Cutaneous T Cell Lymphoma Treatment

Pablo Ortiz-Romero, Emanuella Guenova, Chalid Assafj, Julia Scarisbrick, Keila Mitsunaga, H el ene Moins-Teisserenc, Janika Gosmann, Evangelina Papadavid, Maxime Battistella, Christina Mitteldorf, Mathias Oymanns, and Laura Gleason

Topical therapies, phototherapy, local radiation therapy, and total skin electron-beam therapy (TSEBT) play important roles in the treatment of early-stage MF, when symptoms are generally restricted to inflammatory lesions on the skin (Figure 1).^{29,30} Advanced-stage MF is more likely to be managed with systemic therapies, with guideline-recommended options such as brentuximab vedotin (brentuximab), bexarotene, extracorporeal photopheresis (ECP), interferon (IFN), and methotrexate, among others.²⁹ Updates on several of these therapeutic approaches were presented at the EORTC-CLTG 2022 meeting, as follows.

Figure 1: Recommendations for first- and second-line treatment of early-stage mycosis fungoides.



IFN: interferon; MF: mycosis fungoides; NCCN: National Comprehensive Cancer Network; PUVA: photodynamic therapy; TSEB: total skin electron beam therapy; UVB: ultraviolet B.

Reproduced with permission from *MF Talks*.²⁶

Chlormethine Gel

Chlormethine (also known as mechlorethamine) is an alkylating agent that predominantly inhibits rapidly proliferating malignant T cells.^{32,33} Chlormethine has been used as a treatment for patients with MF since the 1950s, and a gel formulation was more recently approved in several countries, including the European Union (EU) and USA.^{33–35}

In an industry-sponsored symposium, Ortiz-Romero (Hospital Universitario 12 de Octubre, Madrid, Spain), presented data from a recent *in vitro* study comparing the release rate profiles and permeation characteristics of chlormethine gel and ointment.³⁶ The results indicated that chlormethine release over a 5-hour period was significantly higher for the gel than for the ointment and that minimal amounts of chlormethine passed through the epidermal tissue to reach the dermal tissue. Furthermore, Ortiz-Romero emphasised that bioanalytical assays have shown a lack of evidence for systemic absorption of topical chlormethine gel.³⁷

Another *in vitro* study assessed the effects of chlormethine gel on malignant T cells in the skin.³² During the same symposium, Guenova (University Hospital of Lausanne, University of Lausanne, Switzerland) explained that chlormethine decreased T cell viability in a time- and dose-dependent manner, predominantly through the induction of DNA double-stranded breaks. In addition, chlormethine induced the expression of the pro-apoptotic *CASP3* gene and down-regulated genes related to DNA repair.³²

One of the pivotal trials of chlormethine gel was the randomised, controlled, observer-blinded, multicentre 201 trial, which showed that, in terms of response rate, the gel formulation was non-inferior to the ointment in patients with early-stage MF (n=260).³⁸ Assaf (Helios Klinikum Krefeld, Lutherplatz, Germany), described a recent *post hoc* analysis of these data, which aimed to evaluate whether prior exposure to bexarotene or phototherapy affected the response to chlormethine gel (n=118).³⁹ The results showed no statistically

significant difference in the time to first response (measured by the Composite Assessment of Index Lesion Severity [CAILS]) between patients who had received prior bexarotene and/or phototherapy and those who had not, indicating that chlormethine is a valid treatment option in patients who have received prior therapy for MF.

Alberti-Violetti (University of Milan, Milan, Italy), presented a poster describing the results of a retrospective, multicentre, observational study which aimed to evaluate the efficacy and tolerability of chlormethine gel in a real-world Italian cohort.⁴⁰ A total of 68 patients with MF were included, of which 63% were male and the majority had classical MF (76%) and Stage I disease (68%). Chlormethine gel was prescribed either as monotherapy or in combination with a systemic treatment. Two-thirds of patients applied chlormethine gel at a frequency of 4–5 days per week, with one-third applying the gel on a daily basis. Over 3/4 of patients achieved a complete or partial response (as measured by the Severity Weighted Assessment Tool [mSWAT]). No patient experienced a severe adverse event (AE). Hyperpigmentation and irritant contact dermatitis were the most common AEs, each occurring in more than half of patients. Alberti-Violetti concluded that this study confirms the efficacy and tolerability of chlormethine gel for MF in clinical practice in Italy.

Extracorporeal Photopheresis

In ECP, a patient's blood is exposed extracorporeally to photoactivated 8-methoxypsoralen.⁴¹ In one industry-sponsored symposium, Scarisbrick explained that guidelines recommend ECP as a first-line treatment option for Stage III MF and for SS,^{30,41,42} and some suggest that it may be suitable for earlier stages of MF with blood involvement.³⁰ ECP can be safely combined with many other systemic treatments available for the treatment of CTCL, such as phototherapy, IFN, retinoids, or bexarotene, and with skin-directed therapies such as chlormethine gel.^{30,41,42}

During the same symposium, Ortiz-Romero reported data from a Spanish real-world study of ECP in the management of CTCL (n=64). Most patients had Stage IVA1 disease at baseline (51.6%), and the median number of prior lines

of systemic therapy was two. The majority of patients (82.8%) were treated with two cycles of ECP per month, and 75.0% of patients received ECP as part of a combination therapy. The overall response rate (ORR) in the skin was 49.0%, with a median duration of response of 28 weeks, and the responses to combined therapy tended to be better than those to monotherapy. Ortiz-Romero concluded that ECP is effective in a real-world setting in Spain.⁴³

Pegylated Interferon- α

IFN α -2a has been approved for use in CTCL for over 30 years, and pegylated IFN α -2a was approved more recently, in 2002.⁴⁴ However, Mitsunaga (Hospital Universitario 12 de Octubre) stressed that IFN α -2a is no longer produced in either the EU or USA, leaving pegylated IFN α -2a as the only available form of the drug for therapeutic use.⁴⁵ Mitsunaga explained that conjugation to polyethylene glycol (i.e., pegylation) extends the half-life of IFN α and may reduce the frequency of acute AEs such as fatigue and flu-like symptoms, as well as neuropsychological AEs such as depression.⁴⁶⁻⁴⁸

Mitsunaga presented data from a real-world study of pegylated IFN α -2a in the treatment of primary CTCL.⁴⁵ The international, multicentre, retrospective study included patients with MF or SS of any stage (n=105), and more than half the patients received pegylated IFN α -2a as part of combination therapy with ECP, bexarotene, chlormethine gel, or phototherapy. Approximately 50% of patients responded to therapy, and more than 10% of patients achieved a complete response (CR). Two-thirds of patients experienced an AE, most commonly flu-like symptoms, lymphopenia, and neutropenia.

Mogamulizumab

Mogamulizumab is an antibody that selectively binds to C-C chemokine receptor Type 4, which is expressed on the surface of malignant T cells in MF and SS, resulting in cell death. Mogamulizumab is approved in the EU for the treatment of adults with MF and SS who have received at least one prior systemic therapy.⁴⁹

In an industry-sponsored symposium, Moins-Teisserenc (Université de Paris, Institut de Recherche Saint Louis, Paris, France) presented

data from a prospective longitudinal study of the impact of mogamulizumab on the TME in patients with relapsed or refractory SS (n=260) or age-matched controls (n=15).⁵⁰ Mogamulizumab induced early changes in the blood suggestive of immune restoration, with 65.4% of patients achieving an initial CR. Benign T cells and activated regulatory T cell levels decreased over the first month of treatment, while in the long-term, the patients experienced a sustained increase in naïve and stem memory CD4+ T cells.⁵¹

The effect of mogamulizumab on the malignant T cell population was also studied in a retrospective flow cytometry analysis of patients with MF or SS (n=11). Gosmann (University of Bochum, Germany), reported that a significant reduction in malignant T cells was observed after four cycles of treatment; substantial reductions in CD3+, CD5+/CD7-, and CD4+/CD26+ T cells were observed.⁵² Gosmann suggested that an increase in the malignant T cell population could be a criterion for secondary resistance, and that flow cytometry-based monitoring could lead to more personalised treatment options.

Presenting data from three recent studies, as part of one of the industry-sponsored symposia, Papadavid (National and Kapodistrian University of Athens, Greece), emphasised that real-world data support the efficacy of mogamulizumab in the clinical setting. A retrospective study of patients with advanced CTCL (n=21) in France reported a PFS of 22.0 months and an ORR of 57% over a median follow-up period of 11.6 months.⁵¹ A similar retrospective study combining patients from the UK and Spain (n=13) reported an ORR in the skin of 67% of patients. Furthermore, in patients with nodal disease, 90% achieved stable disease and 10% achieved a partial response.⁵³ Finally, real-world data from Australia and trial data from MAVORIC were combined to compare relative survival outcomes in advanced MF or SS between mogamulizumab and vorinostat (n=182).⁵⁴ This study reported that median OS was 57.2 months for mogamulizumab and 40.0 months for vorinostat, although the hazard ratio of 0.679 did not attain statistical significance (p=0.063).

Mogamulizumab can induce the development of a skin rash, termed mogamulizumab-associated rash (MAR), which has been associated with

a higher response rate and longer OS.^{55,56} Battistella (Université Paris Cité and Hôpital Saint Louis, France) suggested that potential mechanisms to distinguish MAR from disease progression include the identification of an inverted or normalised CD4:CD8 ratio,^{57,58} CD8+ exocytosis,^{57,58} follicular involvement,⁵⁷ lymphocyte atypia,⁵⁵ or the retention of CD7 expression.⁵⁷

Mild MAR is managed with a continuation of mogamulizumab treatment and the addition of steroids or antihistamines, while more severe MAR requires a biopsy and either delay or discontinuation of mogamulizumab.⁴⁹

Mitteldorf (University Medical Center Göttingen, Germany), presented the case of a 33-year-old female patient with a novel form of MAR termed lupus miliaris disseminates faciei-like MAR.⁵⁹ After 12 months of treatment, the patient developed yellowish-red papules around the eyes and nose. A biopsy revealed a dense, predominantly CD8+ infiltrate, with evidence of psoriasiform, spongiotic, folliculotropic, and granulomatous components. Therapy was discontinued, after which the rash resolved over a period of 7 weeks. It was explained that further forms of MAR are likely to be identified in the future.

Brentuximab

Brentuximab is a monoclonal antibody directed at CD30, which is fused to monomethyl auristatin E (MMAE), a potent anti-tubulin agent.⁶⁰ Brentuximab is approved for the treatment of adults with CD30+ CTCL after at least one prior systemic therapy.⁶⁰

Presenting evidence from four recent investigations, Papadavid explained that brentuximab outcomes in real-world studies should be interpreted with caution because of their small sample size, limited follow-up, and lack of mature data. An analysis of prospective data from the Spanish Primary Cutaneous Lymphoma Registry revealed that the ORR was 67% and the PFS was 10.3 months in patients with CTCL who were treated with brentuximab and followed up for a mean duration of 18.0 months (n=67). Furthermore, CD30 expression did not appear to influence the ORR.⁶¹ A retrospective study of patients with MF or SS,

from eight European countries, showed that brentuximab achieved an overall response lasting ≥ 4 months in 42% of patients, an ORR of 67%, and a CR rate of 27% (n=67). This study also indicated that the efficacy of brentuximab was independent of CD30 positivity.⁶² A retrospective review of patients with MF and LCT in the USA (n=23) reported that the lymph node CR rate and the improvement in the modified mSWAT score were both numerically greater for brentuximab than for bexarotene, skin-directed therapy, or chemotherapy.⁶³ Finally, a retrospective analysis of brentuximab in combination with skin-directed therapy in patients with CD30+ CTCL in Germany found that complete remission was achieved in 30.8% of patients, with an ORR of 84.6% (n=26). The authors of the analysis concluded that the addition of skin-directed therapies to brentuximab extended the time until the next therapeutic escalation.⁶⁴

Combination Therapy

In addition to having cytotoxic properties, the active agent of brentuximab (MMAE) is a highly potent radiosensitiser. For example, a preclinical study showed that MMAE sensitised colorectal cancer cells and prostate cancer cells to irradiation in a schedule- and dose-dependent manner.⁶⁵ Oymanns (Helios Klinikum Krefeld, Germany), presented data from a small study combining brentuximab and ultrahypofractionated, low-dose and total skin electron-beam therapy radiation in patients with advanced stage CTCL: all four patients achieved near CR within 8 weeks of therapy.⁶⁶

Gleason (Thomas Jefferson University, Philadelphia, USA), presented the results of a retrospective case series that assessed the combination of chlormethine gel and narrow-band ultraviolet B phototherapy in patients with MF (n=5).⁶⁷ One patient achieved CR, three patients achieved PR, and one patient had stable disease during a treatment period of 2–11 months. Two patients experienced no AEs, and all the reported AEs were skin-related. It was concluded that combining chlormethine gel and narrow-band ultraviolet B phototherapy may be a safe and effective treatment for MF.

Perceptions of Mycosis Fungoides

Aviv Barzilai

Barzilai (Chaim Sheba Medical Center, Tel Hashomer, Ramat Gan, Israel), described the results of an online survey of dermatologists' perceptions of illness in early-stage MF (n=80).^{68,69} It was explained that dermatologists generally viewed MF as a chronic disease, which caused a moderate emotional burden but had little impact on patients' lives. In contrast to patients' perceptions,⁷⁰ many dermatologists felt that patients were able to control their disease. The presentation emphasised that this study found that dermatologists used a high diversity of themes when presenting MF to patients, and Barzilai concluded that maintaining patient-centred communication will enable dermatologists to identify gaps between their own and their patients' perspectives on this disease.

Closing Remarks

New research presented at the EORTC-CLTG 2022 meeting demonstrated an increasing depth of understanding of the biology behind CTCL, and the mechanisms by which a variety of therapies modify it. There was an overall view that AI may have the potential to support the diagnosis of CTCL type and stage.

Novel data were generally supportive of the efficacy and safety of available therapies in a real-world setting, although an important need still remains for newer treatments and therapeutic drug combinations. Further research is needed to better define the molecular bases of the different forms of CTCL, since this will facilitate the introduction of new, non-cytotoxic therapies.

References

- Dobos G et al. Epidemiology of cutaneous T-cell lymphomas: a systematic review and meta-analysis of 16,953 patients. *Cancers (Basel)*. 2020;12(10):2921.
- Giordano A, Pagano L. The treatment of advanced-stage mycosis fungoides and Sézary syndrome: a hematologist's point of view. *Mediterr J Hematol Infect Dis*. 2022;14(1):e2022029.
- Ottevanger R et al. Quality of life in patients with mycosis fungoides and Sézary syndrome: a systematic review of the literature. *J Eur Acad Dermatol Venereol*. 2021;35(12):2377-87.
- Wilemze R et al. The 2018 update of the WHO-EORTC classification for primary cutaneous lymphomas. *Blood*. 2019;133(16):1703-14.
- Patil K et al. Molecular pathogenesis of cutaneous T cell lymphoma: role of chemokines, cytokines, and dysregulated signaling pathways. *Semin Cancer Biol*. 2021;S1044-579X(21)00296-0.
- Stolarenco V et al. Cellular interactions and inflammation in the pathogenesis of cutaneous T-cell lymphoma. *Front Cell Dev Biol*. 2020;8:851.
- Liu Z et al. The role of tumor microenvironment in mycosis fungoides and Sézary syndrome. *Ann Dermatol*. 2021;33(6):487-96.
- Piskorz WM, Cechowska-Pasko M. Senescence of tumor cells in anticancer therapy – beneficial and detrimental effects. *Int J Mol Sci*. 2022;23(19):11082.
- Muñoz-Espín D et al. A versatile drug delivery system targeting senescent cells. *EMBO Mol Med*. 2018;10(9):e9335.
- Triana-Martínez F et al. Identification and characterization of cardiac glycosides as senolytic compounds. *Nat Commun*. 2019;10(1):4731.
- Miao YR et al. Neutralization of PD-L2 is essential for overcoming immune checkpoint blockade resistance in ovarian cancer. *Clin Cancer Res*. 2021;27(15):4435-48.
- Ahmad SM et al. The inhibitory checkpoint, PD-L2, is a target for effector T cells: novel possibilities for immune therapy. *Oncoimmunol*. 2017;7(2):e1390641.
- Doelman T et al. Artificial intelligence-assisted probability scoring for differentiation of early mycosis fungoides and benign inflammatory dermatoses on H&E stained pathology slides of skin biopsies. *Eur J Cancer*. 2022;173(Suppl 1):S11.
- Alonso Alonso R et al. Mycosis fungoides: molecular identity revealed by nanostring analysis. *Eur J Cancer*. 2022;173(Suppl 1):S3-4.
- Olsen E et al. Revisions to the staging and classification of mycosis fungoides and Sézary syndrome: a proposal of the International Society for Cutaneous Lymphomas (ISCL) and the cutaneous lymphoma task force of the European Organization of Research and Treatment of Cancer (EORTC). *Blood*. 2007;110(6):1713-22.
- Agar NS et al. Survival outcomes and prognostic factors in mycosis fungoides/Sézary syndrome: validation of the revised International Society for Cutaneous Lymphomas/ European Organisation for Research and Treatment of Cancer staging proposal. *J Clin Oncol*. 2010;28(31):4730-9.
- Talpur R et al. Long-term outcomes of 1,263 patients with mycosis fungoides and Sézary syndrome from 1982 to 2009. *Clin Cancer Res*. 2012;18(18):5051-60.
- Quaglino P et al. Treatment of early-stage mycosis fungoides: results from the PROspective Cutaneous Lymphoma International Prognostic Index (PROCLIPi) study. *Br J Dermatol*. 2021;184(4):722-30.
- Rocuzzo G et al. Identifying unmet needs and challenges in the definition of a plaque in mycosis fungoides: an EORTC-CLG/ISCL survey. *Eur J Cancer*. 2022;173(Suppl 1):S11.
- Bahali AG et al. Prognostic factors of patients with mycosis fungoides. *Postepy Dermatol Alergol*. 2020;37(5):796-9.
- Scarisbrick JJ et al. Prognostic factors in mycosis fungoides and Sézary syndrome: results from the PROCLIPi study. *Eur J Cancer*. 2022;173(Suppl 1):S18.
- Gargallo Moneva V et al. Risk of progression of early-stage mycosis fungoides from RNA analysis. *Eur J Cancer*. 2022;173(Suppl 1):S4.
- Torii K et al. Determining the immune environment of cutaneous T-cell lymphoma lesions through the assessment of lesional blood drops. *Sci Rep*. 2021;11(1):19629.
- Abeni D et al. Circulating CD8+ lymphocytes, white blood cells, and survival in patients with mycosis fungoides. *Br J Dermatol*. 2005;153(2):324-30.
- Groom JR, Luster AD. CXCR3 in T cell function. *Exp Cell Res*. 2011;317(5):620-31.
- Yue C et al. STAT3 in CD8+ T cells inhibits their tumor accumulation by downregulating CXCR3/CXCL10 axis. *Cancer Immunol Res*. 2015;3(8):864-70.
- Nielsen PR et al. Role of B-cells in mycosis fungoides. *Acta Derm Venereol*. 2021;101(3):adv00413.
- Legler DF et al. B cell-attracting chemokine 1, a human CXC chemokine expressed in lymphoid tissues, selectively attracts B lymphocytes via BLR1/CXCR5. *J Exp Med*. 1998;187(4):655-60.
- Fujimura T et al. Topical and systemic formulation options for cutaneous T cell lymphomas. *Pharmaceutics*. 2021;13(2):200.
- National Comprehensive Cancer Network (NCCN). NCCN guidelines: primary cutaneous lymphomas - version 2.2022. 2022. Available at: <https://www.nccn.org/guidelines/guidelines-detail?category=1&id=1491>. Last accessed: 7 October 2022.
- MF Talks. Understanding MF-CTCL: treatment options. Available at: <https://mf-talks.com/temp/index.php?mtdgt=27>. Last accessed: 17 October 2022.
- Chang YT et al. Increased chlormethine-induced DNA double-stranded breaks in malignant T cells from mycosis fungoides skin lesions. *JID Innov*. 2021;2(1):100069.
- Helsinn Therapeutics. Valchlor (mechlorethamine). Prescribing information. 2020. Available at: https://www.accessdata.fda.gov/drugsatfda_docs/label/2020/202317s010lbl.pdf. Last accessed: 7 October 2022.
- Rafa Laboratories Ltd. Ledaga (chlormethine gel). Prescribing information. 2020. Available at: https://mohpublic.z6.web.core.windows.net/IsraelDrugs/Rishum_17_462433720.pdf. Last accessed: 7 October 2022.
- Helsinn Birex Pharmaceuticals Ltd. Ledaga (chlormethine gel). Summary of product characteristics. 2017. Available at: https://www.ema.europa.eu/en/documents/product-information/ledaga-epar-product-information_en.pdf. Last accessed: 7 October 2022.

36. Giuliano C et al. Chlormethine gel for the treatment of mycosis fungoides cutaneous T-cell lymphoma: in vitro release and permeation testing. *Dermatol Ther (Heidelb)*. 2022;DOI:10.1007/s13555-022-00813-y.
37. Querfeld C et al. Lack of systemic absorption of topical mechlorethamine gel in patients with mycosis fungoides cutaneous T-cell lymphoma. *J Invest Dermatol*. 2021;141(6):1601-4.e2.
38. Lessin SR et al. Topical chemotherapy in cutaneous T-cell lymphoma: positive results of a randomized, controlled, multicenter trial testing the efficacy and safety of a novel mechlorethamine, 0.02%, gel in mycosis fungoides. *JAMA Dermatol*. 2013;149(1):25-32.
39. Assaf C et al. A post-hoc analysis of clinical trial data shows that prior phototherapy does not affect response to chlormethine gel in patients with mycosis fungoides. *Eur J Cancer*. 2022;173(Suppl 1):S26-7.
40. Alberti-Violetti S et al. Real-life evaluation of efficacy and tolerability of chlormethine gel in Italian centers. *Eur J Cancer*. 2022;173(Suppl 1):S44.
41. Trautinger F et al. European Organisation for Research and Treatment of Cancer consensus recommendations for the treatment of mycosis fungoides/ Sézary syndrome - Update 2017. *Eur J Cancer*. 2017;77:57-74.
42. Gilson D et al. British Association of Dermatologists and U.K. Cutaneous Lymphoma Group guidelines for the management of primary cutaneous lymphomas 2018. *Br J Dermatol*. 2019;180(3):496-526.
43. Pérez-Carmona L et al. Extracorporeal photophoresis in dermatology. *Actas Dermosifiliogr*. 2009;100(6):459-71.
44. Hauptstein N et al. Bioconjugation strategies and clinical implications of interferon-bioconjugates. *Eur J Pharm Biopharm*. 2022;172:157-67.
45. Mitsunaga K et al. Real-world study of the use of pegylated interferon alfa for treatment of primary cutaneous T-cell lymphomas: an EORTC CLTF study. *Eur J Cancer*. 2022;173(Suppl 1):S24-5.
46. Harris JM, Chess RB. Effect of pegylation on pharmaceuticals. *Nat Rev Drug Discov*. 2003;2(3):214-21.
47. Hüsken AC et al. Comparison of pegylated interferon α -2b plus psoralen PUVA versus standard interferon α -2a plus PUVA in patients with cutaneous T-cell lymphoma. *J Eur Acad Dermatol Venereol*. 2012;26(1):71-8.
48. Zeuzem S et al. Peginterferon alfa-2a in patients with chronic hepatitis C. *N Engl J Med*. 2000;343(23):1666-72.
49. Kyowa Kirin. Poteligeo (mogamulizumab). Summary of product characteristics. 2022. Available at: https://www.ema.europa.eu/en/documents/product-information/poteligeo-epar-product-information_en.pdf. Last accessed: 7 October 2022.
50. Roelens M et al. Mogamulizumab induces long-term immune restoration and reshapes tumour heterogeneity in Sézary syndrome. *Br J Dermatol*. 2022;186(6):1010-25.
51. Jouandet M et al. Impact of mogamulizumab in real-life advanced cutaneous T-cell lymphomas: a multicentric retrospective cohort study. *Cancers (Basel)*. 2022;14(7):1659.
52. Gosmann JG et al. The effect of mogamulizumab on the malignant T cell population: a monocentric retrospective analysis. *Eur J Cancer*. 2022;173(Suppl 1):S26.
53. Molloy K et al. Real-world experience of using mogamulizumab in relapsed/refractory mycosis fungoides/ Sézary syndrome. *Br J Dermatol*. 2021;184(5):978-81.
54. Remák E et al. Understanding relative survival outcomes for patients with cutaneous T-cell lymphoma (CTCL) subtypes mycosis fungoides and Sézary syndrome treated with mogamulizumab or vorinostat: combining Australian real-world evidence and MAVORIC phase 3 trial data. *Eur J Cancer*. 2021;156(Suppl 1):S18.
55. Trum NA et al. Mogamulizumab efficacy is underscored by its associated rash that mimics cutaneous T-cell lymphoma: a retrospective single-centre case series. *Br J Dermatol*. 2022;186(1):153-66.
56. de Masson A et al. Macrophage-derived CXCL9 and CXCL11, T-cell skin homing, and disease control in mogamulizumab-treated CTCL patients. *Blood*. 2022;139(12):1820-32.
57. Musiek ACM et al. Dermatologic events associated with the anti-CCR4 antibody mogamulizumab: characterization and management. *Dermatol Ther (Heidelb)*. 2022;12(1):29-40.
58. Wang JY et al. Histopathologic characterization of mogamulizumab-associated rash. *Am J Surg Pathol*. 2020;44(12):1666-76.
59. Mitteldorf C et al. New type of mogamulizumab induced rash simulating Lupus miliaris disseminatus faciei. *Eur J Cancer*. 2022;173(Suppl 1):S24.
60. Takeda Pharma. Adcetris (brentuximab vedotin). Summary of product characteristics. 2022. Available at: https://www.ema.europa.eu/en/documents/product-information/adcetris-epar-product-information_en.pdf. Last accessed: 7 October 2022.
61. Muniesa C et al. Brentuximab vedotin in the treatment of cutaneous T-cell lymphomas: data from the Spanish Primary Cutaneous Lymphoma Registry. *J Eur Acad Dermatol Venereol*. 2022;DOI:10.1111/jdv.18563.
62. Papadavid E et al. Multicentric EORTC retrospective study shows efficacy of brentuximab vedotin in patients who have mycosis fungoides and Sézary syndrome with variable CD30 positivity. *Br J Dermatol*. 2021;185(5):1035-44.
63. O'Donnell M et al. Disease characteristics, prognosis, and response to therapy in patients with large-cell transformed mycosis fungoides: a single-center retrospective study. *J Am Acad Dermatol*. 2022;86(6):1285-92.
64. Stranzenbach R, Stadler R. Combination of brentuximab-vedotin with skin-directed therapies extends the time to the next therapeutic line in patients with cutaneous T-cell lymphoma. *J Dtsch Dermatol Ges*. 2021;19(3):383-7.
65. Buckel L et al. Tumor radiosensitization by monomethyl auristatin E: mechanism of action and targeted delivery. *Cancer Res*. 2015;75(7):1376-87.
66. Oymanns M et al. Near complete responses to concurrent brentuximab vedotin and ultra-hypofractionated low-dose total skin electron beam radiation in advanced CTCL. *Eur J Cancer*. 2022;173(Suppl 1):S23.
67. Gleason L et al. Combination therapy with Ther-O-07 - Combination therapy with chlormethine gel and narrow-band ultraviolet B for patients with

- mycosis fungoides: a case series. Eur J Cancer. 2022;173(Suppl 1):S23-4.
68. Segal O et al. Illness perception regarding early-stage mycosis fungoides among dermatologists: a multi-centre cross-sectional study. Acta Derm Venereol. 2022;102:adv00784.
69. Barzali A et al. Illness perception of early-stage mycosis fungoides among dermatologists: a multi-center cross-sectional study. Eur J Cancer. 2022;173(Suppl 1):S33.
70. Segal O et al. Illness perception, coping, and quality of life in early-stage mycosis fungoides. An Bras Dermatol 2021;96(1):27-33.

Click here to access MF talks - the new hub dedicated to Mycosis Fungoides Cutaneous T-Cell Lymphoma" with a link to the following [MF Talks - Home \(mf-talks.com\)](https://mf-talks.com)