


# Spinal Plasmacytoma Transformed Into Solitary Sacral Amyloidoma: A Case Report

<b>Authors:</b>	N. Neupane, <sup>1</sup> *H. Kharel, <sup>1</sup> M. Ammad-Ud-Din, <sup>2</sup> S. Jamshed <sup>3</sup>
	1. Department of Internal Medicine, Rochester General Hospital, New York, USA 2. Department of Hematology and Oncology, Moffitt Cancer Center, Tampa, Florida, USA 3. Department of Hematology and Oncology, Lipson Cancer Center, Rochester General Hospital, New York, USA *Correspondence to <a href="mailto:Himal.Kharel@rochesterregional.org">Himal.Kharel@rochesterregional.org</a>
<b>Disclosure:</b>	Jamshed reports financial support from Jansen. All other authors report no conflicts of interest.
<b>Acknowledgements:</b>	Informed consent was obtained from the patient.
<b>Received:</b>	24.07.23
<b>Accepted:</b>	25.10.23
<b>Keywords:</b>	Amyloidoma, plasmacytoma, sacral amyloidoma.
<b>Citation:</b>	EMJ Hematol. 2023; DOI/10.33590/emjhematol/10300884. <a href="https://doi.org/10.33590/emjhematol/10300884">https://doi.org/10.33590/emjhematol/10300884</a> .



## Abstract

Amyloidoma is a rare complication of plasmacytoma, that can involve the spine and present with compressive neurological symptoms. It is usually a diagnosis of exclusion, and is difficult to differentiate from other plasma cell disorders on imaging. Definite diagnosis requires a tissue biopsy. The treatment requires a multidisciplinary approach, with input from haematology, neurology, neurosurgery, and radiology for the optimum course of action, depending on the patient's comorbidities and performance status. The authors hereby present a case of solitary sacral amyloidoma in a 52-year-old African American female. Only three other cases of solitary sacral amyloidoma have been reported in the literature.

## Key Points

1. Plasmacytoma of the spine can present with residual amyloidoma after treatment.
2. The diagnosis of amyloidoma requires biopsy to exclude the mimics.
3. The treatment of spinal amyloidoma is challenging due to its close vicinity to the spinal cord, but early neurosurgical intervention has been shown to improve outcomes.

## INTRODUCTION

Amyloidosis results from a misconfiguration of normal protein into  $\beta$ -plated linear sheets, leading to the formation and deposition of

insoluble fibrils.<sup>1</sup> These fibrils can sometimes form a localised tumour-like mass called amyloidoma at specific organ sites, even in the absence of systemic amyloidosis.<sup>2</sup> Spinal amyloidoma can present with symptoms of nerve

compression and radiculopathy, depending upon the site of involvement.<sup>3</sup> Amyloidoma of the bone can sometimes be difficult to differentiate from other pathologies that commonly cause lytic lesions, like multiple myeloma (MM), plasmacytoma, and metastatic diseases.<sup>4</sup> Therefore, the definitive diagnosis requires a tissue biopsy and Congo red staining, which produces an apple-green birefringence under polarised light.

## PATIENT INFORMATION

A 52-year-old African American female with a past medical history of IgG lambda MM and sacral plasmacytoma presented with worsening back pain, bowel and bladder incontinence, bilateral lower extremity weakness, and saddle anaesthesia concerning for cauda equina syndrome. She had been diagnosed with IgG lambda MM with paraprotein level of 0.2 g/dL 10 months previously, and had received radiation and bortezomib, lenalidomide, and dexamethasone, with subsequent normalisation of the light chain ratio, and complete disappearance of paraprotein. She had declined autologous stem cell transplant. The MRI of lumbosacral spine carried out at the time of

plasmacytoma diagnosis showed an expansile and enhancing soft tissue mass overlying the right sacral ala, while the biopsy at that time showed presence of plasma cell neoplasm without any Congo red staining.

## CLINICAL FINDINGS AND DIAGNOSTIC ASSESSMENT

On presentation, initial lab work revealed normal levels of haemoglobin, creatinine, calcium, and serum protein. MRI of the lumbar spine revealed an irregular expansile enhancing soft tissue mass along the right hemisacrum from the S1 to S4–S5 level, encompassing the right neural foramina of S2, S3, and S4 (Figure 1). These findings were identical to the CT scan finding carried out 2 months previously. Furthermore, serum immunoglobulin, serum protein electrophoresis, urine protein electrophoresis, and free light chain ratio were also normal (Table 1). A PET scan was carried out 1 month prior to the presentation, and did not show FDG uptake or evidence of metastasis in the area. With these findings, the suspicion of MM, plasmacytoma recurrence, and malignancies were low, leaving a suspicion for a sacral amyloidoma (SaA) as the diagnosis of exclusion. CT-guided biopsy

Figure 1: Coronal T1 showing large inferior T1 mass in right sacrum crossing midline.

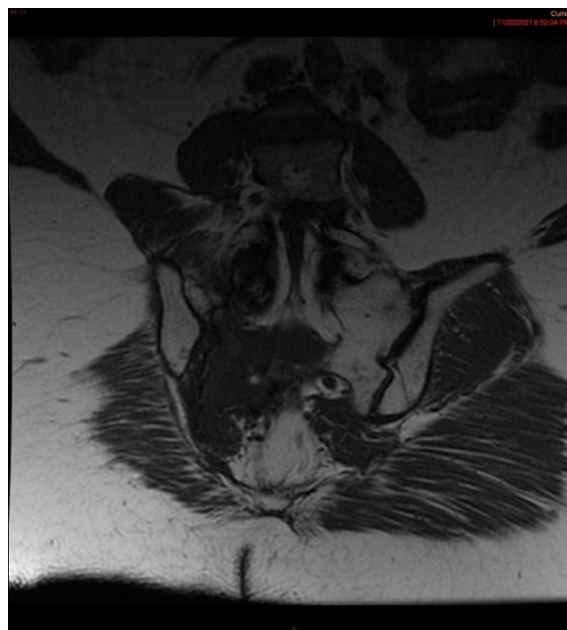


Table 1: Pertinent laboratory findings.

	Result	Normal reference range
<b>Immunofixation electrophoresis</b>		
Total protein	6.2	5.7–8.2 g/dL
Albumin	3.1	3.4–4.7 g/dL
Total globulin	3.1	1.7–4.3 g/dL
α1	0.2	0.1–0.3 g/dL
α2	1.2	0.6–1.0 g/dL
β	1	0.7–1.2 g/dL
γ	0.7	0.6–1.6 g/dL
β2 microglobulin	2.45	1.21–2.70 mcg/mL
SPEP	No monoclonal protein	
<b>Immunofixation, urine</b>		
Protein, ur24	720	0–150 mg/24hr
UPEP	37% albumin, and monoclonal band=6% excreted protein	
<b>Light chain serum</b>		
κ free light chains	0.84	0.33–1.94 mg/dL
λ free light chains	2.49	0.57–2.63 mg/dL
κ/λ free ratio	0.3373	0.26–1.65
<b>Immunoglobulins</b>		
IgG	613	700–1,600 mg/dL
IgM	78	50–300 mg/dL
IgA	85	70–400 mg/dL

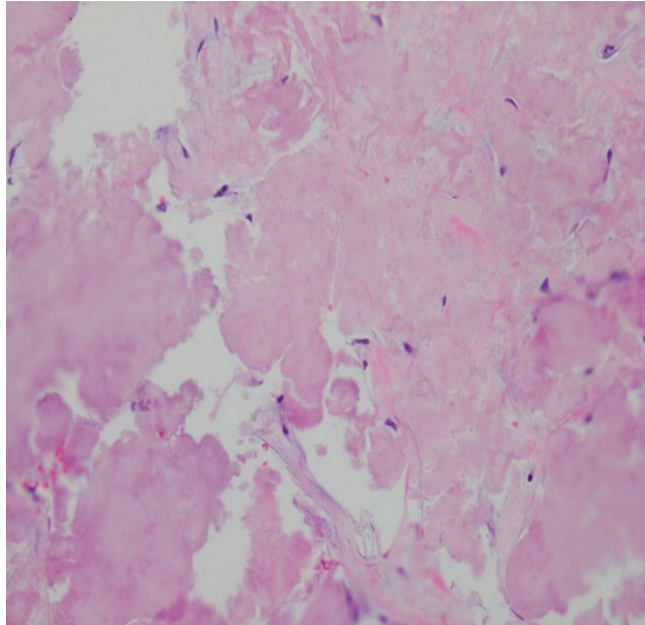
SPEP: serum protein electrophoresis; UPEP: urine protein electrophoresis.

was performed, which revealed a proteinaceous material showing apple-green birefringence under polarised light following Congo red stain, without evidence of plasma cell neoplasm, consistent with SaA (Figure 2). This was unlike the biopsy which occurred 10 months prior, at the time of initial diagnosis, which showed sheets of mature-appearing plasma cells. Furthermore, a colonoscopy with biopsy and cardiac MRI were also done, which ruled out systemic amyloidosis.

## **THERAPEUTIC INTERVENTION**

The patient was started on dexamethasone, which helped to improve the back pain and incontinence within days. Hospital stay was further complicated by methicillin-sensitive staphylococcal bacteraemia, acute anaemia (haemoglobin <7 g/dL), and sacral fracture. The patient was managed conservatively, considering she had improvement of neurological symptoms with steroids; the absence of a fat pad between the spinal cord; and the large size of the mass, which placed her at a high risk of surgical and long-term neurological complications.

Figure 2: Biopsy showing proteinaceous material with no evidence of neoplastic plasma cells.



In addition, bacteraemia made her a high-risk surgical candidate. She received dexamethasone 40 mg daily for 4 days. She was discharged with a spinal brace for outpatient follow-up.

## **FOLLOW-UP AND CLINICAL OUTCOMES**

A repeat CT scan 2 months later revealed the mass was stable, and MM remained in remission without biochemical progression.

## **DISCUSSION**

Amyloidoma is an aggregate of misfolded protein localised in an organ. It commonly involves the bladder, larynx, tonsils, skin, and lungs.<sup>5</sup> Solitary spinal amyloidoma (SSA) is rare, with sacral spinal amyloidoma being exceptionally uncommon. In a review of literature, there were a total of 38 reported cases of SSA, out of which 18 were thoracic, 13 were cervical, four were lumbar, and only three were sacral.<sup>3,4,6-9</sup> Like plasmacytomas, amyloidomas are usually found in the elderly, with 74% of cases being diagnosed between 60–80 years of age.<sup>3</sup> The patient, however, had an usually early presentation

at the age of 52, which may be due to her history of MM and sacral plasmacytoma, and may represent disease continuum. The exact mechanism or factors leading to transformation of the spinal lesion from plasmacytoma to amyloidoma is unknown, and needs further research. As amyloidoma is an expansile mass, the symptoms are generally progressive and are related to the site and neurological involvement.<sup>3-9</sup> The most common presenting symptoms in patients with SSA, as expected, are either pain or neurologic compromise, with decreased muscular strength (74.29%), and axial back pain (65.70%) reported. However, only 17% of cases present with acute symptoms.<sup>3</sup> The patient had chronic back pain, likely due to the evolving mass, but presented with cauda equina syndrome when the mass encroached the spinal cord.

For every patient with cauda equina syndrome, initial imaging starts with an emergent MRI/CT myelography of the spine.<sup>10</sup> An SSA generally appears as a hypointense lesion on T1- and T2-weighted images.<sup>3</sup> CT imaging generally reveals lytic bone lesions with cortical destruction, and possibly pathological fractures, further raising diagnostic challenges, as the findings mimic MM and other primary neoplasms, like plasmacytoma,

chondrosarcoma, or secondary metastatic lesions.<sup>11</sup> A biopsy is required to distinguish between SSA and other mentioned differentials. An apple-green birefringence when stained with Congo red stain visualised under polarised light, without evidence of plasma cell neoplasm, is classically seen.<sup>3-5</sup> Moreover, it should be noted that excluding systemic involvement is of utmost importance in such cases, to rule out systemic amyloidosis.

The treatment of the SSA is challenging, due to its close vicinity to the spinal cord, but early neurosurgical intervention has shown to improve outcomes. Based on the review by Pinheiro et al.,<sup>3</sup> out of 29 patients who underwent surgical resection for a spinal amyloidoma, 24 patients (82.76%) had post-operative neurological improvement. Out of the three cases of SaA, two underwent surgery, and both showed neurological improvement. Another case of SaA reported by Griffin et al.<sup>9</sup> had no neurological

symptoms, and therefore did not undergo surgical intervention. Based on few reports, surgery seems to be a reasonable approach in a symptomatic patient like this one. However, in this case, the authors elected for conservative management due to high surgical risk, and improvements in neurological symptoms with steroids.

## CONCLUSION

Although cases of distant amyloidoma arising secondary to plasmacytoma have been reported, as per the authors' knowledge, this is the first case report of plasmacytoma of the spine with residual amyloidoma after treatment. In cases of SaA presenting as cauda equina syndrome, it is imperative to initiate steroid therapy, and seek a neurosurgery consult for consideration of emergent decompression surgery.

### References

- Rambaran RN, Serpell LC. Amyloid fibrils: abnormal protein assembly. *Prion*. 2008;2(3):112-7.
- Pasternak S et al. Soft tissue amyloidoma of the extremities: report of a case and review of the literature. *Am J Dermatopathol*. 2007;29(2):152-5.
- Pinheiro JP et al. Management and outcome of solitary spinal amyloidoma - a systematic literature review. *World Neurosurg*. 2020;140:325-31.
- Klenke FM et al. Multiple myeloma-associated amyloidoma of the sacrum: case report and review of the literature. *Global Spine J*. 2014;4(2):109-14.
- Mahmood S et al. Natural history and outcomes in localised immunoglobulin light-chain amyloidosis: a long-term observational study. *Lancet Haematol*. 2015;2(6):e241-50.
- Brawanski N et al. Differentiated plasma cell myeloma presenting as a solitary spinal amyloidoma: a case report, possible pitfall and review to the literature. *Clin Neurol Neurosurg*. 2015;137:1-4.
- Bruninx G et al. [Isolated idiopathic amyloid tumor of the sacrum. An important differential diagnosis]. *J Radiol*. 2001;82(4):495-7. (in French).
- Giorgi PD et al. Spinal cord compression in dialysis-related upper cervical amyloidoma - a case report. *Spinal Cord Ser Cases*. 2021;7(1):40.
- Griffin M et al. Amyloid tumor of the sacrum. A case report. *Acta Cytol*. 1995;39(3):503-6.
- Bischoff RJ et al. A comparison of computed tomography-myelography, magnetic resonance imaging, and myelography in the diagnosis of herniated nucleus pulposus and spinal stenosis. *J Spinal Disord*. 1993;6(4):289-95.
- Haridas A et al. Primary isolated amyloidoma of the lumbar spine causing neurological compromise: case report and literature review. *Neurosurgery*. 2005;57(1):E196.