The Genetics of Cholestasis: A Practical Approach to Test Interpretation

This symposium took place on 22nd September 2026, as a virtual webinar organised by IPSEN Biopharmaceuticals, Inc

Funding Statement:	**The publication of this article was funded by IPSEN Biopharmaceuticals, Inc. All faculty members were compensated by IPSEN Biopharmaceuticals for their participation.**
Chairperson:	Naim Alkhouri[1]
Speakers:	Naim Alkhouri,[1] Edwin (Clay) Ferren,[2] Amber Hildreth,[3] James Squires,[4] Tatyana Kushner,[5] Fabian Rodas[6]
Conflicts of interest:	Alkhouri is a member of the speaker bureau for IPSEN; and a consultant for IPSEN and Mirum. Ferren is a speaker for IPSEN. Hildreth is a consultant and speaker for IPSEN and Mirum Pharmaceuticals. Kushner reports research support from Gilead, Mirum, IPSEN, and Madrigal; and has participated in advisory boards for GSK, Gilead, VIR, Bluejay, Mirum, IPSEN, and Madrigal. Rodas received research grants from Gilead Sciences, Zydus Pharmaceuticals, COUR Pharmaceuticals, Kowa Pharmaceuticals, GSK, and Pfizer; and consulting and speaker-bureau fees from IPSEN, Mirum Pharmaceuticals, Gilead Sciences, Intercept Pharmaceuticals, Alfasigma, Albireo Pharma, and Fujifilm. Squires is an advisor for Mirum and IPSEN; and a member of the Data Safety Monitoring Board for Sanofi.
Disclaimer:	This symposium was not a continuing medical education (CME) activity. The information contained in this article is intended to provide education on genetic testing considerations in cholestatic liver diseases and is not intended to provide or suggest treatment advice for specific patients. Determinations regarding patient care are at the sole discretion of the treating healthcare practitioner based on their knowledge, education, and clinical judgement.
Acknowledgements:	Medical writing assistance was provided by Mercy Ifeanyichukwu, freelance medical writer, Aba, Nigeria.
Keywords:	Alagille syndrome, cholestasis, family screening, genetic cholestasis, genetic testing, inherited liver diseases, progressive familial intrahepatic cholestasis (PFIC), test interpretation.
Citation:	EMJ. 2026; https://doi.org/10.33590/emj/99PDV82Z

1. Summit Clinical Research, Clinical Research Institute of Ohio, Westlake, USA
2. Atrium Health Levine Children's Genetics, Charlotte, North Carolina, USA
3. Rady Children's Hospital, The University of California San Diego, USA
4. University of Pittsburgh, Pennsylvania, USA
5. Weill Cornell Medicine, New York, USA
6. UT Health San Antonio, Texas, USA

Meeting Summary

Progressive familial intrahepatic cholestasis (PFIC) and Alagille syndrome are rare inherited liver diseases that most often present in infancy; though adult presentations are increasingly being recognised, they are still often overlooked given the phenotypic heterogeneity. Genetic testing is increasingly accessible in the clinic and can be done with a gene panel or by sequencing the exome or the whole genome. However, despite increased use, increasingly complex results make interpretation and diagnosis challenging for clinicians. Reports can reveal multiple variants, and their clinical relevance must be considered alongside inheritance, penetrance, genotype–phenotype relationships, family history, and the patient's clinical and biochemical phenotype. Establishing an accurate genetic diagnosis has implications beyond initial diagnosis, helping to inform appropriate long-term monitoring for disease progression, associated complications, and extrahepatic manifestations, as well as evaluation of at-risk family members. This multidisciplinary webinar took place on 22nd September 2026. Its speakers, who included paediatric and adult hepatologists and a geneticist, went through identifying, detecting, or diagnosing the disease in adults and children, selecting an appropriate test, and interpreting the test report. Case-based discussions then showed how inconclusive or uncertain genetic results must be evaluated in the context of the patient's clinical presentation, and how collaboration across hepatology and genetics can support diagnostic assessment and clinical decision-making.

Introduction

Genetic cholestatic liver diseases, a heterogeneous group of rare, inherited disorders, arise due to variants in a wide range of genes and may present with elevated serum bile acids, increased alkaline phosphatase, elevated or low gamma-glutamyl transferase (GGT), and elevated bilirubin levels.[1,2] These diseases differ in pathobiology, pathophysiology, presentation, and prognosis, but share the consequences of impaired bile formation/flow.[1] PFIC comprises a group of autosomal recessive disorders and typically presents in infancy or childhood with cholestasis, pruritus, and jaundice, with an estimated incidence of one in 50,000 to one in 100,000 births, although the exact prevalence is unknown.[3]

Genetic testing can help establish the underlying cause of cholestasis, particularly when clinical features alone do not distinguish between inherited disorders. When a 66-gene panel was applied to 2,171 infants, children, and young adults with cholestasis, 57% (n=1,237) of whom were younger than 1 year old, it identified a genetic diagnosis in 12% of patients (n=265), involving variants across 32 genes.[4] *JAG1* and *NOTCH2* variants of Alagille syndrome were the most frequent findings, followed by *ABCB11*, *SERPINA1*, *ABCB4*, and *POLG* variants.[4] The European Association for the Study of the Liver (EASL) guidelines recommend testing early in infants and children with cholestasis of unclear cause, and in adults once more frequent causes have been excluded, with genetic counselling beforehand.[1]

However, identifying when to suspect an inherited disorder and deciding how to investigate it in adults can be more challenging. Bile acid elevation is variable, pruritus ranges in severity,[5] and the syndromic features may be less apparent or recognised in adulthood.[6] Access to testing, and interpretation of the report, remain further obstacles for clinicians.[7] Moreover, identifying a genetic variant does not necessarily establish its clinical significance. Results must be considered alongside the patient's phenotype, family history, and inheritance pattern to determine their implications for diagnosis, management, and family screening. Against this background, this symposium brought together six experts in the field to discuss practical approaches to test interpretation and family screening in patients with suspected genetic cholestasis.

CC BY-NC 4.0 Licence • Copyright © 2026 EMJ

The programme covered when to suspect an inherited cause, how tests and reports are interpreted, which genes are involved, and how results may shape management, before moving to case-based discussion. The faculty comprised Naim Alkhouri, Chief Medical Officer, Summit Clinical Research, and Director of Research, Clinical Research Institute of Ohio, Westlake, USA; Edwin (Clay) Ferren, Atrium Health Levine Children's Genetics, Charlotte, North Carolina, USA; Amber Hildreth, Rady Children's Hospital and University of California San Diego, USA; James Squires, University of Pittsburgh, Pennsylvania, USA; Tatyana Kushner, Weill Cornell Medicine, New York, USA; and Fabian Rodas, UT Health San Antonio, Texas, USA.

Clinical Features of Genetic Cholestatic Liver Disease in Children

PFIC and Alagille syndrome are among the genetic cholestatic disorders commonly seen in paediatric hepatology practice. PFIC Types 1–3, the most common forms of the disease, are caused by familial intrahepatic cholestasis 1 (FIC1), bile salt export pump (BSEP), and multidrug resistance protein 3 (MDR3) deficiency, respectively.[3] Alkhouri highlighted that PFIC Type 1 carries extrahepatic manifestations, including hearing loss, pancreatitis, diarrhoea, and steatorrhoea, and can be aggressive in children who carry homozygous variations, some of whom require liver transplantation early in life. PFIC Type 2 also leads to severe cholestasis and early transplantation. As Alkhouri noted, "it is one of the few paediatric conditions in which hepatocellular carcinoma (HCC) must be considered."[2] In PFIC Type 3, impaired phospholipid secretion makes bile lithogenic, predisposing patients to gallstones, including intrahepatic stones, and raising the risk of HCC and cholangiocarcinoma. Alkhouri noted that this is the type "you're probably going to see the most in an adult hepatology practice."[1]

Alagille syndrome arises mainly from variants in *JAG1* and, less often, *NOTCH2*.[1] As this multi-system disease is autosomal dominant,[1] Alkhouri recalled diagnosing a child and then identifying it in one of the child's parents, showing how adults can remain undiagnosed for decades. EASL guidelines recommend genetic testing early in the diagnostic work-up of infants and children with cholestasis of unclear cause, because genetic variants may be the major determinant of the phenotype.[1] "Have a very low threshold," Alkhouri advised, since, with gene panels, "you can get the answer now quicker than testing for each suspected diagnosis separately."

Genetic Cholestasis in Adults

In adults, genetic cholestasis can present differently from the paediatric picture, with variable bile acid elevations, differences in the presence and severity of pruritus,[5] and a lower likelihood of the syndromic features of Alagille syndrome.[6] Alkhouri explained that the typical adult presentation is unexplained cholestasis with raised alkaline phosphatase, with or without raised GGT, and pruritus that can be severe, episodic, or daily, disturbing sleep and the ability to work. He noted that, in contrast to children, "we're not seeing bile acid levels above 200 like what you see in the paediatrics population," with levels in adult practice typically ranging between 30–50 µmol/L, an observation also echoed by Rodas during his case presentation.

In a cohort of 356 adults who underwent sequencing of cholestasis genes, at least one variant in *ABCB4* (PFIC3), *ABCB11* (PFIC2), or *ATP8B1* (PFIC1) was identified in 101 persons (28.4%), comprising 46 with *ABCB4*, 35 with *ABCB11*, and 28 with *ATP8B1*.[8] *ABCB4* variants were associated with chronic liver disease (71.7%), whereas *ABCB11* variants were associated with acute/episodic cholestasis and pregnancy-associated liver dysfunction (82.4%).[8] Alkhouri observed that many adult providers do not test for these diseases, emphasising that "if you don't test for something, you're not going to find it." Recognising that a genetic disorder may underlie cholestasis is only the first step; clinicians must then determine which patients to test and which testing approach is most appropriate.

Investigation and Timing of Genetic Testing

The diagnostic work-up of adults with cholestasis begins with clinical and family history, examination, and ultrasound to exclude dilated bile ducts, stones, or tumours, followed by antimitochondrial antibodies for primary biliary cholangitis (PBC) and magnetic resonance cholangiopancreatography (MRCP) for primary sclerosing cholangitis (PSC).[9] If these are negative, liver biopsy and/or genetic testing is considered. Assessing the contribution of an identified variant is complicated by environmental exposure, comorbidities, and medication use, so a stepwise approach is encouraged: rule out common liver diseases, consider liver biopsy and genetic testing, and re-evaluate regularly if the cause remains unclear (Figure 1).[10] Alkhouri noted that "when we go to the low to normal gamma GGT pathway, it is very important to also measure serum bile acids to assess if they are high."

Figure 1: Stepwise approach to investigating suspected genetic cholestasis in adults.

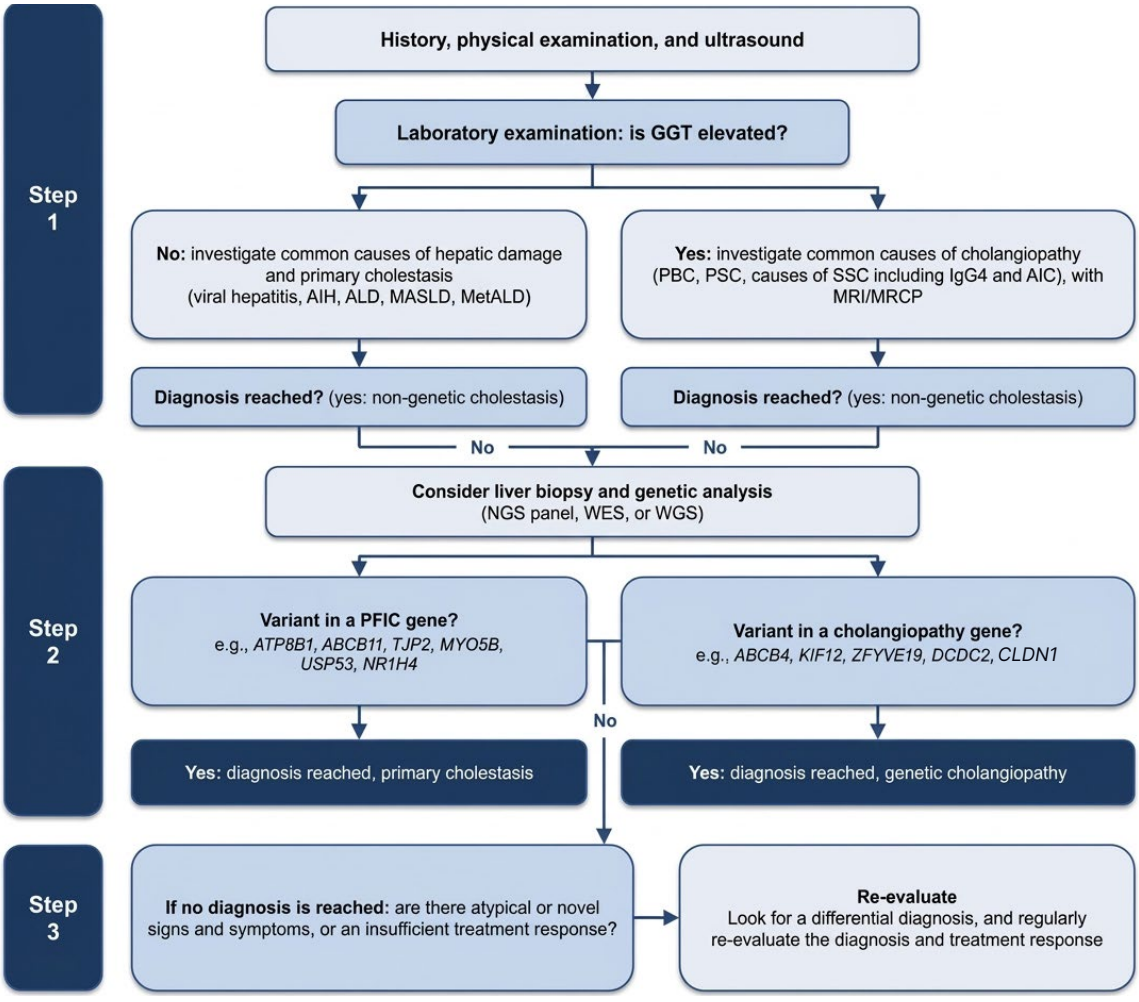

Adapted from Thompson et al.[10]

AIC: autoimmune cholestasis; AIH: autoimmune hepatitis; ALD: alcohol-related liver disease; GGT: gamma-glutamyl transferase; MetALD: MASLD with increased alcohol intake; MRCP: magnetic resonance cholangiopancreatography; NGS: next-generation sequencing; PBC: primary biliary cholangitis; PFIC: progressive familial intrahepatic cholestasis; PSC: primary sclerosing cholangitis; SSC: secondary sclerosing cholangitis; WES: whole-exome sequencing; WGS: whole-genome sequencing.

CC BY-NC 4.0 Licence • Copyright © 2026 EMJ

Alkhouri stressed that "early is better when it comes to genetic testing." Suggested triggers in acute cholestasis include severe or early-onset intrahepatic cholestasis of pregnancy (ICP) with serum bile acids of 40 µmol/L or above, or onset at or before 32 weeks of gestation; severe or recurrent drug-induced liver injury; and recurrent unexplained episodes. In chronic cholestasis, triggers include cryptogenic cholestasis, early-onset gallstones, a family history of liver disease, and atypical autoimmune liver disease once PBC and PSC are excluded.[11] Alkhouri reported that ICP had the highest diagnostic rate in his practice, with variants identified in around 50% of cases. He clarified that "not all ICP cases are caused by PFIC variants, but a high percentage," although most obstetricians do not test *ABCB4* or *ABCB11*.

Low phospholipid-associated cholelithiasis, typically linked to PFIC Type 3, accounted for approximately 1% of symptomatic cholelithiasis in adults in a case-control study across 11 French centres, with *ABCB4* variants present in 46% of cases and associated with common bile duct stones, chronic GGT elevation, and a personal or family history of hepatobiliary cancer.[12] Alkhouri advised that intrahepatic stones seen during endoscopic retrograde cholangiopancreatography, or stones recurring after cholecystectomy, should prompt questions about family history and consideration of testing, and described performing periodic MRCP in these patients given the risk of cholangiocarcinoma. Other history clues include consanguinity,[6] extrahepatic features such as congenital heart disease[6] or kidney disease,[13] and a family history of liver disease or early-onset gallstones.[12]

Genetic Testing Methods and Their Limitations

Genetic testing for cholestatic liver disease has moved from sequencing single genes towards broad, high-throughput approaches. EASL guidelines recommend next-generation sequencing and whole exome sequencing (WES), anticipate that whole genome sequencing will gradually replace both, and discourage Sanger sequencing as a first-line test.[1] Ferren noted that "Sanger sequencing is used more now for confirmation of genetic results." Gene panels are also broadening,[14] although Ferren noted that they are "usually out of date by the time they're published," because new disease-associated genes continue to be identified. Broader testing can increase the amount of genetic information available, but it can also increase the complexity of interpretation. The challenge therefore shifts from identifying a variant to determining whether that finding explains the patient's disease.[7]

The functional impact of many variants is unknown, so pathogenicity can be difficult to predict. Ferren illustrated this by noting that, were everyone attending the webinar tested, "the lab would find variants in every one of us," most of which are unlikely to be harmful since the group is "overall pretty healthy." Genotype–phenotype relationships can also be inconsistent.[15] A classic example of this is X-linked adrenoleukodystrophy, a condition that "can be fatal for young boys in childhood," though a sibling carrying the same variant may remain symptom-free or develop symptoms only in adulthood.[3] As such, even a confirmed genetic change cannot always predict the clinical course.

Interpreting Variants and Genetic Test Reports

Variant classification guidelines help laboratories categorise variants as pathogenic, likely pathogenic, of uncertain significance (VUS), likely benign, or benign.[16] Ferren emphasised that "a classification does not equal a diagnosis." The guidelines do not account for penetrance or variable expressivity, and a single pathogenic variant in a recessive gene may simply mean the patient is a carrier. Ferren cautioned that "identification of a pathogenic variant does not always indicate the patient has the disease." This distinction is particularly important when testing identifies a VUS or another inconclusive finding. Laboratories can also reach different conclusions on the

same variant, and ClinVar allows clinicians to "compare what other labs have said about a variant if it's been reported." However, evidence to support variant interpretation may be particularly limited for rarer PFIC subtypes, making it more difficult to establish the clinical significance of a finding. Variant classification alone does not establish a diagnosis; inheritance, phenotype, biochemical findings, and family history all contribute to assessing clinical relevance. Ferren explained that when broad sequencing is ordered, laboratories are "only filtering out the information that you provide to them." He recalled an infant sent for exome sequencing because of a heart defect, with hearing loss and a single kidney found afterwards. Ferren told the hepatologists, "I need your phenotype." A genetic test report gives the reason for referral, a result summary, zygosity, inheritance pattern, classification, and which genes have been tested. Ferren advised checking that genes associated with the suspected condition are included in the panel, as some remain difficult to sequence.

When the genetic and clinical findings do not align clearly, results may be best interpreted by a multidisciplinary team, in which the geneticist, pathologist, and hepatologist review genetic findings alongside biopsy results and clinical presentation, an approach described as hepatology genome rounds.[17] Ferren emphasised that testing is arriving earlier, adding: "If you can save a kid a liver biopsy or any kind of invasive procedure, that's fantastic." Ferren also encouraged ongoing follow-up for patients who remain without a molecular diagnosis, as testing technologies continue to evolve rapidly, and newer approaches may provide answers in the future. Ferren's advice is consistent with EASL guidelines advising retesting every 3 years.[1] Hildreth agreed, noting that "the more we test, the more we're going to find."

Key Genes in Genetic Cholestasis

Expanded genetic testing has identified a growing list of genes linked to cholestasis, and the number of PFIC subtypes has grown.[18] *ATP8B1*, *ABCB11*, and *ABCB4* remain among the most implicated,[18] and long-term follow-up studies of the first two demonstrate marked differences in disease progression. Fewer than half of 130 patients with FIC1 deficiency reached adulthood with their native liver,[19] while in 264 patients with BSEP deficiency, median native liver survival was 20.4, 7.0, and 3.5 years for genotype classes BSEP1, BSEP2, and BSEP3, respectively ($p<0.001$), and HCC had developed by 15 years of age in 4%, 7%, and 34% ($p=0.001$).[20]

TJP2 deficiency (PFIC4), recently characterised by low- or normal-GGT cholestasis, disrupts tight junctions between hepatocytes, allowing bile acids to leak and causing hepatocellular injury and chronic cholestasis.[21,22] It typically presents in newborns and infants. However, Hildreth stressed that it "has an increased risk of HCC, so [it is] really important for monitoring long term." She added that "there's been reports of chronic respiratory disease and development of subdural haematoma." Turning to Alagille syndrome, Hildreth explained that it is caused mostly by *JAG1* variants, with *NOTCH2* variants accounting for fewer than 3% of cases. In children with *JAG1* disease, cholestasis typically presents in the first year of life, and biopsies can show bile duct proliferation before paucity develops, so the syndrome may be mistaken for biliary atresia.[23] Hildreth emphasised that "the most important thing is differentiating from biliary atresia," noting that genetic results can often be obtained before a liver biopsy is needed. In patients with *NOTCH2* variants, extrahepatic manifestations are less common, with characteristic facial features reported in approximately 20% of cases.[24]

In the cohort of 356 adults discussed earlier, 28.4% carried a variant in *ABCB4*, *ABCB11*, or *ATP8B1*, most of them heterozygous.[8] Additionally, WES found a definitive or presumed diagnosis in 33% (17/52) of adults with liver disease of unknown aetiology.[25] For Hildreth, this showed that some "idiopathic" cases "actually had a genetic cause," despite not presenting in childhood.

CC BY-NC 4.0 Licence • Copyright © 2026 EMJ

Adults with *JAG1* variants may be diagnosed late and misclassified as having PBC, PSC, or idiopathic cholestasis, so where disease does not fully fit these diagnoses, "we should be thinking about something genetic, including *NOTCH2*," Hildreth said.[10,26,27] Hildreth highlighted that adults with Alagille syndrome are a "special patient population," with considerations including HCC risk, pregnancy-related complications, kidney disease, and cerebrovascular bleeding. Hildreth concluded that genomics and clinical phenotyping must be integrated, with *JAG1*, *NOTCH2*, and *TJP2* kept in the differential, "especially if they're not following what would be expected with their initial liver diagnosis."

Acting on Genetic Test Results

Squires explained that integrating genomic results with the clinical picture does not end once a diagnosis has been made. As genetic testing is increasingly performed earlier in the diagnostic pathway, results may become available before the full phenotype is evident, reversing the traditional diagnostic process.[1,3,4] A genetic diagnosis should therefore prompt a search for associated manifestations.

Alagille syndrome, for example, can affect the eyes, spine, heart, and kidneys,[1,23,24,28] whereas FIC1 deficiency is unusual among the PFIC subtypes as it also causes hearing loss, pancreatic disease, and diarrhoea.[15,29] Squires highlighted condition-specific follow-up investigations and surveillance strategies (Table 1). In patients with Alagille syndrome, this includes a baseline brain MRI to assess for vascular abnormalities such as Moyamoya disease, generally during adolescence and in any newly diagnosed adult.[26,31] Squires also emphasised the importance of cancer surveillance in BSEP deficiency[32] and *TJP2* deficiency,[33,34] while patients with MDR3 deficiency may benefit from ultrasound surveillance and, in selected cases, regular MRCP to detect intrahepatic stones.[5,12] Squires also highlighted work from Benjamin Shneider, Baylor College of Medicine, Houston; Texas Children's Hospital, Houston, USA, and the Childhood Liver Disease Research Network (ChiLDReN) on "the utility of liver stiffness measurement that can serve as a non-invasive surrogate for progression of liver disease," describing it as "critically important."[35]

Establishing an accurate diagnosis is important not only for explaining the patient's current presentation. Depending

Table 1: Follow-up investigations after a genetic diagnosis of cholestasis.[1,2,30]

Condition	Follow-up investigation
Alagille syndrome	Brain MRI to assess for Moyamoya disease (around adolescence and in newly diagnosed adults); echocardiogram; renal function tests; chest X-ray for butterfly vertebrae; eye exam to check for posterior embryotoxon
FIC1 deficiency	Hearing test
BSEP, *TJP2*, MDR3, and FXR deficiency	Cancer surveillance
MDR3 deficiency	Ultrasound, or possibly regular MRCP, to screen for gallstone formation
MYO5B-related disease	Screen for intestinal disease (like diarrhoea) and complications

BSEP: bile salt export pump; FIC1: familial intrahepatic cholestasis 1; FXR: farnesoid X receptor; MDR3: multidrug resistance protein 3; MRCP: magnetic resonance cholangiopancreatography.

on the underlying disorder, it may also inform longitudinal monitoring for disease progression, associated complications, and extrahepatic manifestations, as well as appropriate evaluation of family members. A genetic diagnosis may also reassure families, resolve uncertainty about future risk, and inform reproductive planning.[36]

Turning to treatment, Squires acknowledged that "historically, treatment for these conditions has really been non-specific," with management largely focused on chronic progressive liver disease and its complications.[37,38] Surgical approaches include partial external biliary diversion (PEBD), partial internal diversion, and ileal exclusion.[39,40]

In FIC1 deficiency, PEBD can be effective in selected patients[19] and, according to Squires, "there is no genotype–phenotype correlation for this intervention." Data from an international cohort suggest that "the diversion seems to work better in patients whose pre-diversion serum bile acids were less than 194 [µmol/L]."[19] By contrast, genotype may have a greater role in BSEP deficiency, where PEBD is effective in about half of patients, but those with biallelic truncating variants respond poorly, have a particularly high risk of HCC, and are more likely to die before transplantation.[20,41]

In Alagille syndrome, treatment "is really not dictated by genotype at all," Squires noted.[3] These differences in the relevance of genotype across cholestatic disorders highlight the importance of interpreting genetic findings in the context of each patient's clinical presentation. The following case-based discussion illustrated how this approach can inform diagnostic reasoning when genetic results are inconclusive.

Case-Based Discussion

Two hypothetical patient cases presented by the HCPs showed why a genetic result only means something when it is read alongside the patient. Kushner presented the first case, which was a 27-year-old female whose history included ICP. Biopsy showed bile ducts absent from 33% of portal tracts. Genetic testing in 2018 found a heterozygous VUS in *ABCB4*, and variants in this gene are often missed in adults.[42] At 8 weeks of gestation, the patient had severe pruritus, and bile acids were above 360 µmol/L.

Alkhouri noted that he would diagnose PFIC despite the VUS, given the presentation and raised bile acids. Squires noted that bile duct loss is not typically associated with MDR3 deficiency and wondered whether it might be a red herring, although loss of the smaller bile ducts has been described with *ABCB4* variants.[43] Hildreth and Ferren both advised exome or genome sequencing. WES yielded a genetic diagnosis in 5/21 adults with adult-onset cholestatic liver disease,[44] though VUS remain hard to interpret.[45]

Rodas presented the second patient, a 56-year-old female whose cirrhosis had first been put down to autoimmune hepatitis and later to metabolic dysfunction-associated steatohepatitis. Treatment did not work. After 8 months, severe pruritus and serum bile acids of 37 µmol/L led to genetic testing.

The genetic report identified a heterozygous pathogenic *UGT1A1* allele associated with Gilbert syndrome, alongside a second *UGT1A1* VUS. Genetic testing identified variants in *UGT1A1*, *CFTR*, *FECH*, and *VPS33B*. Rodas explained that "*UGT1A* is quite common. I think the prevalence goes for 40% in our patients." These findings were not enough to explain the disease. Cystic fibrosis transmembrane conductance regulator (CFTR) was less clear-cut, as it belongs to the same transporter family as BSEP and recent *in vitro* work suggests that CFTR potentiators can correct a protein defect,[46] so it could not be ruled out.

Rodas outlined the key steps for working through a report (Figure 2). Variants are classified from pathogenic to benign,[16] and he stressed the importance of knowing "what genetic mutations, what variants you are expecting, because if you don't know what you ordered, then you may miss the diagnosis."

CC BY-NC 4.0 Licence • Copyright © 2026 EMJ • November 2026 • Flagship

The clinical diagnosis was *VPS33B* deficiency, also known as PFIC Type 12.[47] Rodas concluded that "the idea is not just to go over the results and read the results; it is to connect that genetic information with your clinical phenotype."

Conclusion

Genetic cholestasis may be diagnosed across the lifespan, and adults with unexplained cholestasis should be considered for testing.[1] Advances in genetic testing have expanded our ability to identify underlying genetic contribution to cholestatic disease; however, obtaining genetic results is just one part of the diagnostic process. Interpretation of genetic test results may be challenging, particularly as it relates to resolving heterozygous and/or VUS, or in cases where the patient's phenotype does not cleanly align.[45]

Genetic findings should therefore be interpreted alongside the patient's clinical and biochemical phenotype, family history, and expected inheritance pattern, with consultation or collaboration with genetics professionals and other specialists when results are uncertain or complex. Understanding the scope and limitations of the test modality, including which genes and genetic regions were and were not evaluated, is also important when

Figure 2: Steps for interpreting a genetic test report.



Based on the case-based presentation by Rodas. Variant classification follows Richards et al.[16]

considering whether additional or updated testing is appropriate.

Utilising genetic testing to inform an accurate diagnosis has implications beyond identifying the cause of disease. Depending on the underlying disorder and individual phenotype, it may inform longitudinal monitoring for disease progression and associated complications, evaluation of extrahepatic manifestations, clinical management, and consideration of testing or counselling for family members.

References

1. European Association for the Study of the Liver. EASL Clinical Practice Guidelines on genetic cholestatic liver diseases. J Hepatol. 2024;81(2):303-25.
2. Online Mendelian Inheritance in Man (OMIM). PS211600 Cholestasis, progressive familial intrahepatic - PS211600. Available at: https://omim.org/phenotypicSeries/PS211600. Last accessed: 25 November 2026.
3. Davit-Spraul A et al. Progressive familial intrahepatic cholestasis. Orphanet J Rare Dis. 2009;4:1.
4. Karpen SJ et al. Use of a comprehensive 66-gene cholestasis sequencing panel in 2171 cholestatic infants, children, and young adults. J Pediatr Gastroenterol Nutr. 2021;72(5):654-60.
5. Stättermayer AF et al. Variants in ABCB4 (MDR3) across the spectrum of cholestatic liver diseases in adults. J Hepatol. 2020;73(1):651-63.
6. Li J et al. Clinical and genetic characteristics of Alagille syndrome in adults. J Clin Transl Hepatol. 2023;11(1):156-62.
7. McKiernan P et al. Opinion paper on the diagnosis and treatment of progressive familial intrahepatic cholestasis. JHEP Rep. 2024;6(1):100949.
8. Nayagam JS et al. Clinical phenotype of adult-onset liver disease in patients with variants in ABCB4, ABCB11, and ATP8B1. Hepatol Commun. 2022;6(10):2654-64.
9. European Association for the Study of the Liver. EASL Clinical Practice Guidelines on sclerosing cholangitis. J Hepatol. 2022;77(3):761-806.
10. Thompson RJ et al. Challenges in the diagnosis and treatment of genetic cholestasis in adults. JHEP Rep. 2026;8(1):101625.
11. Nayagam JS et al. Genetic cholestasis in children and adults. J Hepatol. 2024;80(4):670-72.
12. Dong C et al. Low-phospholipid-associated cholelithiasis syndrome: prevalence, clinical features, and comorbidities. JHEP Rep. 2021;3(2):100201.
13. Ranchin B et al. Kidney and vascular involvement in Alagille syndrome. Pediatr Nephrol. 2025;40:891-99.
14. Allouni S, Ala A. Rare but relevant: genetic liver disease in the general medical setting. Clin Med (Lond). 2025;25(6):100535.
15. Davit-Spraul A et al. ATP8B1 and ABCB11 analysis in 62 children with normal gamma-glutamyl transferase progressive familial intrahepatic cholestasis (PFIC): phenotypic differences between PFIC1 and PFIC2 and natural history. Hepatology. 2010;51(5):1645-55.
16. Richards S et al. Standards and guidelines for the interpretation of sequence variants: a joint consensus recommendation of the American College of Medical Genetics and Genomics and the Association for Molecular Pathology. Genet Med. 2015;17(5):405-24.
17. Chung DH et al. Hepatology genome rounds: an interdisciplinary approach to integrate genomic data into clinical practice. J Hepatol. 2023;79(4):1065-71.
18. Ibrahim SH et al. Cholestatic liver diseases of genetic etiology: advances and controversies. Hepatology. 2022;75(6):1627-46.
19. van Wessel DBE et al. Impact of genotype, serum bile acids, and surgical biliary diversion on native liver survival in FIC1 deficiency. Hepatology. 2021;74(2):892-906.
20. van Wessel DBE et al. Genotype correlates with the natural history of severe bile salt export pump deficiency. J Hepatol. 2020;73(1):84-93.
21. Vitale G et al. Genotypes and different clinical variants between children and adults in progressive familial intrahepatic cholestasis: a state-of-the-art review. Orphanet J Rare Dis. 2025;20:80.
22. Sambrotta M et al. Mutations in TJP2 cause progressive cholestatic liver disease. Nat Genet. 2014;46:326-8.
23. Turnpenny PD, Ellard S. Alagille syndrome: pathogenesis, diagnosis and management. Eur J Hum Genet. 2012;20:251-7.
24. Ayoub MD, Kamath BM. Alagille syndrome: diagnostic challenges and advances in management. Diagnostics (Basel). 2020;10(11):907.
25. Zheng M et al. Advancing diagnosis and management of liver disease in adults through exome sequencing. EBioMedicine. 2023;95:104747.
26. Ayoub MD et al. Management of adults with Alagille syndrome. Hepatol Int. 2023;17:1098-112.
27. Zhang W et al. Alagille syndrome: an uncommon cause of intrahepatic cholestasis in adults. Rev Esp Enferm Dig. 2019;111(4):323-6.
28. Kamath BM et al. Outcomes of childhood cholestasis in Alagille syndrome: results of a multicenter observational study. Hepatol Commun. 2020;4(3):387-98.
29. Pawlikowska L et al. Differences in presentation and progression between severe FIC1 and BSEP deficiencies. J Hepatol. 2010;53(1):170-8.
30. Spinner NB et al. Alagille syndrome. [Internet] (2024) Seattle: University of Washington. Available at: https://www.ncbi.nlm.nih.gov/books/NBK1273/. Last accessed: 25 November 2026.
31. Emerick KM et al. Intracranial vascular abnormalities in patients with Alagille syndrome. J Pediatr Gastroenterol Nutr. 2005;41(1):99-107.
32. Knisely AS et al. Hepatocellular carcinoma in ten children under five years of age with bile salt export pump deficiency. Hepatology. 2006;44(2):478-86.
33. Zhou S et al. Hepatocellular carcinoma associated with tight-junction protein 2 deficiency. Hepatology. 2015;62(6):1914-6.
34. Sambrotta M, Thompson RJ. Mutations in TJP2, encoding zona occludens 2, and liver disease. Tissue Barriers. 2015;3(3):e1026537.
35. Shneider BL et al. Nonfasted liver stiffness correlates with liver disease parameters and portal hypertension in pediatric cholestatic liver disease. Hepatol Commun. 2020;4(11):1694-707.

CC BY-NC 4.0 Licence • Copyright © 2026 EMJ • November 2026 • Flagship

36. McPherson E. Genetic diagnosis and testing in clinical practice. Clin Med Res. 2006;4(2):123-9.
37. Düll MM, Kremer AE. Newer approaches to the management of pruritus in cholestatic liver disease. Curr Hepatol Rep. 2020;19:86-95.
38. Kamath BM et al. Medical management of Alagille syndrome. J Pediatr Gastroenterol Nutr. 2010;50(6):580-6.
39. Bull LN et al. Outcomes of surgical management of familial intrahepatic cholestasis 1 and bile salt export protein deficiencies. Hepatol Commun. 2018;2(5):515-28.
40. Sahloul A et al. Progressive familial intrahepatic cholestasis: outcome and time to transplant after biliary diversion according to genetic subtypes. Front Surg. 2023;10:1074229.
41. Felzen A et al.; NAtural course and Prognosis of PFIC and Effect of biliary Diversion (NAPPED) Consortium. Genotype-phenotype relationships of truncating mutations, p.E297G and p.D482G in bile salt export pump deficiency. JHEP Rep. 2022;5(2):100626.
42. Avena A et al. ABCB4 variants in adult patients with cholestatic disease are frequent and underdiagnosed. Dig Liver Dis. 2021;53(3):329-44.
43. Sinha A et al. ABCB4 mutations in adults cause a spectrum cholestatic disorder histologically distinct from other biliary disease. Dig Dis Sci. 2022;67:5551-61.
44. Scaravaglio M et al. Diagnostic yield of whole exome sequencing in adult-onset cholestatic liver disease. Clin Gastroenterol Hepatol. 2026;24(4):1035-43.
45. Conti A et al. Use of next-generation sequencing and whole-exome sequencing in the diagnosis of adult-onset familial intrahepatic cholestasis: challenges in interpreting variants of uncertain significance. Diagnostics (Basel). 2026;16(15):2335.
46. Mareux E et al. In vitro rescue of the bile acid transport function of ABCB11 variants by CFTR potentiators. Int J Mol Sci. 2022;23(18):10758.
47. Online Mendelian Inheritance in Man (OMIM). #620010 Cholestasis, progressive familial intrahepatic, 12; PFIC12. 2022. Available at: https://www.omim.org/entry/620010. Last accessed: 5 October 2026.

DRSC-US-001363 | November 2026